CLINICAL ORAL IMPLANTS RESEARCH WILEY-BLACKWELL

Impact of bone graft harvesting techniques on bone formation and graft resorption: A histomorphometric study in the mandibles of minipigs

Journal:	*Clinical Oral Implants Research*
Manuscript ID:	COIR-Sep-13-OR-3696.R1
Manuscript Type:	Original Research
Date Submitted by the Author:	n/a
Complete List of Authors:	Saulacic, Nikola; University of Bern, Department of Oral Surgery and Stomatology, School of Dental Medicine; University Hospital, Department of Cranio-Maxillofacial Srugery Bosshardt, Dieter; University of Bern, Department of Oral Surgery and Stomatology, School of Dental Medicine Jensen, Simon; Copenhagen University Hospital (Rigshospitalet), Department of Oral and Maxillofacial Surgery; University of Bern, Department of Oral Surgery and Stomatology, School of Dental Medicine Miron, Richard; University of Bern, Department of Oral Surgery and Stomatology, School of Dental Medicine Gruber, Reinhard; University of Bern, Department of Oral Surgery and Stomatology, School of Dental Medicine Buser, Daniel; University of Bern, Department of Oral Surgery and Stomatology, School of Dental Medicine
Keywords:	Animal Experiments, Surgical techniques, Guided tissue regeneration, Bone regeneration

SCHOLARONE™
Manuscripts

Impact of bone graft harvesting techniques on bone formation and graft resorption: A histomorphometric study in the mandibles of minipigs

Nikola Saulacic[1,2], Dieter D. Bosshardt[1,3], Simon S. Jensen[1,4], Richard Miron[1], Reinhard Gruber[1,5], Daniel Buser[1]

[1]Department of Oral Surgery and Stomatology, School of Dental Medicine, University of Bern, Switzerland

[2]Department of Cranio-Maxillofacial Surgery, University Hospital, Bern, Switzerland

[3]Robert K. Schenk Laboratory of Oral Histology, School of Dental Medicine, University of Bern, Switzerland

[4]Department of Oral and Maxillofacial Surgery, Copenhagen University Hospital (Rigshospitalet), Copenhagen, Denmark

[5]Laboratory of Oral Cell Biology, School of Dental Medicine, University of Bern, Switzerland

Running title: Bone graft harvesting techniques and bone formation

Corresponding author: Prof. Dr. med. dent. Daniel Buser, Department of Oral Surgery and Stomatology, School of Dental Medicine, University of Bern, Freiburgstrasse 7, CH-3010, Bern, Switzerland. Telephone: +41 31 632 2555, Fax: +41 31 632 2566, E-mail: daniel.buser@zmk.unibe.ch

Keywords: autogenous bone graft, bone formation, bone resorption, histological analysis.

Clinical Oral Implants Research

Abstract

Background: Harvesting techniques can affect cellular parameters of autogenous bone grafts in vitro. Whether these differences translate to in vivo bone formation, however, remains unknown.

Objective: The purpose of the present study was to assess the impact of different harvesting techniques on bone formation and graft resorption in vivo.

Material and methods: Four harvesting techniques were used: (a) cortico-cancellous blocks particulated by a bone mill, (b) bone scraper, (c) piezosurgery, and (d) bone slurry collected from a filter-device upon drilling. The grafts were placed into bone defects in the mandibles of 12 minipigs. The animals were sacrificed after 1, 2, 4 and 8 weeks of healing. Histology and histomorphometrical analysis were performed to assess bone formation and graft resorption. An explorative statistical analysis was performed.

Results: The amount of new bone increased, while the amount of residual bone decreased over time with all harvesting techniques. At all given time points, no significant advantage of any harvesting technique on bone formation was observed. The harvesting technique, however, affected bone formation and the amount of residual graft within the overall healing period. Friedman test revealed an impact of the harvesting technique on residual bone graft after 2 and 4 weeks. At the later time point, post-hoc testing showed more newly formed bone in association with bone graft processed by bone mill than harvested by bone scraper and piezosurgery.

Conclusions: Transplantation of autogenous bone particles harvested with four techniques in the present model resulted in moderate differences in terms of bone formation and graft resorption.

Clinical Oral Implants Research

Introduction

In implant dentistry, bone grafts are frequently used for bone augmentation procedures prior to or simultaneous with implant placement to ensure long-term functional and esthetic stability (Buser et al. 2009, 2013; Jung et al. 2012). Bone formation in the space protected by a barrier membrane has been demonstrated in preclinical (Dahlin et al. 1988, 1989, 1994; Gotfredsen et al. 1993; Schenk et al. 1994) and clinical studies (Lazzara 1989; Nyman et al. 1990; Buser et al. 1990). Particulate autogenous bone (PAB) can prevent the collapse of the membrane into the bone defect (Mellonig & Nevins 1995) and supports early bone formation better than bone substitutes (Buser et al. 1998; Jensen et al. 2006, 2007, 2011). There are various surgical techniques available for bone harvesting, raising the question of wether the method of bone harvesting may affect bone formation.

Surgical techniques to obtain PAB include grinding the bone blocks with a bone mill (Lundgren et al. 1996; Peleg et al. 1998), harvesting bone with a bone scraper (Zaffe & D'Avenia 2007; Johansson et al. 2010), by means of piezosurgery (Lambrecht 2004) or by collecting the bone slurry during a bone drilling procedure with a filter device (Widmark & Ivanoff 2000; Johansson et al. 2010). PAB prepared with different harvesting techniques show different properties such as size, shape, surface topography and number of living cells (Albrektsson 1980; Gruber et al. 2005; von See et al. 2010). The impact of two harvesting techniques on bone formation in vivo was already determined in rabbits; bone particles collected during blood-suction upon drilling caused a similar amount of new bone as particulated bone when placed in bone defects in the tibia (Coradazzi et al. 2007), but less bone formation in the calvaria (Kon et al. 2009; Clune et al. 2010). The method of bone grafting and proceeding can thus contribute to bone formation, but this depends on the anatomical location of the defect site. Nevertheless, the existing knowledge on the impact of harvesting techniques on bone formation is limited. An animal model has been established to evaluate bone formation using membrane-protected, standardized defects in the mandibular angle of minipigs (Buser et al. 1998; Jensen et al. 2006, 2007, 2009, 2011), since bone geometry and metabolism of minipigs mimic that of humans closely. PAB harvested with different surgical techniques have not been compared previously in this well documented minipig model.

The in vitro impact of four harvesting techniques on cell viability, differentiation and the release of growth factors was recently determined. The cellular parameters such as cell viability and the expression of osteogenic marker genes and growth factors were higher in bone harvested with a scraper and bone processed by a bone mill when compared to bone harvested by piezo-surgery or by

Clinical Oral Implants Research

a bone trap (Miron et al. 2011, 2013). Moreover, a difference in the number of cells was detected depending on the harvesting technique (Springer et al. 2004; Gruber et al. 2005). It remains, however, unknown whether these in vitro observations translate into in vivo. The aim of the present study was to determine the impact of four harvesting techniques on (1) bone formation and (2) graft resorption in standardized bone defects in the mandible of minipigs.

Material and methods

Study design and surgery

A total of 12 adult (2-4-year-old) Göttingen minipigs were used in this study. The husbandry and care of animals before, during and after surgery was done at the Surgical Research Unit ESI and Clinic for Large Animals, University of Bern. The animals received a standard diet and water ad libitum. The protocol of the study was approved by the Committee for Animal Research, State of Bern, Switzerland (Approval No. 13/10), using a study design that has been successfully utilized in previous studies (Buser et al. 1998, Jensen et al. 2007). The present study was performed in conjunction with an in vitro experiment for characterization of PAB harvested from the mandible of minipigs (Miron et al., 2011, 2013).

Animals were sedated by ketamine (i.m. 20 mg/kg), xylazine (i.m. 2 mg/kg), atropine (i.v. 0,05 mg/kg) and midazolam (i.v. 0,5 mg/kg) to achieve the intubation status. Inhalation anesthesia was induced and maintained with isoflurane (1,0 - 1,5 %) administrated via an intratracheal tube. Fentanyl patches (5 - 10 mcg/kg) were used for the intraoperative analgesia and the local anesthesia of articain hydrochloride (Ultracain DS, 1:200.000). The animals received antibiotic prophylaxis for three days (Duplocillin LA, 12'000 U.I./kg).

The study was designed as a randomized, controlled experimental study performed in two surgical phases. Four standardized intraosseous defects were created on each side of the mandible. Through subangular incisions, the lateral portion of the mandibular body and ramus were exposed sufficiently to allow the preparation of four standardized intraosseous defects on each side of the mandible. Defects measuring 7 mm in diameter and 4 mm in depth were prepared using a trephine with copious saline irrigation. PAB obtained with four different harvesting techniques was placed using a systematic random protocol (www.ranbdomization.com) during two surgical interventions, according to the split-

mouth design: (a) The cortico-cancellous blocks ground to a particulate size using a bone mill (R. Quétin, Leimen, Germany), particle size approx. 1.5-2.5 mm (BM); (b) cortical bone grafts harvested with a bone scraper (Bone scraper, Hu-Friedy Mfg. B.V., Netherlands), particle size approx. 1-2 mm (BS); (c) cortical bone grafts harvested with a piezosurgery (Piezosurgery, Mectorn GmbH, Germany), particle size approx. 0.5-1.0 mm (PS); (d) bone slurry collected from the aspirator with a bone trap filter (KF T2, Schlumbohm GmbH, Brokstedt, Germany) during the preparation of the osteotomy, particle size approx. 0.05-0.2 mm (BT).

Each of the four PAB (a-d) were placed into the prepared osseous defects of the mandible. Following graft placement, an expanded polytetrafluoroethylene (ePTFE) membrane (GT10, W. L. Gore & Associates Newark, DE) was used to cover the four defects and stabilized with five fixation screws (Modus 1.5, Medartis AG, Basel, Switzerland). In the second surgery, PAB was placed in an identical sequence on the contralateral side of the mandible. In six animals, four different PAB were placed on the left side of the mandible and one week later also on the right side. The animals were sacrificed one week later, yielding healing periods of one and two weeks. In the other six animals, PAB was placed on the left side of the mandible and four weeks later also on the right side. The animals were sacrificed after four weeks, yielding healing periods of four and eight weeks. A sample size of six defects per time period (12 animals; N=96 in total; N=24 per time period; N=6 for each graft material) is based on those used in previously published studies (Buser et al. 1998; Jensen et al., 2006, 2007 2009, 2011).

Sacrifice and retrieval of specimens

Animals were sacrificed by intravenous injection of 20 mmol KCl. Soft tissue was removed to expose the treated area. The mandibles were cut bilaterally just above the mandibular foramen and anterior to the masseter to harvest two blocks each containing four defects for histologic preparation.

Histological preparation and analysis

Prior to histologic preparation, the recovered segments were immediately immersed in a solution of 4% buffered formalin combined with 1% $CaCl_2$. The specimens were processed for the production of undecalcified ground sections as described by Schenk et al. (Schenk 1984) Briefly, the samples were rinsed in running tap water, dehydrated in ascending concentrations of ethanol and embedded in

Clinical Oral Implants Research

methylmethacrylate. The embedded tissue blocks were cut into approximately 400 µm-thick ground sections using a slow-speed diamond saw (Varicut® VC-50, Leco, Munich, Germany). After mounting the sections onto acrylic glass slabs, they were ground and polished to a final thickness of about 100 µm (Knuth-Rotor-3, Struers, Rodovre/Copenhagen, Denmark) and surface stained with toluidine blue (Schenk 1984). The two central-most sections were used for descriptive and morphometric analyses. Digital photography was performed using a ProgRes® C5 digital camera (Jenoptik Laser, Optik, Systeme GmbH, Jena, Germany) connected to a Zeiss Axioplan microscope (Carl Zeiss, Göttingen, Germany). Due to the observed progress of bone regeneration in this type of defect anatomy (i.e. from the defect margin to the defect center), the defects were divided into four regions (Fig. 1).

Histomorphometric measurements were performed in order to calculate the amount of tissues formed relative to the defect area defined by the parent bone and the barrier membrane (total volume, TV). The area fraction of osteoid, newly formed mineralized bone, total new bone (NB/TV), residual PAB (PAB/TV) and soft tissue were assessed by point counting directly in the light microscope, using an optically superimposed eyepiece test square grid (distance between 6 x 6 test lines = 255 µm) at a magnification of 160-fold. In a subset of specimens, the histomorphometric analysis was performed twice in order to determine the reproducibility of the method employed. Means, medians and ranges were calculated for all measurements.

Statistical analysis

An explorative statistical analysis without correction for the multiple testing was performed. Thus, no adjustment for multiple testing was done. NB/TV was determined as the primary outcome and PAB/TV as the secondary outcome of the study. The Friedman test was used to test for differences between the four harvesting techniques for NB/TV and PAB/TV per healing time. A post-hoc Wilcoxon test for pairwise comparisons was performed. For the comparison of 1-week vs. 8-week healing period, Brunner□Langer F1_LD_F1 model was used with healing time as a whole□plot factor and type of PAB as a sub□plot factor. A significance level of 0.05 was chosen.

Clinical Oral Implants Research

Results

Clinical observation

All twelve animals survived the surgical procedures. One animal had to be excluded at the time of sample harvesting due to the incomplete fracture connecting bone defects of the mandibular angle on the left side. An additional animal was therefore included to have n=6 in each group. There were no other complications encountered. Clinical inspection did not reveal any dehiscence or sign of infection at the surgical sites.

Histological analysis

One week

All defects were delineated by the bone defect margins and the barrier membrane (Fig. 2). Irrespective of the grafting material used, a blood clot was present in all defects, mostly in the upper half of the defect space. At some sites, the blood clot was trapped in some spiral-shaped BS graft particles (Fig. 3e). Granulation tissue was seen close to the defect walls, particularly at the bottom of the defects (Figs 3a,c,g). A small amount of woven bone was observed in some of the defects, irrespective of the grafting material used (Figs 3a,c,g). Bone formation always started at the defect margins, particularly at the bottom and at sites where bone marrow was opened during defect creation (Figs 3a,c,g). Residual bone graft material was present in all defects and each type of grafting material had its characteristic shape. The BM graft contained some large and bulky particles and many thinner, serrated bone particles (Figs 2a, 3a), the BC graft consisted of many thin and spiral-shaped bone particles (Figs 2c, 3c), PS particles were thin and mainly horseshoe-shaped or flattened (Figs 2e, 3e), whereas the BT graft consisted of plenty of tiny bone particle fragments, some of which were clustered together (Figs 2g, 3g). The number of osteoclasts on the bone graft particles was highest after one week. While the lowest number of osteoclasts was found in the defects filled with BM particles (Fig. 4a), their number was higher in defects filled with BS (Fig. 4b) or PS particles (Fig. 4c). The osteoclasts seemed to sever some of the thin, spiral-shaped BS particles (Fig. 4b). The highest number of osteoclasts was found on the BT particles concomitant with a high number of other small cells and blood vessels (Fig. 4d).

Clinical Oral Implants Research

Two weeks

Only a few defects contained some residual blood clot (Fig. 2). Blood clot was also seen retained in some residual, spiral-shaped BS particles. Granulation tissue and new bone had expanded further into the center of the defects and some of the defects showed woven bone formation almost to the level of the barrier membrane, irrespective of the graft material used. The woven bone at the bottom of the defects had matured and the granulation tissue converted into a provisional matrix rich in small blood vessels (Fig. 3). Osteoid and osteoblasts were still plentiful, whereas the number of osteoclasts clearly decreased. While BM and BS particles were still numerous, the amount of PS and BT particles was reduced (Fig. 2). Furthermore, the number of BS particles with a typical spiral shape was reduced (compare Fig. 2c with 2d).

Four weeks

All defect showed a trabecular network of new bone to the level of the membrane (Fig. 5) and all remaining graft particles were embedded in newly formed bone (Fig. 6). The new bone consisted of a central lattice of woven bone onto which parallel-fibered bone was deposited (Fig. 6). Residual blood clot was not or barely visible and the maturation of the bone marrow had progressed. The original shape of the bone graft particles was retained at some sites and reflected by the architecture of the newly formed bone (Fig. 6).

Eight weeks

All defects demonstrated complete bone fill with a quite mature bone marrow (Figs 5 and 6). The new bone was more compact underneath the barrier membrane than elsewhere in the defect (Fig. 5). The graft particles were embedded in newly formed bone and displayed an architecture reminiscent of their origin (Fig. 6).

Histomorphometric analysis

The amount of new bone increased while the amount of residual PAB decreased over time with all harvesting techniques (Table 1, Fig. 7). Bone formation was independent from the harvesting technique at all time points ($P > 0.05$). Based on the explorative statistical analysis, however, the interaction term was significant from week 1 to week 8 (Table 2). The post-hoc tests were significant for all four types of PAB ($P = 0.0022$), indicating that the harvesting technique affects bone formation

Clinical Oral Implants Research

with in the observation period. In other words, the effect of four types of bone grafts on bone formation depends on the time point of observation.

The explorative statistical analysis further revealed that more residual BM particle area was present compared to the other bone grafts types (Table 1, Fig. 7), particularly at week 4 compared to BS (P = 0.0313) and PS particles (P = 0.0313). In summary, the explorative statistical analysis reflects the observations from the histological analysis that, if at all, only minor changes in bone formation and graft resorption were evident among the four types of bone grafts.

Discussion

The goal of this study was to compare the impact of four harvesting techniques on early bone formation and graft resorption in membrane-protected, standardized defects in the mandibles of minipigs. Bone formation was statistically similar at any given time-point, but the harvesting technique affected bone formation and the amount of residual PAB over time. Even though the explorative statistical analysis revealed some possible changes in bone formation and graft resorption over time, the overall impact of the harvesting technique has to be considered modest. Thus, from a clinician's perspective, all harvesting techniques are equally efficient for the bone regeneration in this particular defect situation. Nevertheless, PAB in the present study were harvested under optimal conditions, without inclusion of soft tissue cells or saliva. Possible contamination of PAB was thus excluded, not completely representing a real clinical situation (Sivolella et al. 2006). Since the present study was not designed to have sufficient statistical power, the overall conclusions have to be interpreted with care. However, there is a discrepancy between the in vivo observations presented here and previous in vivo findings.

In a previous in vitro study, PAB harvested by the same four techniques demonstrated differences, e.g. cell viability and the release of molecules were higher in BM and BS samples when compared with PS and BT samples (Miron et al. 2011, 2013). Thus, the in vitro findings do not necessarily translate into bone formation or graft resorption in vivo. The possible reasons for this discrepancy are speculative. It is possible that the osteogenic capacity of PAB is neglectable, independent of the harvesting technique. What remains besides the osteogenic capacity is the osteoconductivity and osteoinductivity; the two other parameters that define graft consolidation. Thus, bone formation appears to be mainly affected by the osteoconductivity and possibly also by the osteoinductivity of

Clinical Oral Implants Research

PAB – both parameters being independent of the cellular activity of the graft. However, this is not the only explanation for the lack of consistency between in vitro and in vivo findings.

The lack of difference in bone formation between different groups at a given healing period may also be explained by the use of a non-critical size defect that ultimately would spontaneously heal (Buser et al. 1998). The use of a non-resorbable membrane further enhances the favourable conditions for uneventful bone healing by protecting the self-contained defects from ingrowth of soft tissue. The acute, circular, self-contained and membrane-protected mandibular defect allows extensive bone formation, which is perhaps not of sufficient challenge to reveal possible subtle differences caused by the four bone grafts. This assumption is supported by another non-critical size defect model demonstrating no differences in bone formation between grafts consisting of bone slurry and particulated bone (Coradazzi et al. 2007). Differences in bone formation were, however, observed in a one wall calvaria augmentation model (Kon et al. 2009) or inlay cranioplasty (Clune et al. 2010). Together, these data suggest that the harvesting technique can affect bone formation in defects that are more demanding than the defect model used in the present study. Furthermore, minipigs have favorable healing capacity, indicating that the lack of difference in bone formation might additionally be attributed to the excellent healing. On the other hand, including healing periods of one and two weeks, where very limited bone formation was observed, should leave sufficient room for a grafting material to reveal its possible superiority in terms of supporting new bone.

The primary intension of the present study was to compare the consolidation of autografts obtained by different harvesting techniques and not if the grafts performed better than empty control. Furthermore, the bone particles were consequently not supposed to perform better than an empty defect. The barrier membrane delineates the lateral border of the bone defects, but usually collapse into the volume of an empty defect. The defect area would thus decrease and the relative area of the newly formed bone would increase (Buser et al. 1998; Jensen et al. 2009). In empty defects and defects filled with particulated bone graft, an average of 34% and 39% new bone was observed after 4 weeks of healing, respectively (Buser et al. 1998). Thus, the overall impact of PAB to support bone formation in this defect situation is weak, if at all significant. However, the standardized, membrane-protected defects in the mandible of the minipig are highly suitable to detect a delay in bone formation in the presence of bone substitutes. In our previous studies, PAB was used as a positive control with results comparable to those of the present investigation (Jensen et al., 2006, 2007, 2011). It may be more appropriate to discuss the present data under this premise: PAB obtained by the four harvesting

techniques do not impair bone regeneration. The defect situation is presumably not challenging enough to reveal a potential beneficial effect of the type of bone graft on bone formation.

The present study has clearly shown that the bone resorption was very prominent particularly during the first week of healing. This was particularly true for the BT with lowest particle size, as demonstrated by histomorphometric data from the first to the second week of healing. Corticocancellous architecture of particulated bone grafts processed by bone mill may influence the revascularization and resorption of bone grafts (Chen et al. 1994; Pallesen et al. 2002). Different sizes of the PAB samples used in the present study might have caused a significant interaction term developed from 1-week to 8-weeks. A reverse relationship between particle size and new bone was previously observed using particulated bone grafts (Pallesen et al. 2002) and deproteinized compact bone (Xu et al. 2003; Zhou et al. 2011). A smaller surface area of PAB processed by bone mill may be available for osteoclastic resorption, but also for subsequent bone apposition. Accordingly, biggest surface area of samples prepared by bone drilling probably allowed more volume to be occupied by new bone. It is conceivable that the high resorptive activity of osteoclasts in the first phase led to a release of cytokines and/or growth factors that accelerated bone formation in the second phase (Sims & Walsh 2012). In the case of BT particles, the osteoconductivity may thus be of subsidiary importance and the osteoconductivity of superior importance. Thus, explorative statistical analysis without correction has revealed minor differences in the behaviour of various grafts in vivo.

The clinical relevance of this study has to be interpreted strictly based on the defect situation. According to the present results, PAB samples obtained by the four harvesting techniques are likely equally efficient for augmentation of self-contained bone defects. However, the good performance of the BT samples observed in the present study may not apply to the real clinical situation, where bone slurry collected from the oral cavity are reported to be contaminated with microorganisms (Sivolella et al. 2006). The present data cannot be generalized. Further studies on the osteogenic potential of PAB should include more demanding models, for example one wall defects or models of compromised bone regeneration.

Conclusions

The impact of harvesting technique on bone formation and graft resorption in membrane-protected, standardized defects in the mandible of minipigs is modest. The present data do not rule out that the harvesting technique has an impact on bone formation in a more challenging defect model.

Clinical Oral Implants Research

Acknowledgements

The authors wish to thank the staff at the Surgical Research Unit ESI and Clinic for Large Animals for excellent handling of the animals, Ms. Claudia Moser and Dr. Leandro Nunes for their professional help during surgical procedures, Mr. David Reist for the histologic preparation of the specimens, Ms. Silvia Owusu for performing the histomorphometric analysis and Ms. Jasmin Wandel (University of Bern, Institute of Mathematical Statistics and Actuarial Science) for statistical advice. The study was supported by a grant from the ITI Foundation (Basel, Switzerland, grant 692_2010).

References

Albrektsson, T. (1980) The healing of autologous bone grafts after varying degrees of surgical trauma. *Journal of Bone & Joint Surgery* **62B:** 403-410.

Buser, D., Bragger, U., Lang, N. P. & Nyman, S. (1990) Regeneration and enlargement of jaw bone using guided tissue regeneration. *Clinical Oral Implants Research* **1:** 22-32.

Buser, D., Chappuis, V., Bornstein, M. M., Wittneben, J. G., Frei, M. & Belser, U. C. (2013) Long-Term Stability of Contour Augmentation With Early Implant Placement Following Single Tooth Extraction in the Esthetic Zone: A Prospective, Cross-Sectional Study in 41 Patients With a 5- to 9-Year Follow-Up. *Journal of Periodontology* **84:** 1517-1527.

Buser, D., Halbritter, S., Hart, C., Bornstein, M. M., Grutter, L., Chappuis, V. & Belser, U. C. (2009) Early implant placement with simultaneous guided bone regeneration following single-tooth extraction in the esthetic zone: 12-month results of a prospective study with 20 consecutive patients. *Journal of Periodontology* **80:** 152-162.

Buser, D., Hoffmann, B., Bernard, J. P., Lussi, A., Mettler, D. & Schenk, R. K. (1998) Evaluation of filling materials in membrane--protected bone defects. A comparative histomorphometric study in the mandible of miniature pigs. *Clinical Oral Implants Research* **9:** 137-150.

Chen, N. T., Glowacki, J., Bucky, L. P., Hong, H. Z., Kim, W. K. & Yaremchuk, M. J. (1994) The roles of revascularization and resorption on endurance of craniofacial onlay bone grafts in the rabbit. *Plastic and Reconstructive Surgery* **93:** 714-722.

Chiapasco, M. & Zaniboni, M. (2009) Clinical outcomes of GBR procedures to correct peri-implant dehiscences and fenestrations: a systematic review. *Clinical Oral Implants Research* **20 Suppl 4:** 113-123.

Clinical Oral Implants Research

Clune, J. E., Mulliken, J. B., Glowacki, J., Rogers, G. F., Arany, P. R., Kulungowski, A. M. & Greene, A. K. (2010) Inlay cranioplasty: an experimental comparison of particulate graft versus bone dust. *Plastic and Reconstructive Surgery* **126:** 1311-1319.

Coradazzi, L. F., Garcia, I. R., Jr. & Manfrin, T. M. (2007) Evaluation of autogenous bone grafts, particulate or collected during osteotomy with implant burs: histologic and histomorphometric analysis in rabbits. *The International Journal of Oral & Maxillofacial Implants* **22:** 201-207.

Dahlin, C., Linde, A., Gottlow, J. & Nyman, S. (1988) Healing of bone defects by guided tissue regeneration. *Plastic and Reconstructive Surgery* **81:** 672-676.

Dahlin, C., Sandberg, E., Alberius, P. & Linde, A. (1994) Restoration of mandibular nonunion bone defects. An experimental study in rats using an osteopromotive membrane method. *International Journal of Oral & Maxillofacial Surgery* **23:** 237-242.

Dahlin, C., Sennerby, L., Lekholm, U., Linde, A. & Nyman, S. (1989) Generation of new bone around titanium implants using a membrane technique: an experimental study in rabbits. *The International Journal of Oral & Maxillofacial Implants* **4:** 19-25.

Gotfredsen, K., Nimb, L., Buser, D. & Hjorting-Hansen, E. (1993) Evaluation of guided bone generation around implants placed into fresh extraction sockets: an experimental study in dogs. *Journal of Oral and Maxillofacial Surgery* **51:** 879-884.

Gruber, R., Baron, M., Busenlechner, D., Kandler, B., Fuerst, G. & Watzek, G. (2005) Proliferation and osteogenic differentiation of cells from cortical bone cylinders, bone particles from mill, and drilling dust. *Journal of Oral and Maxillofacial Surgery* **63:** 238-243.

Jensen, S. S., Bornstein, M. M., Dard, M., Bosshardt, D. D. & Buser, D. (2009) Comparative study of biphasic calcium phosphates with different HA/TCP ratios in mandibular bone defects. A long-term histomorphometric study in minipigs. *Journal of Biomedical Materials Research B Appllied Biomaterials* **90:** 171-181.

Jensen, S. S., Broggini, N., Hjorting-Hansen, E., Schenk, R. & Buser, D. (2006) Bone healing and graft resorption of autograft, anorganic bovine bone and beta-tricalcium phosphate. A histologic and histomorphometric study in the mandibles of minipigs. *Clinical Oral Implants Research* **17:** 237-243.

Jensen, S. S., Chen, B., Bornstein, M. M., Bosshardt, D. D. & Buser, D. (2011) Effect of enamel matrix derivative and parathyroid hormone on bone formation in standardized osseous defects: an experimental study in minipigs. *Journal of Periodontology* **82:** 1197-1205.

Clinical Oral Implants Research

Jensen, S. S., Yeo, A., Dard, M., Hunziker, E., Schenk, R. & Buser, D. (2007) Evaluation of a novel biphasic calcium phosphate in standardized bone defects: a histologic and histomorphometric study in the mandibles of minipigs. *Clinical Oral Implants Research* **18:** 752-760.

Johansson, L. A., Isaksson, S., Lindh, C., Becktor, J. P. & Sennerby, L. (2010) Maxillary sinus floor augmentation and simultaneous implant placement using locally harvested autogenous bone chips and bone debris: a prospective clinical study. *Journal of Oral and Maxillofacial Surgery* **68:** 837-844.

Jung, R. E., Fenner, N., Hammerle, C. H. & Zitzmann, N. U. (2012) Long-term outcome of implants placed with guided bone regeneration (GBR) using resorbable and non-resorbable membranes after 12-14 years. *Clinical Oral Implants Research* **24:** 1065-1073.

Kon, K., Shiota, M., Ozeki, M., Yamashita, Y. & Kasugai, S. (2009) Bone augmentation ability of autogenous bone graft particles with different sizes: a histological and micro-computed tomography study. *Clinical Oral Implants Research* **20:** 1240-1246.

Lambrecht, J. T. (2004) Intraoral pizo-surgery. *Schweizer Monatsschrift für Zahnmedizin* **114:** 28-26.

Lazzara, R. J. (1989) Immediate implant placement into extraction sites: surgical and restorative advantages. *The International Journal of Periodontics & Restorative Dentistry* **9:** 332-343.

Lundgren, S., Moy, P., Johansson, C. & Nilsson, H. (1996) Augmentation of the maxillary sinus floor with particulated mandible: a histologic and histomorphometric study. *The International Journal of Oral & Maxillofacial Implants* **11:** 760-766.

Mellonig, J. T. & Nevins, M. (1995) Guided bone regeneration of bone defects associated with implants: an evidence-based outcome assessment. *The International Journal of Periodontics & Restorative Dentistry* **15:** 168-185.

Miron, R. J., Gruber, R., Hedbom, E., Saulacic, N., Zhang, Y., Sculean, A., Bosshardt, D. D. & Buser, D. (2013) Impact of Bone Harvesting Techniques on Cell Viability and the Release of Growth Factors of Autografts. *Clinical Implant Dentistry & Related Research* **15:** 481-489.

Miron, R. J., Hedbom, E., Saulacic, N., Zhang, Y., Sculean, A., Bosshardt, D. D. & Buser, D. (2011) Osteogenic potential of autogenous bone grafts harvested with four different surgical techniques. *Journal of Dental Research* **90:** 1428-1433.

Nyman, S., Lang, N. P., Buser, D. & Bragger, U. (1990) Bone regeneration adjacent to titanium dental implants using guided tissue regeneration: a report of two cases. *The International Journal of Oral & Maxillofacial Implants* **5:** 9-14.

Clinical Oral Implants Research

Pallesen, L., Schou, S., Aaboe, M., Hjorting-Hansen, E., Nattestad, A. & Melsen, F. (2002) Influence of particle size of autogenous bone grafts on the early stages of bone regeneration: a histologic and stereologic study in rabbit calvarium. *The International Journal of Oral & Maxillofacial Implants* **17:** 498-506.

Peleg, M., Mazor, Z., Chaushu, G. & Garg, A. K. (1998) Sinus floor augmentation with simultaneous implant placement in the severely atrophic maxilla. *Journal of Periodontology* **69:** 1397-1403.

Schenk, R. K., Buser, D., Hardwick, W. R. & Dahlin, C. (1994) Healing pattern of bone regeneration in membrane-protected defects: a histologic study in the canine mandible. *The International Journal of Oral & Maxillofacial Implants* **9:** 13-29.

Schenk, R. K., Olah, A.J., Hermann, W (1984) Preparation of calcified tissue for light microscopy. In: Dickson, G.R., ed. Methods of calcified tissue preparation, 1st edition pp. 1-56. Amsterdam: Elsevier Science Publishers BV.

Sims, N. A. & Walsh, N. C. (2012) Intercellular cross-talk among bone cells: new factors and pathways. *Current Osteoporos Reports* **10:** 109-117.

Sivolella, S., Berengo, M., Scarin, M., Mella, F. & Martinelli, F. (2006) Autogenous particulate bone collected with a piezo-electric surgical device and bone trap: a microbiological and histomorphometric study. *Archives of Oral Biology* **51:** 883-891.

Springer, I. N., Terheyden, H., Geiss, S., Harle, F., Hedderich, J. & Acil, Y. (2004) Particulated bone grafts--effectiveness of bone cell supply. *Clinical Oral Implants Research* **15:** 205-212.

von See, C., Rucker, M., Kampmann, A., Kokemuller, H., Bormann, K. H. & Gellrich, N. C. (2010) Comparison of different harvesting methods from the flat and long bones of rats. *British Journal of Oral and Maxillofacial Surgery* **48:** 607-612.

Widmark, G. & Ivanoff, C. J. (2000) Augmentation of exposed implant threads with autogenous bone chips: prospective clinical study. *Clinical Implant Dentistry & Related Research* **2:** 178-183.

Xu, H., Shimizu, Y., Asai, S. & Ooya, K. (2003) Experimental sinus grafting with the use of deproteinized bone particles of different sizes. *Clinical Oral Implants Research* **14:** 548-555.

Zaffe, D. & D'Avenia, F. (2007) A novel bone scraper for intraoral harvesting: a device for filling small bone defects. *Clinical Oral Implants Research* **18:** 525-533.

Zhou, X., Zhang, Z., Li, S., Bai, Y. & Xu, H. (2011) Osteoconduction of different sizes of anorganic bone particles in a model of guided bone regeneration. *British Journal of Oral and Maxillofacial Surgery* **49:** 37-41.

Clinical Oral Implants Research

Figure legends

Fig. 1 Schematic drawing of the bone defect area divided in four regions.

Fig.2 Histological sections illustrating the bone defect delineated by the old bone (OB) and the ePTFE membrane at 1 (a, c, e) and 2 (b, d, f) weeks for four types of bone grafts. After 1 week, granulation tissue was present in all defects mostly in R1, whereas blood clot (BC) manly in the R4. BM graft consisted of large (arrows) and serrated particles (a, b), BS of spiral-shaped particles (arrows; c, d), PS of horseshoe-shaped (arrows) and flattened particles (e, f) and BT of plenty of tiny particles also clustered together (arrows; g, h). Bone formation started in R1 after 1 week and reached R4 at 2 weeks.

Fig. 3 Detailed histological view of the bone defects at 1 (a, c, e) and 2 (b, d, f) weeks for four types of bone grafts. At 1 week, bone formation starts in R1, connecting the old bone (OB) to the bone grafts (arrows). Residual blood clot (BC) was retained in some spiral-shaped PS particles (e). The rim of osteoblasts is secreting osteoid matrix. Woven bone (WB) is present in R1 at 1 week in some samples (a, g) and at 2 weeks in all samples (b, d, f, h).

Fig. 4 Detailed histological view of the bone defects at 1 week of healing period. The scalloped bone surface indicates resorptive activity (arrowheads). Osteoclasts (arrows) are round in shape with a high number of nuclei or have a flat appearance and a decreased number of nuclei. The lowest number of osteoclasts is found on BM (a) and the highest on BT particles (d). Osteoclasts seem to severe some thin BS (b) and PS particles (c).

Fig. 5 Histological sections illustrating the bone defect delineated by the old bone (OB) and the ePTFE membrane at 4 (a, c, e) and 8 (b, d, f) weeks for four types of particulate bone grafts. At 4 weeks of healing, many graft particles (arrows) maintained its characteristic shape. All bone grafts are embedded in a trabecular network of new bone. Signs of mineralization are seen in all four regions. After 8 weeks, the bone defects are completely filled with new bone, most compact in R4. The shape of the new bone at some sites reflects the form of the bone grafts. Ingrowth of new blood vessels is shown from the old bone in R1.

Clinical Oral Implants Research

Fig. 6 Detailed histological view of the bone defects at 4 (a, c, e) and 8 (b, d, f) weeks for four types of particulate bone grafts. After 4 weeks of healing is seen parallel-fibered, lamellar bone (LB) deposited on the woven bone (WB). Architecture of new bone resembles the original shape of bone graft particles (arrows). After 8 weeks, both new bone matrix and bone marrow (BM) are mature. New parallel-fibered bone is more lamellar in structure. Completed secondary osteons (*) are bounded by cement lines.

Fig. 7 Histogram illustrating the effect of the harvesting technique on the percentage of total new bone (lines) and residual bone graft (interrupted lines) over time.

Clinical Oral Implants Research

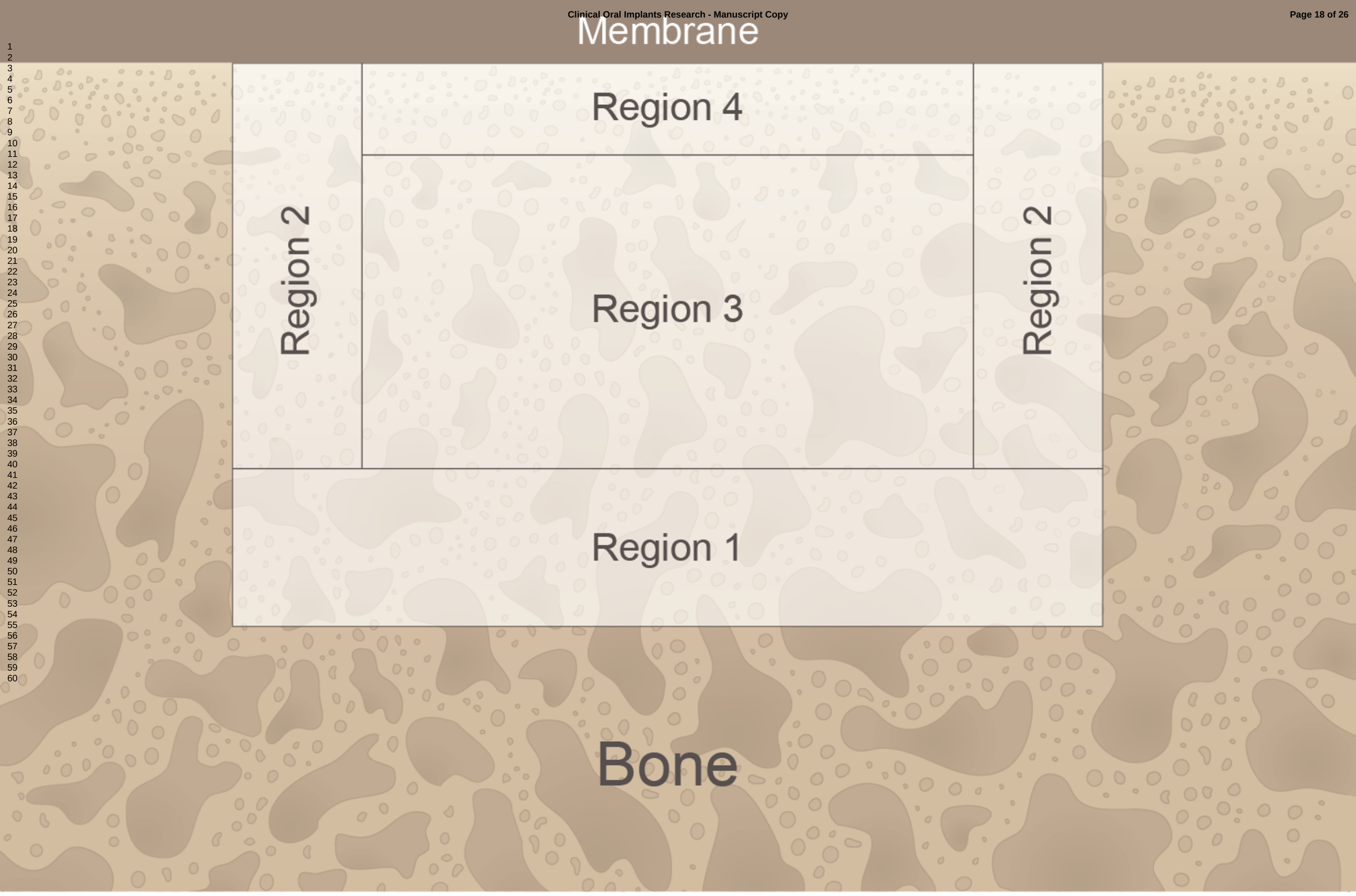

Fig. 1

Clinical Oral Implants Research - Manuscript Copy

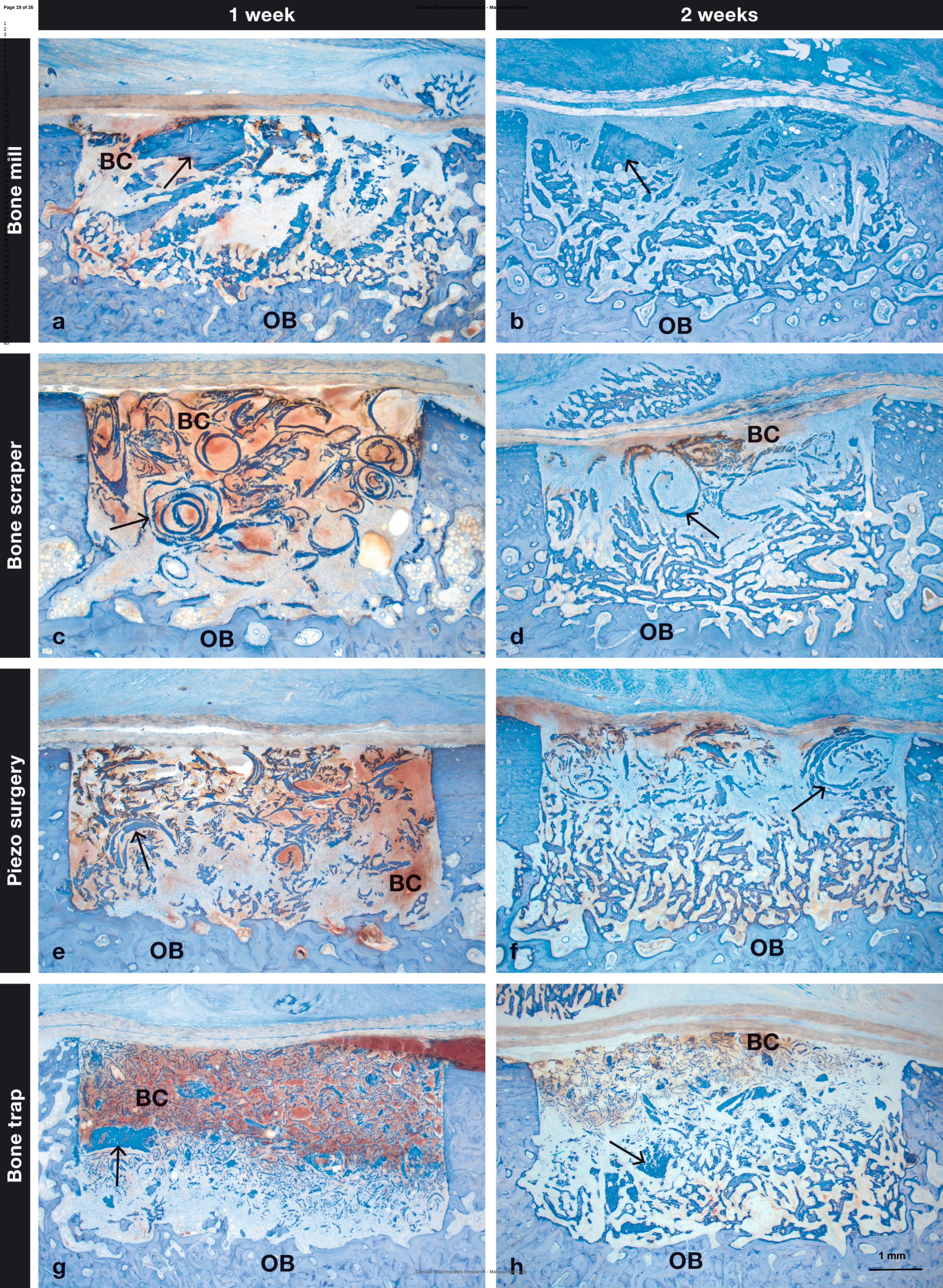

Clinical Oral Implants Research - Manuscript Copy

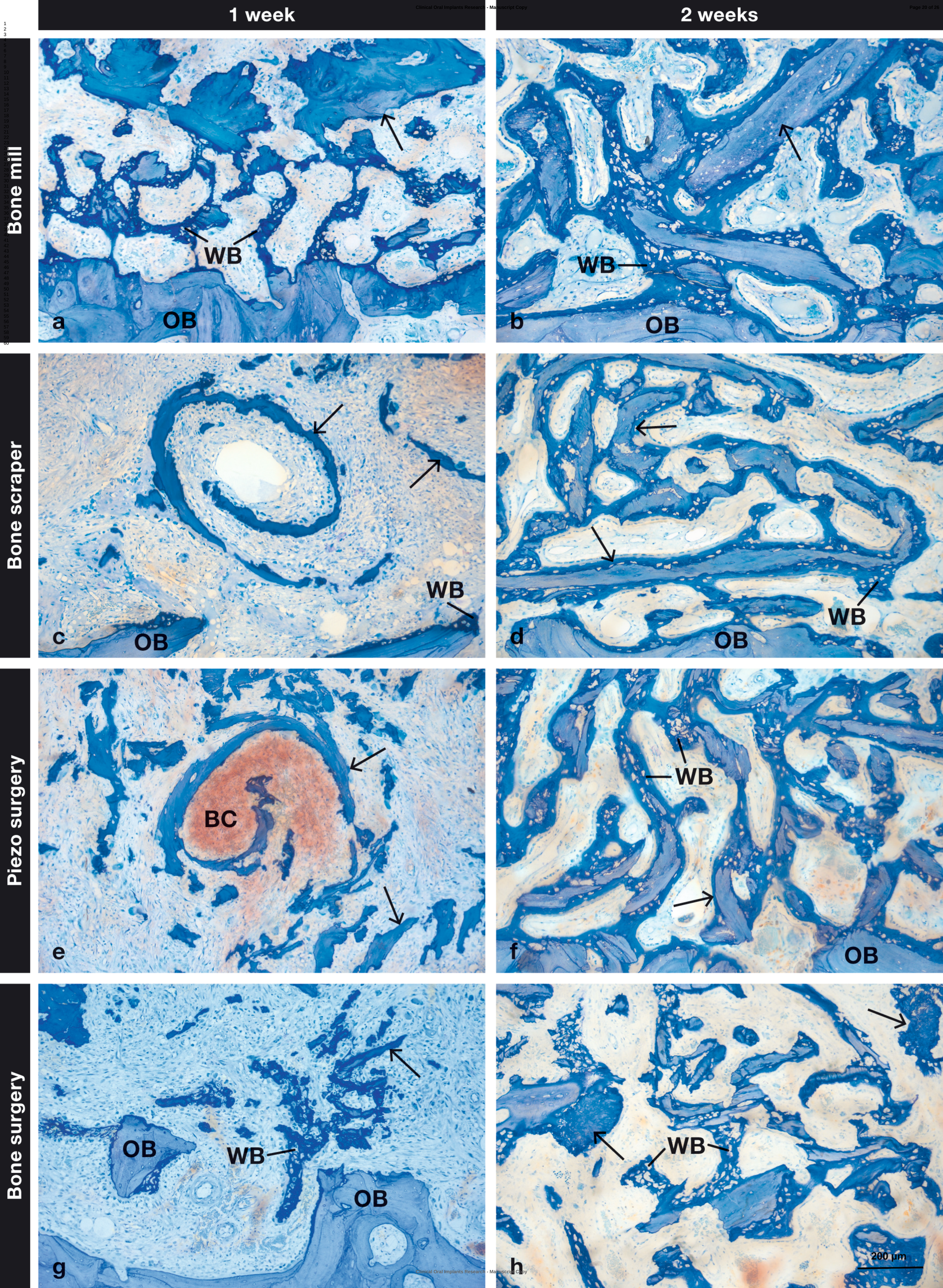
1 week
2 weeks
Bone mill
Bone scraper
Piezo surgery
Bone surgery
WB
OB
a
b
c
d
e
f
g
h
BC
200 µm

Clinical Oral Implants Research - Manuscript Copy

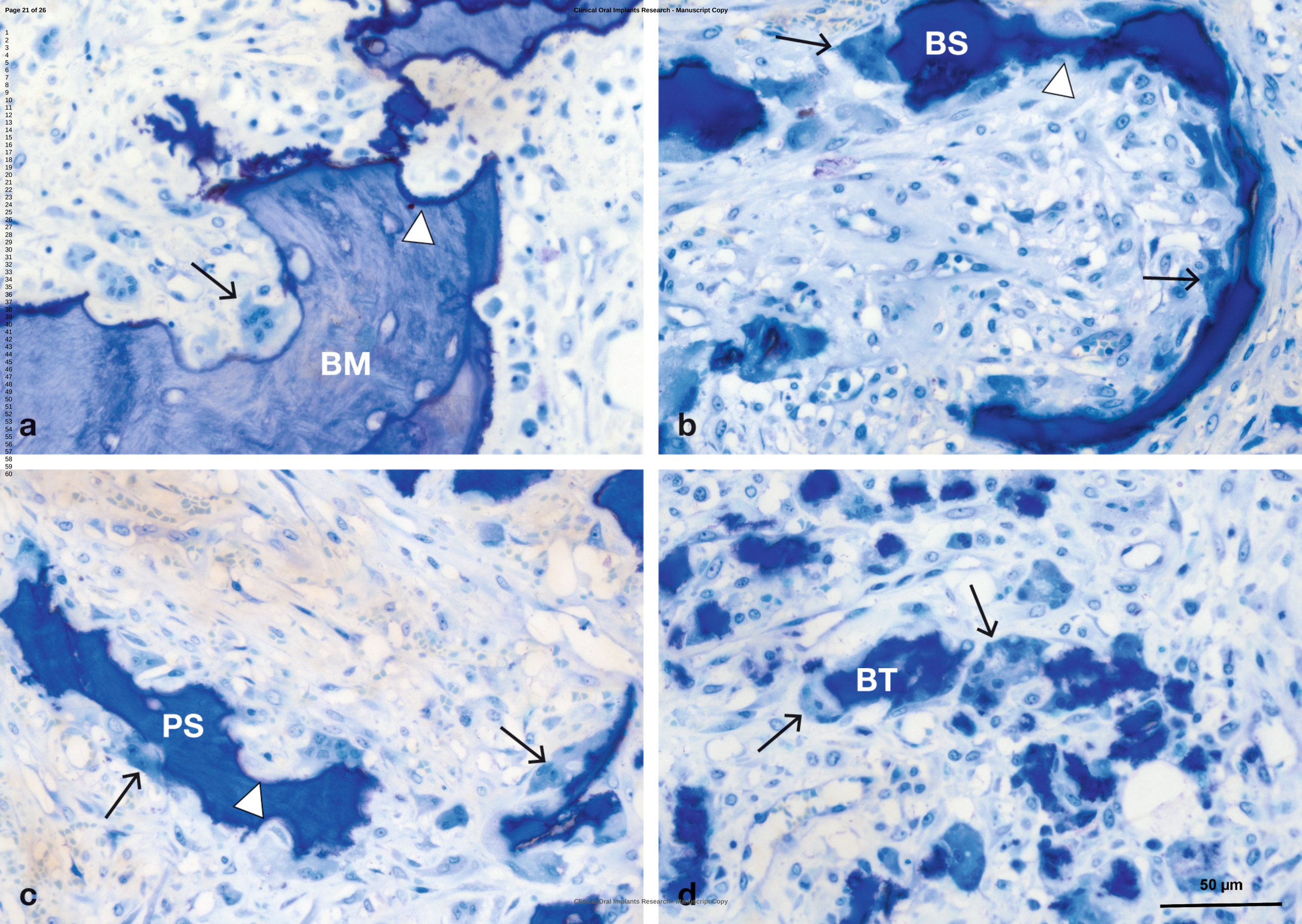

Clinical Oral Implants Research - Manuscript Copy

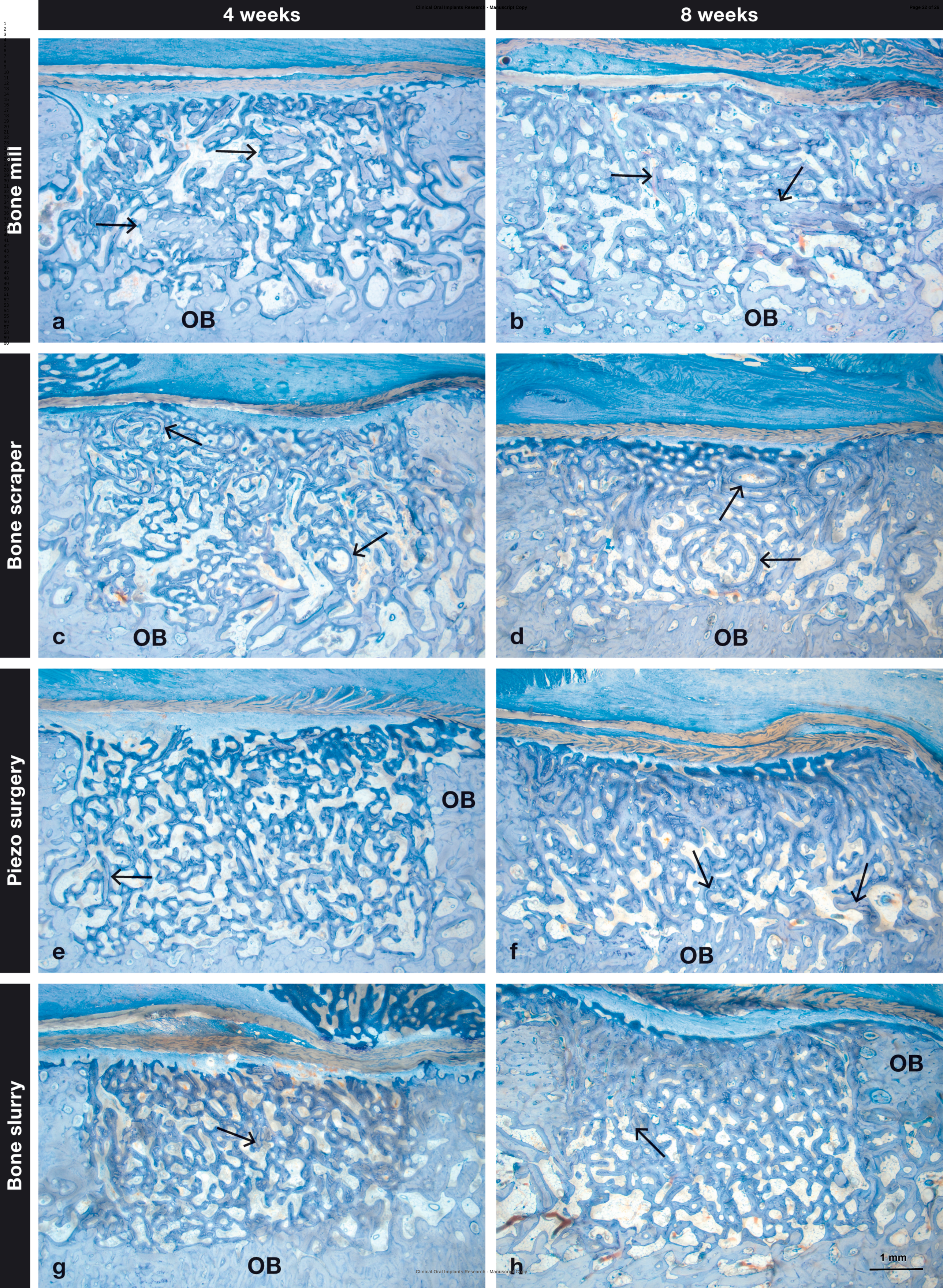
4 weeks
8 weeks
Bone mill
Bone scraper
Piezo surgery
Bone slurry
a
OB
b
OB
c
OB
d
OB
e
OB
f
OB
g
OB
h
OB
1 mm

Clinical Oral Implants Research - Manuscript Copy

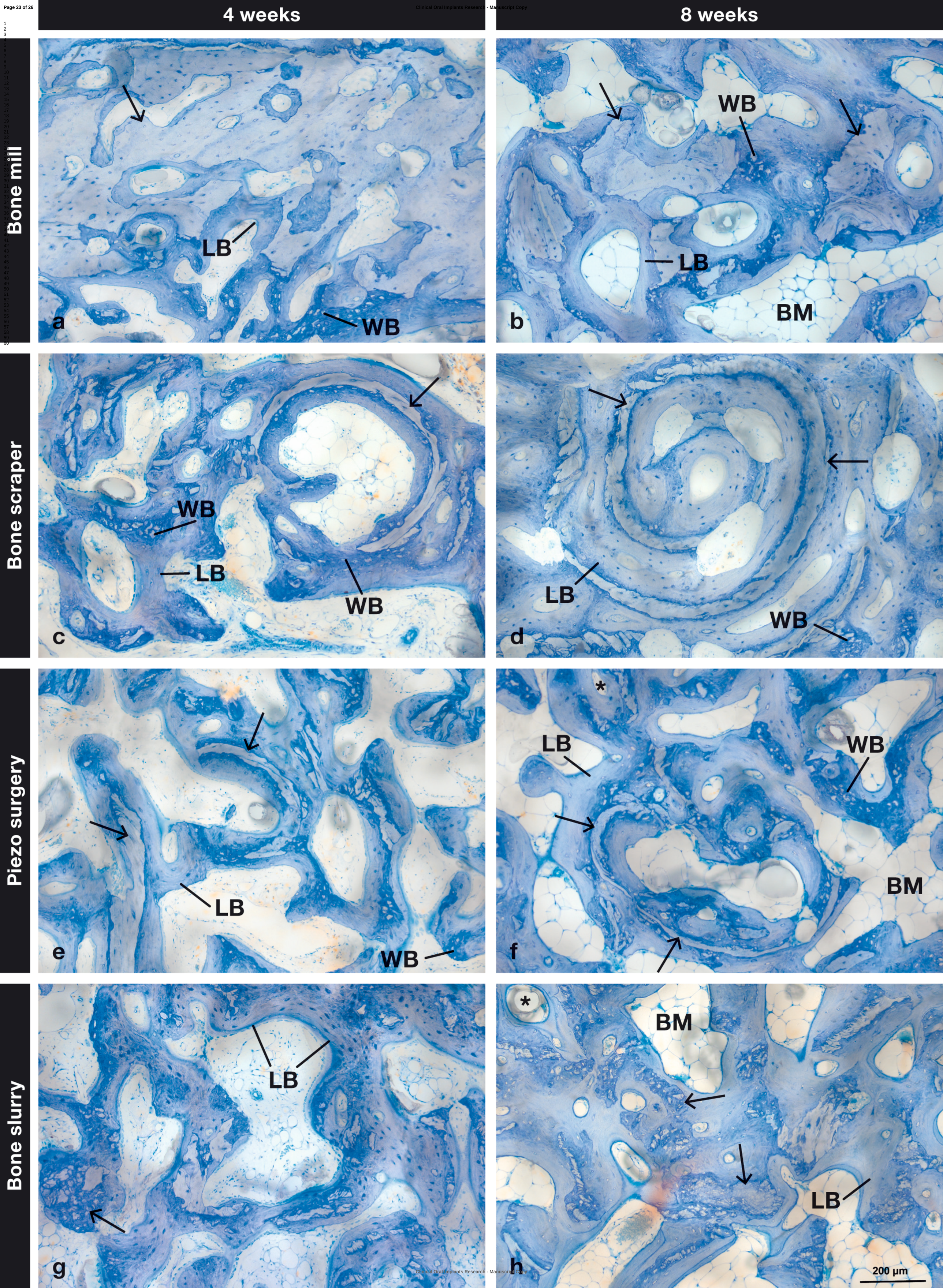

Clinical Oral Implants Research - Manuscript Copy

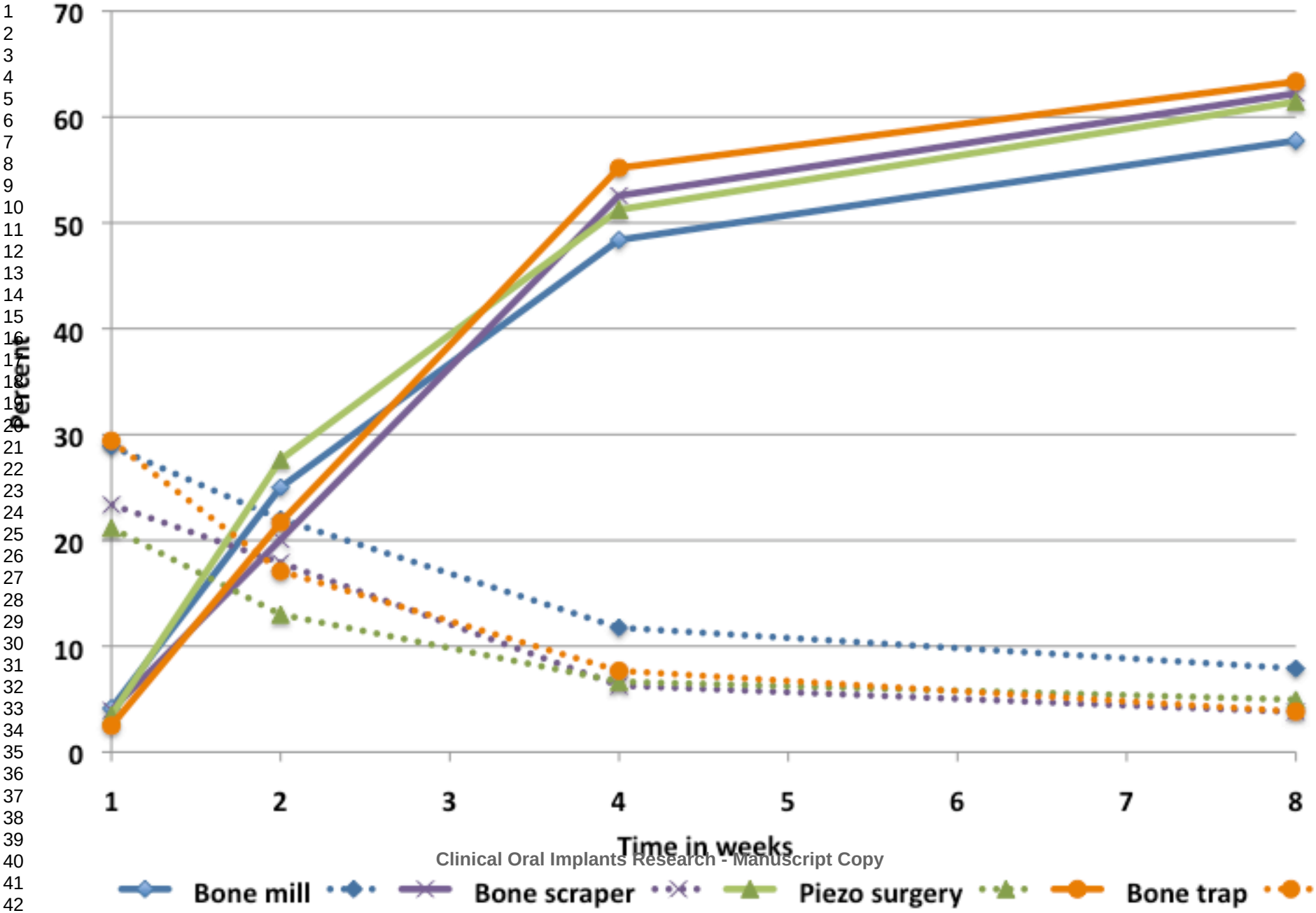

Clinical Oral Implants Research - Manuscript Copy

Table 1. **Percentage of bone chips (residual grafting material), osteoid, mineralized bone, total new bone (osteoid and mineralized bone) and total soft tissue over time occupying the defects for four treatment modalities. Data are shown as means ± SD**

Time point	Bone chip	Residual bone chips	Osteoid	Mineralized bone	Total new bone	Soft tissue
Week 1	Bone mill	28.89 ± 3.11	2.91 ± 2.28	1.23 ± 2	4.13 ± 4.21	66.95 ± 5.56
	Bone scraper	23.37 ± 1.9	2.91 ± 1.29	1.03 ± 1.38	3.94 ± 2.18	72.64 ± 1.46
	Piezosurgery	21.18 ± 3.37	2.72 ± 0.89	0.75 ± 0.62	3.47 ± 1.04	75.28 ± 3.15
	Bone trap	29.41 ± 6.88	1.64 ± 1.4	0.84 ± 1.3	2.49 ± 2.63	67.90 ± 5.98
Week 2	Bone mill	21.99 ± 5.96	9.06 ± 1.42	15.94 ± 6.50	25 ± 7.89	53.01 ± 7.12
	Bone scraper	17.89 ± 5.59	8.94 ± 4.73	11.14 ± 8.37	20.08 ± 11.95	62.03 ± 7.09
	Piezosurgery	13 ± 5.2	10.56 ± 1.91	17.07 ± 7.1	27.63 ± 6.38	59.33 ± 3.57
	Bone trap	17.08 ± 4.84	10.33 ± 2.49	11.36 ± 4.05	21.7 ± 5.43	61.19 ± 4.54
Week 4	Bone mill	11.75 ± 2.16	6.96 ± 1.79	41.43 ± 2.49	48.39 ± 2.42	39.86 ± 1.91
	Bone scraper	6.28 ± 1.39	7.62 ± 1.22	44.95 ± 3.77	52.57 ± 3.49	41.14 ± 3.62
	Piezosurgery	6.65 ± 2.03	7.93 ± 2.24	43.32 ± 6.39	51.24 ± 4.84	42.11 ± 4.82
	Bone trap	7.68 ± 1.89	7.25 ± 0.92	47.94 ± 3.21	55.19 ± 2.78	37.13 ± 2.72
Week 8	Bone mill	7.89 ± 2.9	2.15 ± 0.56	55.61 ± 7.47	57.76 ± 7.71	34.35 ± 5.94
	Bone scraper	3.78 ± 0.82	2.06 ± 0.52	60.16 ± 7.72	62.23 ± 8.05	34 ± 8.3
	Piezosurgery	4.95 ± 1.97	2.16 ± 0.5	59.29 ± 5.04	61.44 ± 4.67	33.6 ± 4.3
	Bone trap	2.83 ± 2.21	1.84 ± 0.61	61.5 ± 5.86	63.35 ± 5.81	32.83 ± 4.01

Clinical Oral Implants Research

Table 2. **Effect of type of bone graft, time and interaction effect (treatment and time) on the amount of residual bone graft and total new bone**

	Type of bone graft		Total new bone	
Healing time	Week 1 vs. week 2		Week 1 vs. week 8	
Effect	Statistic	*P*	Statistic	*P*
Bone graft	11.04	0.2380	1.613	0.1968
Healing time	41.49	< 0.0001	56.11	< 0.0001
Interaction effect	0.5470	0.2465	3.777	0.0198

Clinical Oral Implants Research