adulthood? Results from the Leningrad siege study, a cross sectional study. *BMJ* 1997;**315**:1342–1348.
7. Roseboom TJ, van der Meulen JH, Osmond C, Barker DJ, Ravelli AC, Schroeder-Tanka JM, van Montfrans GA, Michels RP, Bleker OP. Coronary heart disease after prenatal exposure to the Dutch famine, 1944–45. *Heart* 2000;**84**:595–598.
8. Godfrey KM, Lillycrop KA, Burdge GC, Gluckman PD, Hanson MA. Epigenetic mechanisms and the mismatch concept of the developmental origins of health and disease. *Pediatr Res* 2007;**61**:5R–10R.
9. Gluckman PD, Hanson MA, Buklijas T, Low FM, Beedle AS. Epigenetic mechanisms that underpin metabolic and cardiovascular diseases. *Nat Rev Endocrinol* 2009;**5**:401–408.
10. Barker DJ. *Mothers, Babies, and Health in Later Life*. 2nd ed. Edinburgh: Churchill Livingstone; 1998.
11. Singhal A, Lucas A. Early origins of cardiovascular disease: is there a unifying hypothesis? *Lancet* 2004;**363**:1642–1645.
12. Forsdahl A. Living conditions in childhood and subsequent development of risk factors for arteriosclerotic heart disease. The cardiovascular survey in Finnmark 1974–75. *J Epidemiol Community Health* 1978;**32**:34–37.
13. van Abeelen AFM, Elias S, Bossuyt P, Grobbee D, van der Schouw Y, Roseboom C, Uiterwaal C. Cardiovascular consequences of famine in the young. *Eur Heart J* 2012;**33**:538–545. First published on 25 August 2011. doi: 10.1093/eurheartj/ehr228.
14. Li Y, Jaddoe VW, Qi L, He Y, Wang D, Lai J, Zhang J, Fu P, Yang X, Hu FB. Exposure to the Chinese famine in early life and the risk of metabolic syndrome in adulthood. *Diabetes Care* 2011l;**34**:1014–1018.
15. Koupil I, Shestov DB, Sparen P, Plavinskaja S, Parfenova N, Vagero D. Blood pressure, hypertension and mortality from circulatory disease in men and women who survived the siege of Leningrad. *Eur J Epidemiol* 2007;**22**:223–234.
16. McKeigue PM, Ferrie JE, Pierpoint T, Marmot MG. Association of early-onset coronary heart disease in South Asian men with glucose intolerance and hyperinsulinemia. *Circulation* 1993;**87**:152–161.

CARDIOVASCULAR FLASHLIGHT

doi:10.1093/eurheartj/ehr233
Online publish-ahead-of-print 19 July 2011

Takayasu arteritis presenting with extensive bilateral aneurysms of the common carotid arteries

Matthias Renker, Iris Baumgartner*, and Nicolas Diehm

Clinical and Interventional Angiology, Swiss Cardiovascular Center, Inselspital, University Hospital Bern, 3010 Bern, Switzerland

* Corresponding author. Tel: +41 31 632 30 34, Fax: +41 31632 47 93, Email: iris.baumgartner@insel.ch

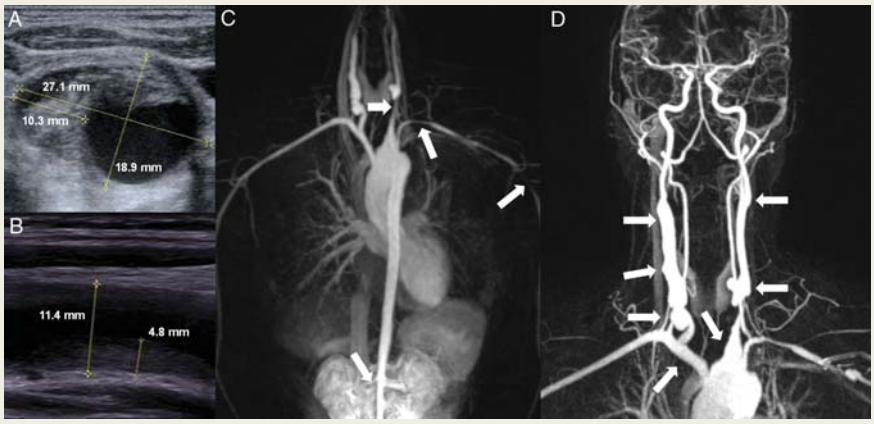

A 17-year-old female patient was referred to our institution for vascular evaluation. She had presented to the general practitioner with a sore throat and elevated inflammatory markers. Prior to hospital admission, additional symptoms appeared despite antibiotic treatment: night sweat, cervical pain, and upper extremity claudication.

During clinical examination, a whirring bruit audible at auscultation led to subsequent ultrasound of the supraaortic arteries. *Figure A* shows a sonographic cross-sectional view of a partially thrombosed right common carotid artery (CCA) aneurysm with a maximum diameter of 27.1 mm. As the longitudinal view of the left CCA in *Figure B* reveals, the wall diameter measured 4.8 mm due to extensive intima-media thickening. By using magnetic resonance angiography (MRA), suspicion of large-vessel vasculitis was substantiated. Magnetic resonance angiography demonstrated a clinical picture pathognomonic for TA with inflammatory vessel wall changes resulting in stenoses (*Figure C*, arrows) and aneurysmatic dilations (*Figure D*, arrows) of the aorta and high-calibre arteries arising thereof.

The extent of these aneurysms is pronounced. Yet, extracranial carotid aneurysms are *per se* a rare finding with TA. Most frequently affected are the aorta, the subclavian artery, and the brachiocephalic trunk.

Therapeutic options may include medication, endovascular revascularization, and surgical measures. Within the present concept, high-dose corticosteroids are applied to de-escalate acute exacerbations, whereas infliximab and methotrexate serve as the maintenance treatment. Furthermore, antiplatelet therapy was established. Since TA has been stable, no interventional or surgical approaches have yet been conducted. Follow-up in this patient involves continuous laboratory assessment, quarterly ultrasound, and annual MRA.

Published on behalf of the European Society of Cardiology. All rights reserved. © The Author 2011. For permissions please email: journals.permissions@oup.com.

source: https://doi.org/10.7892/boris.4285 | downloaded: 12.10.2024