

Cochleovestibular Deficit as First Manifestation of Syphilis in a HIV-Infected Patient

Stefan Weder · Pascal Senn · Marco Caversaccio · Dominique Vibert

Department of Otorhinolaryngology, Head and Neck Surgery, Inselspital, University Hospital, University of Bern, Bern, Switzerland

Key Words

Cochleovestibular deficit · Neurosyphilis · HIV

Abstract

We report the detailed documented case of a 57-year-old homosexual HIV-positive man with bilateral cochleovestibular deficits as a first symptom of syphilis infection in early stage II disease. As a morphological substrate, a strong enhancement of both inner ears and vestibulocochlear nerves were found on gadolinium-enhanced MR scans. The serological tests identified an active infection with *Treponema pallidum*. After a high-dose treatment with penicillin G and prednisolone, the auditory and vestibular functions and the MR morphology of the vestibulocochlear nerves and inner ears on both sides returned to normal.

Introduction

The number of syphilis infections has re-increased in recent years [1]. As a consequence, atypical presentations of the disease reemerged as well [2]. Ootosyphilis represents one of the clinical manifestations of neurosyphilis and may mimic the typical triad of Ménière's disease with fluctuation of hearing, tinnitus and acute vertigo attacks. We report the case of a HIV-positive 57-year-old man, suffering from isolated ootosyphilis, as a first manifestation of syphilis. No other clinical and dermatological signs were found in this case.

Stefan Weder, MD
Department of Otorhinolaryngology, Head and Neck Surgery
Inselspital, University Hospital, University of Bern
CH-3010 Bern (Switzerland)
E-Mail stefan.weder@insel.ch

Clinical Presentation

In June 2010, a 57-year-old homosexual, HIV-positive man was referred to our tertiary ENT referral center with a history of sudden hearing loss three weeks ago on the right and one week ago on the left side. At admission the patient additionally complained of an acute vertigo attack with dizziness for several days. There were no further neurological symptoms, particularly headache or nuchal rigidity. On examination the patient was oriented and conscious with no mental deterioration, there were no clinical signs of further cranial nerve (CN) dysfunction, especially CN VII, the muscle strength, peripheral reflexes and sensation were symmetric and the cerebellar testing was normal. In the context of his HIV disease (CDC stage A3), an infectious origin of the cochleovestibular deficit was suspected and serological screening tests were performed. The Venereal Disease Research Laboratory (VDRL) and *Treponema pallidum* Hemagglutination Assay (TPHA) tests turned out to be highly positive: VDRL with a titer of 64, and TPHA with a titer of 20,480. However, four months prior to admission, the same tests had been negative. Cerebral magnetic resonance imaging (MRI) showed gadolinium enhancement of both inner ears as well as hyperintense signals within both cochleovestibular nerves and the facial nerve on the left side (fig. 1a). The analysis of the cerebrospinal fluid (CSF) revealed an increased cell count of 28 cells/ μ l (normal value: 5 cells/ μ l) with 72% mononuclear and 28% polynuclear cells, and an elevated total protein level of 0.67 g/l (normal value: 0.4 g/l). A complete otoneurological examination was performed, including pure-tone audiogram, brainstem evoked auditory potentials (BEAP), videonystagmography (VNG) and cervical vestibular-evoked myogenic potential (cVEMP: a tone burst stimulus evokes an initial inhibitory potential in the tonically contracted ipsilateral sternocleidomastoid muscle due to activation of the saccule and inferior vestibular nerve). The pure-tone audiogram confirmed a bilateral sensorineural hearing loss (fig. 2a). The BEAP curves with supraliminal stimulation of 75 and 95 dB sound pressure level (SPL) were normal on the right and desynchronized on the left side (fig. 3a). The VNG showed a geotropic (earthward) nystagmus during the Rose maneuver on the left side (the Rose maneuver examines the presence of a positional nystagmus: the patient is lying in supine position with hyperextended head, then the head is turned to the right and left side) as well as a hyporeflexia in the bithermal caloric test on the left side. The cVEMPs were absent on both sides.

In conclusion these findings confirmed the diagnosis of a bilateral otosyphilis with early syphilitic meningitis (stage II). The patient was hospitalized for an intravenous treatment with high doses of penicillin G (24×10^6 IU/day) for 14 days in combination with intravenous prednisolone (100 mg/day) over 5 days. Auditory and vestibular functions subjectively returned to normal within several days to weeks after treatment. The recovery was confirmed in the follow-up pure-tone audiometry (fig. 2b) and BEAP (fig. 3b). The skull MRI only showed a residual minimal contrast enhancement of the 8th cranial nerve on the left side in April 2011 (fig. 1b). Similarly, blood tests from December 2010, February and July 2011 showed a seven-fold decrease of the VDRL and TPHA titer.

Discussion

An isolated, cochleovestibular deficit as a first manifestation of acute syphilis, as shown in this case, has rarely been described in the literature, particularly in HIV patients. The negative VDRL/TPHA tests a few months before the onset of the sudden cochleovestibular dysfunction as well as their high positivity concomitant with the first clinical signs confirmed

this atypical manifestation of early stage II syphilis without further neurological manifestations or other lesions, particularly of the skin. Furthermore, the increased CSF cell count and protein level were compatible with a neurosyphilis.

In this case, a bilateral inflammation with gadolinium enhancement of the cochleae as well as the 7th and 8th cranial nerves was observed. In the literature, the enhancement of the cochlea, as sign of syphilitic labyrinthitis, is interpreted as the result of the spread of the inflammatory process via the endolymphatic or perilymphatic fluids [3]. Theoretically a hematogenous dissemination to the cochlea and further spread via the 7th and 8th nerves is possible [3] but less plausible in the presence of meningitis. Nevertheless, in our HIV-positive patient (CDC stage A3) the alteration in cell-mediated immunity might explain an unusual progression of syphilis differing from the natural history of the disease [4].

In syphilis, the cochleovestibular dysfunction can be due to either a lesion of the inner ear itself or of the cranial nerves. Indeed, the seventh and eighth nerves are particularly often involved [5]. Gumma of the cochleovestibular nerve has also been reported as mimicking the neuroradiological imaging of a neurinoma of the 8th nerve [6].

Clinically, the triad of hearing loss, tinnitus, and vertigo and/or dizziness is often similar to symptoms of Ménière's disease and otosyphilis is known as one of the etiologies of the endolymphatic hydrops. The histopathological findings range from an initial mononuclear leukocyte infiltration to an advancing obliterative endarteritis with osteitis and fibrosis at the late stage. These lesions generate the endolymphatic hydrops with progressive degeneration of the membranous labyrinth [7–9].

The diagnosis of otosyphilis is based on the results of the otoneurological examination. The pure-tone audiogram shows a unilateral and/or bilateral sensorineural hearing loss without a specific audiometric pattern [2]. Rosenhall et al. [10] reported abnormal BEAP with prolonged wave V latency and I-V interval, as well as abnormal interaural time differences. Nevertheless, abnormal BEAP were also reported within asymptomatic HIV patients as signs of subclinical brainstem lesions in the early stages of the disease in absence of neuroradiological and neurological signs [11]. In our patient, the fact that BEAP returned to normal one year after the acute cochleovestibular deficit, suggests that the pathologic findings were due to the syphilis infection and not related to the HIV itself. The favorable evolution of the cochleovestibular function with highly dosed antibiotics and corticosteroids is indicative that the histopathological damage was reversible and might correspond to the early stage of mononuclear leukocyte infiltration.

Taking into account that many patients with syphilis and cochleovestibular involvement suffer also from neurosyphilis, it is recommended to treat every otosyphilis like a neurosyphilis [2]. Therefore high concentrations of antibiotics are necessary to penetrate into the cerebrospinal fluid and endolymph space. In case of symptomatic and asymptomatic otosyphilis, the treatment of choice is aqueous crystalline penicillin G 18–24 million units per day, administered as 3–4 million units intravenously every 4 hours or by continuous infusion for 10–14 days [1]. The additional benefit of corticosteroids is controversially discussed in the literature particularly in HIV-positive patients, due to the risk of opportunistic infections and neoplasia [1, 2].

After treatment, the monitoring of the cochleovestibular function can be accomplished with pure-tone audiometry, otoacoustic emissions (sounds generated spontaneously or in response to an acoustic stimulus in the inner ear, which are measurable by a microphone inserted in the external ear canal), BEAP, ENG and cVEMPs. In HIV patients, the persistence of abnormal BEAP might be interpreted as either the electrophysiological manifestation of the syphilitic vascular involvement in the brainstem inducing a definitive loss of the affected neurons [10] or in relation with the HIV infection itself.

If CSF pleocytosis is present initially, lumbar puncture should be performed every 6 months until normalization of the cell count [12]. Indeed, a successful treatment shows a decrease of the CSF pleocytosis, a normalization of the blood-brain barrier within months, a decrease of the IgM-antibody kinetics within 6–12 months and a three- to fourfold decrease of the VDRL titer. In our patient a sevenfold decrease of VDRL titer was recorded after six months.

Conclusion

Clinicians should be aware of signs and symptoms related to syphilis, particularly because this treatable disease and its atypical presentations have reemerged in recent years. Patients at risk, particularly HIV-positive patients, presenting with acute auditory and vestibular symptoms should routinely receive serological testing to rule out syphilis. Recognized in the early stage of the disease, the cochleovestibular manifestations of syphilis can be successfully treated using high doses of intravenous penicillin G and additional intravenous corticosteroids depending on the case.

References

- 1 Centers for Disease Control and Prevention: Sexually transmitted disease treatment guidelines, 2006. *Morbidity and Mortality Weekly Report* 2006;55:40–43.
- 2 Mishra S, Walmsley SL, Loutfy MR, Kaul R, Logue KJ, Gold WL: Orosyphilis in HIV-coinfected individuals: a case series from Toronto, Canada. *AIDS Patient Care and STDs* 2008;22:213–219.
- 3 Smith MM, Anderson JC: Neurosyphilis as a cause of facial and vestibulocochlear nerve dysfunction: MR imaging features. *AJNR Am J Neuroradiol* 2000;21:1673–1675.
- 4 Johns DR, Tierney M, Felsenstein D: Alteration in the natural history of neurosyphilis by concurrent infection with the human immunodeficiency virus. *N Engl J Med* 1987;316:1569–1572.
- 5 Harris DE, Enterline DS, Tien RD: Neurosyphilis in patients with AIDS. *Neuroimaging Clin N Am* 1997;7:215–221.
- 6 Little JP, Gardner G, Acker JD, Land MA: Orosyphilis in a patient with human immunodeficiency virus: internal auditory canal gumma. *Otolaryngol Head Neck Surg* 1995;112:488–492.
- 7 Schuknecht HF: *Pathology of the Ear*. Cambridge, Harvard University Press, 1974, pp 262–266.
- 8 Linthicum FH Jr, el-Rahman AG: Hydrops due to syphilitic endolymphatic duct obliteration. *Laryngoscope* 1987;97:568–574.
- 9 Belal A Jr, Linthicum FH Jr: Pathology of congenital syphilitic labyrinthitis. *Am J Otolaryngol* 1980;1:109–118.
- 10 Rosenhall U, Löwhagen GB, Roupe G: Auditory function in early syphilis. A follow up study. *J Laryngol Otol* 1984;98:567–572.
- 11 Korálnik IJ, Beaumanoir A, Häusler R, Kohler A, Safran AB, Delacoux R, Vibert D, Mayer E, Burkhard P, Nahory A, et al: A controlled study of early neurologic abnormalities in men with asymptomatic human immunodeficiency virus infection. *N Engl J Med* 1990;323:864–870.
- 12 Workowski KA, Berman S: Centers for Disease Control and Prevention (CDC). Sexually transmitted diseases treatment guidelines, 2010. *MMWR Recomm Rep* 2010;59:1–110.

Weder et al.: Cochleovestibular Deficit as First Manifestation of Syphilis in a HIV-Infected Patient

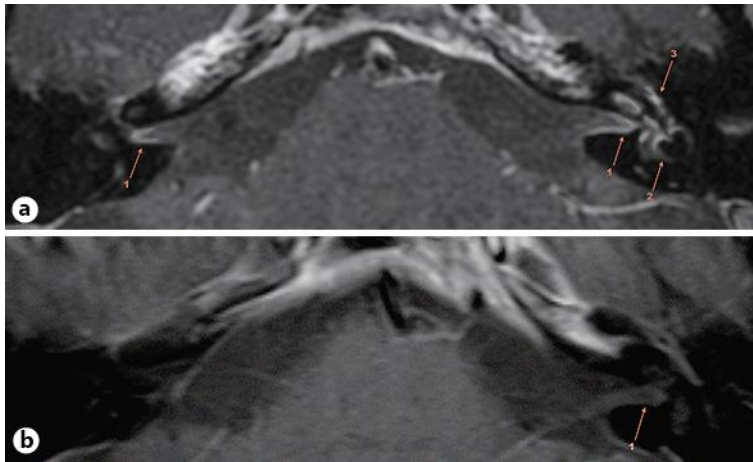


Fig. 1. MRI studies of the skull base focusing on the pontocerebellar angles in the acute stage (**a**) and 9 months later following successful treatment and functional recovery (**b**). **a** In the acute stage, gadolinium contrast agent enhancement of the 8th cranial nerves on both sides (1), both inner ears with predominance on the left (2) and the facial nerve on the left (3) were found. These findings were interpreted as a result of a spread of the inflammatory process via the endolymphatic and/or the perilymphatic fluids. **b** In April 2012, the MRI only showed a slight residual enhancement of the 8th cranial nerve on the left side (1), while the MR morphology of the other structures had returned to normal.

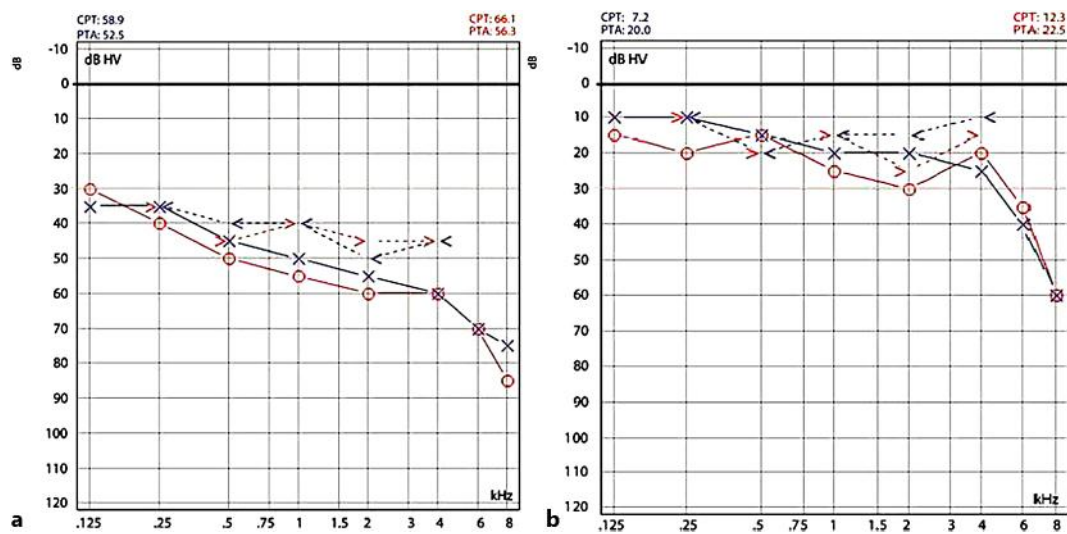


Fig. 2. Pure-tone audiometry thresholds at initial presentation with sensorineural hearing loss (**a**) and with close-to-normal auditory function one year after treatment (**b**).

Weder et al.: Cochleovestibular Deficit as First Manifestation of Syphilis in a HIV-Infected Patient

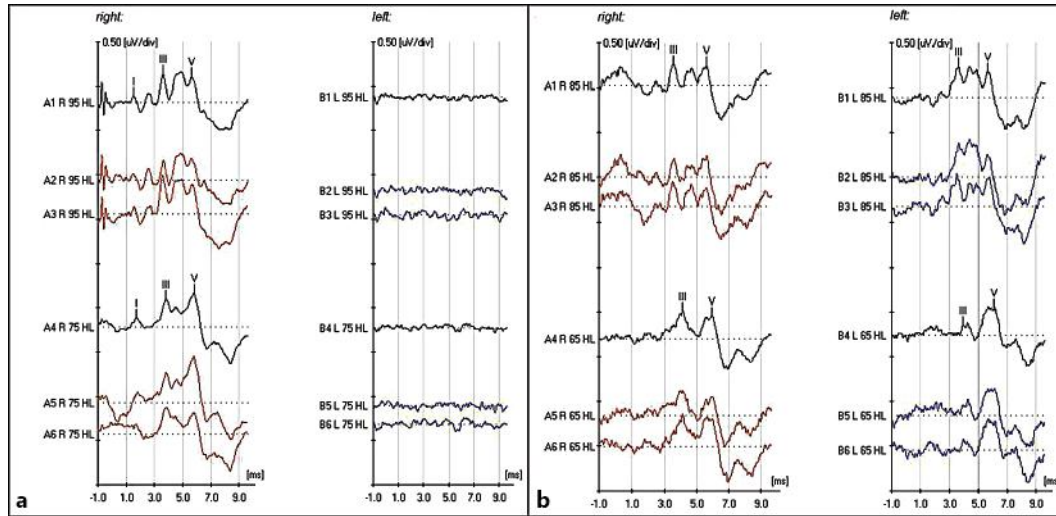


Fig. 3. **a** The BEAP curves with supraliminal stimulation of 75 and 95 dB SPL: normal on the right and desynchronized on the left side. **b** BERA performed one year after the acute event with supraliminal stimulation: absence of wave I on both sides, normalization of waves III and V on the left side.