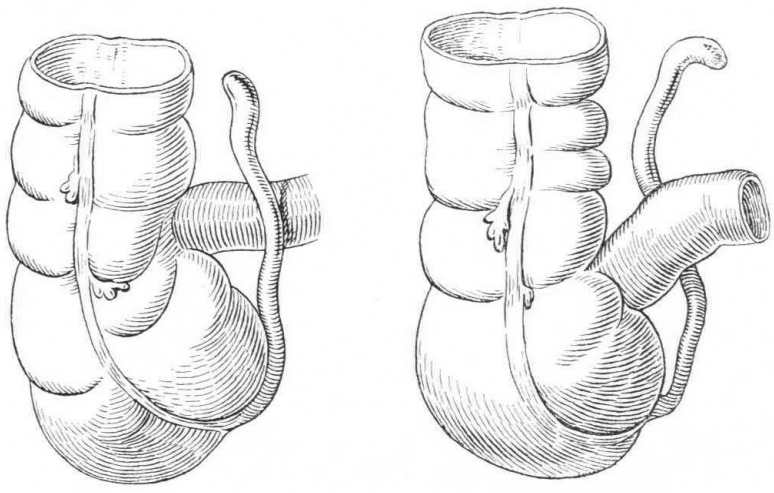


Neonatal appendicitis:
a short report of a favorable
course

Source: <https://doi.org/10.7803/hormi.4563> | downloaded: 24.4.2024

OCTOBER 2011



A twin preterm baby boy was delivered at a gestational age of 33 5/7 weeks to a 36-year-old G3/P1. Antenatal steroids were given at 31 weeks for premature contractions and, at 33 5/7 weeks, an elective caesarean section was performed because of intrauterine growth restriction and pathological umbilical cord Doppler in the index patient. Apgar scores were 9, 10, 10 at 1, 5 and 10 minutes, respectively, and the umbilical cord pH was normal.

He was small for gestational age with a birth weight of 1430g (-2.2 SD); length and head circumference were on the 8th and 30th percentile, respectively. Apart from mild respiratory distress and one day of phototherapy for unconjugated hyperbilirubinemia, the initial postnatal course was uncomplicated. The baby tolerated enteral feeds well and parenteral nutrition could be stopped on the 6th day of life.

On the 11th day of life, an initially painless mass of approximately 3 cm was palpated in the right lower abdominal quadrant on routine physical examination. The following day, the mass was noted to be tender. The baby was otherwise well and there were no signs of sepsis or peritonitis. He tolerated feeds and his stools were normal. Laboratory findings showed a slightly elevated C-reactive protein of 25 mg/L. On abdominal ultrasound examination, thickening of the bowel wall in the right lower quadrant was noted. Increased echogenicity of the mesenteric fat

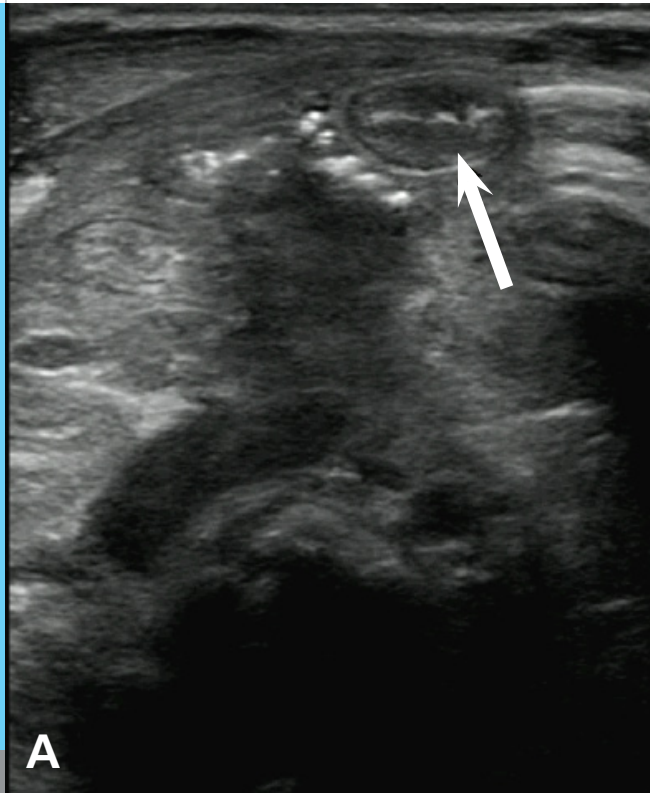
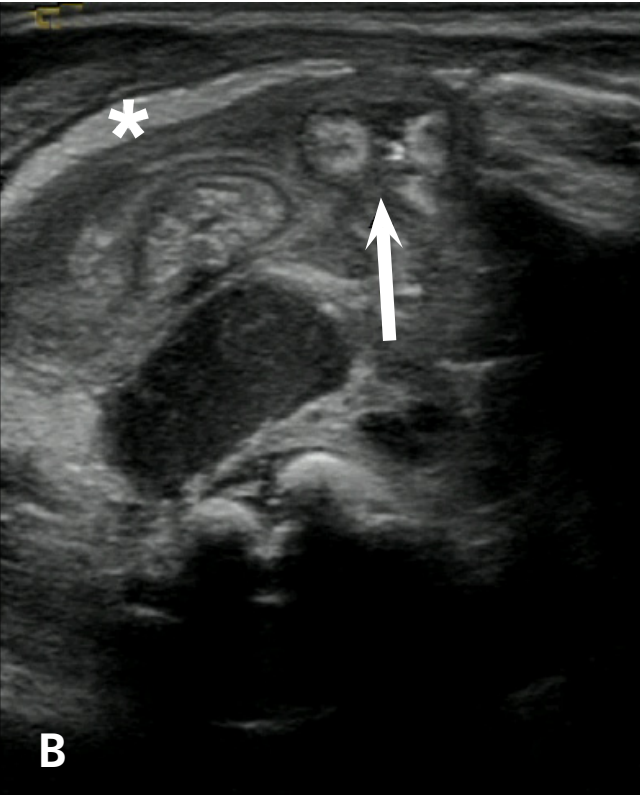



Fig. 1

A

Abdominal ultrasound examinations: A) Normal distal appendix (arrow) with hypoechoic bowel wall. There are hyperechoic dots adjacent to the appendix consistent with free gas; B) On a cine-clip, the more proximal appendix shows increased echogenicity of the bowel wall and an interruption of the dorsal bowel wall (arrow) consistent with perforated appendicitis. There is increased echogenicity of the mesenteric fat (asterisk) consistent with inflammatory changes and adjacent hypoechoic pus.

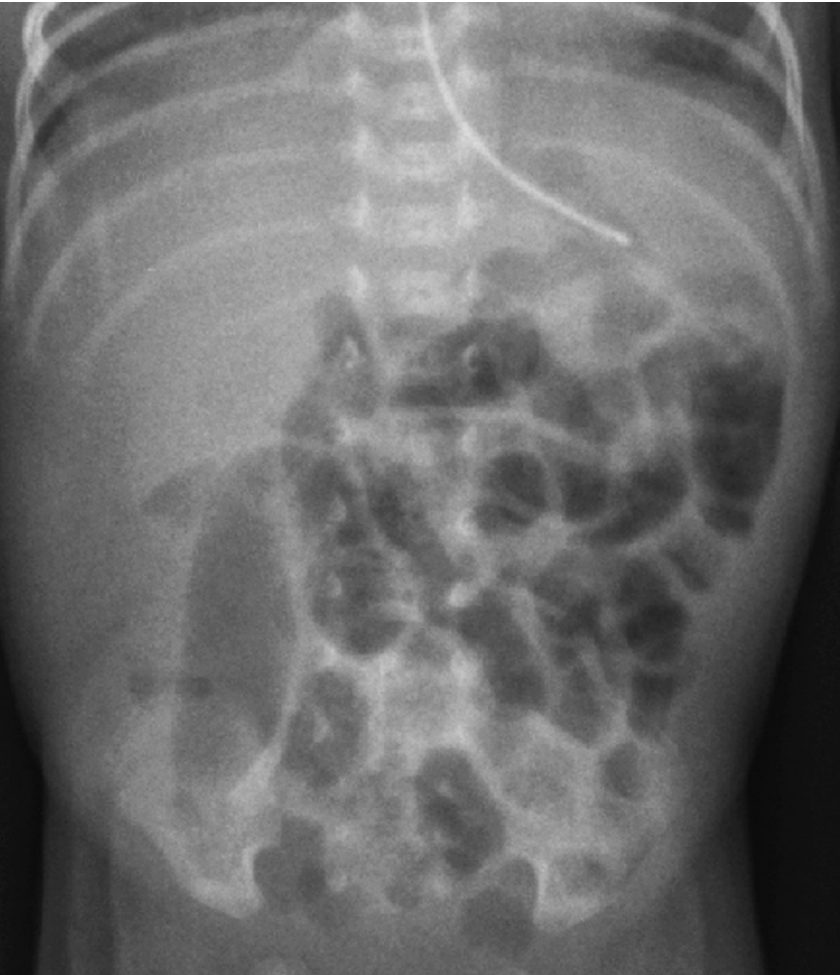


B



was consistent with inflammatory changes. On retrospective evaluation of the high frequency linear transducer cine clip the more distal part of the appendix was clearly visible. Proximally, the appendix was more than 7 mm in diameter with a dorsal perforation and adjacent fluid or pus collection (Fig. 1). Initially, the findings were thought to be compatible with necrotizing enterocolitis and perforation or perforated appendicitis. An abdominal radiograph showed a nearly gas-free right hemiabdomen and small air bubbles in the right lower quadrant (Fig. 2). Broad-spectrum antibiotic therapy was started with amikacin and amoxicillin/clavulanic acid and a laparotomy was performed. Intraoperatively, the appendix was in a retrocecal and retrocolic cranial position and there was an occult perforation. There were no signs of necrotizing enterocolitis and neither a mechanical obstruction nor an intestinal malformation were noted. Histology showed inflammation of the appendix with perforation (Fig. 3).

The baby's postoperative recovery was uneventful and he was discharged from the hospital on the 6th postoperative day.

**Fig. 2**

Abdominal radiograph with mildly distended intestinal loops, a possible mass effect in the right hemiabdomen and small areas of free gas in the right lower quadrant compatible with an inflammatory process such as NEC with bowel perforation or meconium peritonitis or perforated appendicitis.

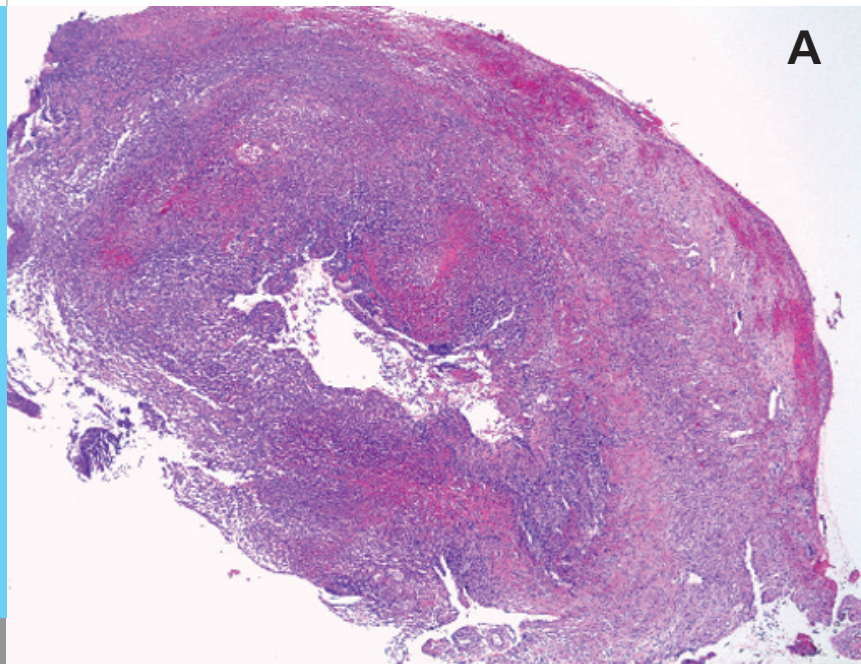
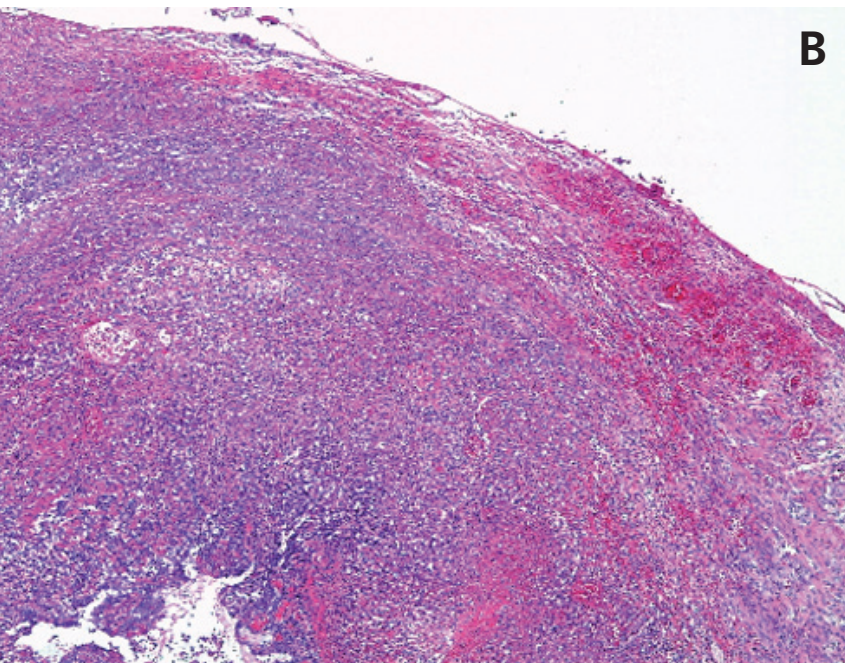


Fig. 3

Acute suppurative and hemorrhagic inflammation of the central part of the appendix vermiformis (panel A). Note the beginning disintegration of the wall in the vicinity of the perforation (panel B, upper half). Less inflammation was present at the surgical resection margins (H&E).



DISCUSSION

Neonatal appendicitis is a rare condition with a reported incidence of $< 0.04\%$; about 140 cases have been reported in the literature so far (1, 2). Males predominate and 25-50% of the neonatal patients are preterm infants (1-3). The rarity of appendicitis has been attributed to various factors, such as the broad funnel-shaped orifice of the appendix, the relative infrequency of lymphatic hyperplasia in the periappendiceal region caused by lack of infectious stimuli as well liquid diet, recumbent position and lack of fecoliths (1-4). Appendicitis in the neonate is often associated with other conditions such as Hirschsprung's disease, meconium plug syndrome, NEC, or inguinal hernias.

The pathogenesis of acute appendicitis in the neonate is unclear and various theories have been proposed. In their review, Jancelewicz et al. (1) discuss 3 theories concerning the pathogenesis of appendicitis in the neonate. According to the first theory, appendicitis in the newborn is an isolated form of necrotizing enterocolitis (NEC), which implies that impaired immunity or systemic infection may be responsible. A second theory, which is also closely linked to theories concerning the pathogenesis of NEC, suggests that ischemia and decreased perfusion of the intestine, associated with conditions such as perinatal asphyxia, cardiac anomalies and ECMO exposure, may increase the risk. Thirdly, obstructive cecal distension with increased pressure at the appendiceal base associated with meconium ileus

or Hirschsprung's disease may lead to perforation of the appendix.

The clinical presentation of neonatal appendicitis is highly variable and does not have the characteristic features seen in older children (4). The most frequent symptoms are irritability, poor feeding, vomiting, abdominal distension, abdominal wall edema and sometimes a palpable mass in the right lower quadrant (2).

The diagnosis is often delayed or made at laparotomy, resulting in a higher morbidity and mortality in the perinatal period than for other age groups (1). The perforation rate is relatively high at over 70%, which is probably secondary to the thin appendicular wall and delayed diagnosis (2). Mortality rates up to 64% and more recently 28% have been described (4).

In our patient, the only symptoms present were a palpable abdominal mass and localized abdominal tenderness. Appendicitis was considered in the differential diagnosis but despite this, the appendix had already perforated. The co-existent conditions were prematurity, intrauterine growth restriction with pathological umbilical cord Doppler examinations and mild respiratory distress after birth.

REFERENCES

1. Jancelewicz T, Kim G, Miniati D. Neonatal appendicitis: a new look at an old zebra. *J Pediatr Surg* 2008;43:e1-e5
2. Karaman A, Cavusoglu YH, Karaman I, Cakmak O. Seven cases of neonatal appendicitis with a review of the English language literature of the last century. *Pediatr Surg Int* 2003;19:707-709
3. Managoli S, Chaturvedi P, Vilhekar KY, Gupta D, Ghosh S. Perforated acute appendicitis in a term neonate. *Indian J Pediatr* 2004;71:357-358
4. Bundy DG, Byerley JS, Liles EA, Perrin EM, Katznelson J, Rice HE. Does this child have appendicitis? *JAMA* 2007;298:438-451

SUPPORTED BY



CONTACT

Swiss Society of Neonatology
www.neonet.ch
webmaster@neonet.ch