Neuroimaging of Temporal Lobe Epilepsy: Lesions and Networks

Eugenio Abela[1,2], Christian Rummel[2], Martinus Hauf[2,3], Christian Weisstanner[1], Kaspar Schindler[1], Roland Wiest[2]

[1] Department of Neurology, Inselspital, University Hospital Bern, University of Bern

[2] Support Center for Advanced Neuroimaging (SCAN), University Institute of Diagnostic and Interventional Neuroradiology, Inselspital, University of Bern

[3] Klinik Bethesda, Tschugg

Supported by the Swiss National Foundation (SNF), grant numbers 33CM30-140332 and 33CM30-124089

Summary

Recent research using multimodal neuroimaging has revealed that focal-onset epilepsies are accompanied by pathological changes in brain structure and function that extend far beyond the site of primary injury. These findings lend support to the notion that epilepsies are in fact network disorders, and that their clinical presentation, time course and treatment responsiveness might critically depend on network-wide effects. Although the network hypothesis is not new, current advances in neuroimaging technology have made it directly quantifiable – in vivo, non-invasively, with high spatiotemporal resolution and minimal inconvenience for the patient. In this article, we provide an overview of recent studies using advanced morphometric and functional magnetic resonance imaging (MRI), show how these modalities can be combined with one another and/or electroencephalographic (EEG) data and present clinical examples of how these techniques might be applied in practice.

Epileptologie 2013; 30: 131 – 137

Key words: Temporal lobe epilepsy, lesion localization, functional connectivity, network effects

Neuroimagerie de l'épilepsie du lobe temporal : lésions et réseaux

Des recherches récentes utilisant la neuroimagerie multimodale ont révélé que les épilepsies focales sont accompagnées par des changements pathologiques de la structure et la fonction cérébrale qui s'étendent bien au-delà du site de la lésion primaire. Ces résultats renforcent la notion que les épilepsies sont en fait des maladies de réseaux et que leur présentation clinique, leur évolution et leur réponse au traitement peut dépendre d'effets à l'échelle du réseau entier. Bien que l'hypothèse de réseau ne soit pas nouvelle, les avancées des techniques de neuroimagerie on rendu cette hypothèse directement quantifiable in vivo, de manière non-invasive avec une haute résolution spatiotemporelle et des inconvénients minimes pour le patient. Dans cet article, nous discutons des études récentes utilisant l'imagerie par résonance magnétique (IRM) fonctionnelle et morphométrique. Nous montrons comment ces techniques peuvent être combinées entre elles et avec les données électro-encéphalographiques (EEG) et nous présentons des exemples cliniques de leur applications.

Mots clés : Epilepsie du lobe temporal, localisation, connectivité fonctionnelle, effet des réseaux

Bildgebung bei Temporallappenepilepsie: von der Läsion zum Netzwerk

Fortschritte in der multimodalen Bildgebung haben neue Erkenntnisse zu den pathologischen Korrelaten fokaler Epilepsien erbracht. Insbesondere zeigt sich, dass die strukturellen und metabolischen Veränderungen weit ausgedehnter sind, als es die fokale Natur dieser Erkrankungen erahnen lassen würde. Dies hat zum Konzept geführt, fokale Epilepsien als Netzwerkerkrankungen zu verstehen, deren Symptomatik, Verlauf und therapeutische Modulierbarkeit sowohl von lokalen wie über das gesamte Netzwerk greifenden Effekten bestimmt werden. Modernes Neuroimaging kann Gehirnnetzwerke in kurzer Zeit mit minimaler Belastung für den Patienten darstellen und damit zu einem integralen Verständnis fokaler Epilepsien beitragen. In diesem Artikel geben wir eine kurze Übersicht zur Darstellung von Netzwerkeffekten fokaler epileptogener Läsionen mittels morphometrischer und funktioneller Neuroimaging-Studien anhand zweier klinischer Beispiele.

Schlüsselwörter: Temporallappenepilepsie, Läsionslokalisation, funktionelle Konnektivität, Netzwerkeffekt

Introduction

It has been known since the work of Ramón y Cajal (1852-1934) that the brain is basically a vast, dynamic, densely connected biological network of breathtaking complexity [1]. Much of clinical neurology to date, including epileptology, has mainly focused on identifying critical nodes within network structures in order to identify lesions that e.g. cause hemiparesis or generate seizures. However, it is well known that a lesion can exert distributed effects across large-scale brain network, leading to metabolic dysfunction or structural alterations of remote brain areas connected to the primary lesion site [2, 3]. An example of these effects is crossed cerebellar diaschisis, classically described as a reduction in regional cerebellar blood flow contralateral to a supratentorial ischemic lesion [4 - 6], but also apparent during focal epileptic seizures and status epilepticus [7, 8]. Indeed, using advances multimodal neuroimaging techniques, network-wide effects have been increasingly recognized in focal epilepsies [3, 9]. It has therefore been proposed to view epilepsies as a „network disorder“ and to integrate local and remote effects into a systems-level model of disease [3, 9 - 11] that would expand the well-known zonal concept commonly used in epileptology [12]. In this article, we provide a brief overview of structural and functional imaging findings that support the network hypothesis in epilepsy. We focus on temporal lobe epilepsies (TLE), because they represent the most prevalent form of focal epilepsies and one of the most frequently investigated with neuroimaging [13, 14]. Also, they can be used as a paradigm for network-wide effects of focal lesions, given their often (at least visually) restricted pathology to structures of the temporal lobe.

Lesion Analysis in TLE

The hallmark of mesial TLE (MTLE) is hippocampal or mesial temporal sclerosis (MTS), which is detected by MRI in 75-85% of the patients [15]. Current clinical MRI protocols for temporal lobe abnormalities incorporate high-resolution T1w, T2w and FLAIR imaging, with at least one set of T2w or FLAIR coronal slices perpendicular to the long axis of the hippocampus [16] . Interpretation should focus on hippocampal volume, increased signal intensity on T2-weighted imaging, and disturbed internal architecture. The presence of MTS on preoperative MRI is predictive for good outcome after epilepsy surgery [17], whereas preoperative temporal lobe volume differences provided equivocal results [18, 19]. In non-lesional MTLE 18F-fluorodeoxyglucose-positron emission tomography (FDG-PET) is predictive for good surgical outcome; whereas an added value of 11C-Flumazenil-PET (FMZ-PET) and proton magnetic resonance spectroscopy (MRS) has not been established [20]. Subtle focal cortical dysplasia may coincide in the temporal lobe or in extratemporal areas ipsilateral to the MTS [21]. While clinical applications of automated voxel-based analyses and cortical thickness analysis for individual patients with MTLE are still experimental, improvements within a range of 10-30% in the detection rate of focal cortical dysplasias have been reported [22 - 24]. In addition to conventional MRI, advanced imaging techniques as functional MRI and tractography lateralize eloquent brain areas (language and motor function), predict effects of temporal lobe resection on memory and visualize the topography and composition of cerebral white matter tracts [25].

Network Analysis in TLE

While lesion analysis and interpretation is the essential task for the neuroradiologist in clinical practice, a substantial body of epilepsy research has shown that focal lesions influence brain areas beyond the epileptogenic lesion, across ensembles of functionally and anatomically connected brain areas [26 - 30] characterized by coherent physiological activity, such as high-frequency oscillations on EEG or low-frequency (< 0.1Hz) blood oxygen level dependent (BOLD) signal fluctuations. The BOLD signal is the most commonly used contrast mechanism in functional MRI and is thought to reflect the hemodynamic response of the brain to exogenous stimuli (such as an image or a tone) or endogenous neural activity (such as interictal epileptiform discharges). Covariance analysis of these fluctuations determines areas of the brain that form functionally connected networks. More than twenty independent networks have been identified that correspond to intrinsic and extrinsic systems, and are associated with internal- and external-oriented processing, respectively [31]. Many studies that investigated alterations of gray matter volume and concentrations using MRI-based automated analysis techniques as voxel-based morphometry and cortical thickness analysis on a whole brain level have shown that structural changes in mTLE patients are not restricted to the hippocampus or the elements of the mesial temporal lobe [32], but show widespread abnormalities that extend into the temporal pole, temporolimbic and frontocentral regions [33, 34], the cerebellum and the thalamus [35] and longitudinal increases in volume loss [36]. Neuronal network damage in TLE with hippocampal atrophy and in MRI-negative TLE has been reported to be more widespread in patients with a left-sided seizure focus [35]. This may be explained by more extensively connected temporofrontal networks in the dominant hemisphere, due to their involvement in language function with more intense seizure propagation in the left hemisphere re-

sulting in a prominent neuronal loss in LTLE [37]. Furthermore, an association between residual seizures and atrophy in temporopolar and insular cortices in TLE with hippocampal atrophy and in the posterior quadrant in MRI-negative TLE has been reported [38] .

Our group has recently examined the spatial relationship between widespread cortical atrophy and functionally connected networks linked to interictal epileptiform discharges, using simultaneous EEG-fMRI in a cohort of patients suffering from mTLE [39]. In EEG-fMRI, both modalities are recorded at the same time using MRI-compatible electrodes. After postprocessing, the time course of interictal epileptiform discharges found on the EEG trace can be used to indentify spatiotemporal correlates of the BOLD signal, i.e. regions of the brain whose hemodynamic response is closely coupled to the EEG-activity. It is thought that these areas represent the irritative zone and its associated network. In the aforementioned study, we detected hemodynamic correlates to interictal epileptiform discharges beyond the seizure onset zone in the ipsilateral insula, the temporal pole and temporo-lateral neocortex, in the cerebellum, along the central sulcus and bilaterally in the cingulate gyrus. Equally widespread reductions in grey matter volume were detected in the middle and inferior temporal gyrus, the uncus to the hippocampus, the insula, the posterior cingulate and the anterior lobe of the cerebellum. These findings were in line with the cortical thickness changes described above. Previous ictal connectivity studies in mTLE exhibited patterns of bilateral increases of cerebral blood flow in the temporal lobes (predominantly the middle and superior temporal gyrus including the temporal pole, the posterior temporal lobe and the cerebellum) and decrease cerebral blood flow in the inferior temporal gyrus, the inferior parietal lobe and posterior cingulated [40]. Of note, there is a tight spatial overlap between hemodynamic and atrophy effects along mesolimbic areas, but not in regions beyond the limbic network [15].

Clues from morphometric analyses and combined EEG/fMRI recordings implicate that the widespread structural damage linked to abnormal hemodynamic responses is suggestive of TLE being a system rather than a focal disorder leading to a disruption of structural networks. Both functional network analysis (derived from a temporal correlation of neurophysiologic signals in different brain regions) to illustrate brain dynamics on a system level and structural network analysis (using advanced neuroimaging techniques as diffusion tensor or diffusion spectrum imaging) provided further advances in knowledge about interregional network disruptions in mTLE [41]. While graph-theoretical analyses revealed a small-world organization of the cerebral cortex in healthy individuals [42], global network organization of patients revealed increased path length in TLE [41]. Several authors demonstrated altered connectivity in patients with mTLE. As a key finding, they reported increased connections within the mesial temporal lobe and decreased connectivity along extratemporal areas, including contralateral temporal regions [43 - 45]. Others suggested altered bitemporal connectivity patterns in patients with mTLE [46]. These findings suggest a deleterious impact of the epileptic lesion and the epileptogenic zone on the whole brain, potentially impacting multiple cerebral networks [47].

Network Relationships across Modalities

What is the relationship between the functional and structural changes reviewed above? A recent study by Voets et al. examined the association between resting-state functional networks, brain atrophy and changes in white matter microstructure in 35 patients with TLE [48]. Interestingly, Voets et al. reported reduced functional interactions between the hippocampus and anterior temporal and sensorimotor cortices that covaried with the extent of grey matter atrophy, i.e. reduced integration of the hippocampus with the rest of the network could be explained by the degree of grey matter volume reduction in the same areas. Of note, these areas parallel those that we found to correlate with IEDs in simultaneous EEG-fMRI. Additionally Voets et al. discovered that functional integration outside this network, e.g. between frontal and temporal areas, was dependent on white matter microstructure rather than grey matter atrophy.

Network Relationships across Modalities: Clinical Examples

We present two cases where we used visual and automated methods to identify the epiletogenic lesion, EEG-fMRI to map the interictal network, and functional connectivity to define the lesion-dependent network.

Case 1

We used surface based morphometry (SBM) with FreeSurfer [49, 50] as a tool for comparison of cortical properties like thickness, curvature and sulcal depth between subject groups. As mentioned above, in [51] it was shown that SBM may also be useful for quantitative assessment of cortical malformations in individual epilepsy patients during pre-surgical evaluation. Here we compared cortical thickness of our patient (female, 34 years) to a gender matched control group of 16 females (age 30 to 40 years, mean 33.4, standard error of the mean 0.9) who received T1 weighted imaging with the same MR sequence (MPRAGE, TE=2.2ms, TR=1950ms, TI=900ms). While on the left hemisphere no significant deviations from the control group were found, several regions survived false discovery rate (FDR) correction on level 0.05 in the right hemisphere

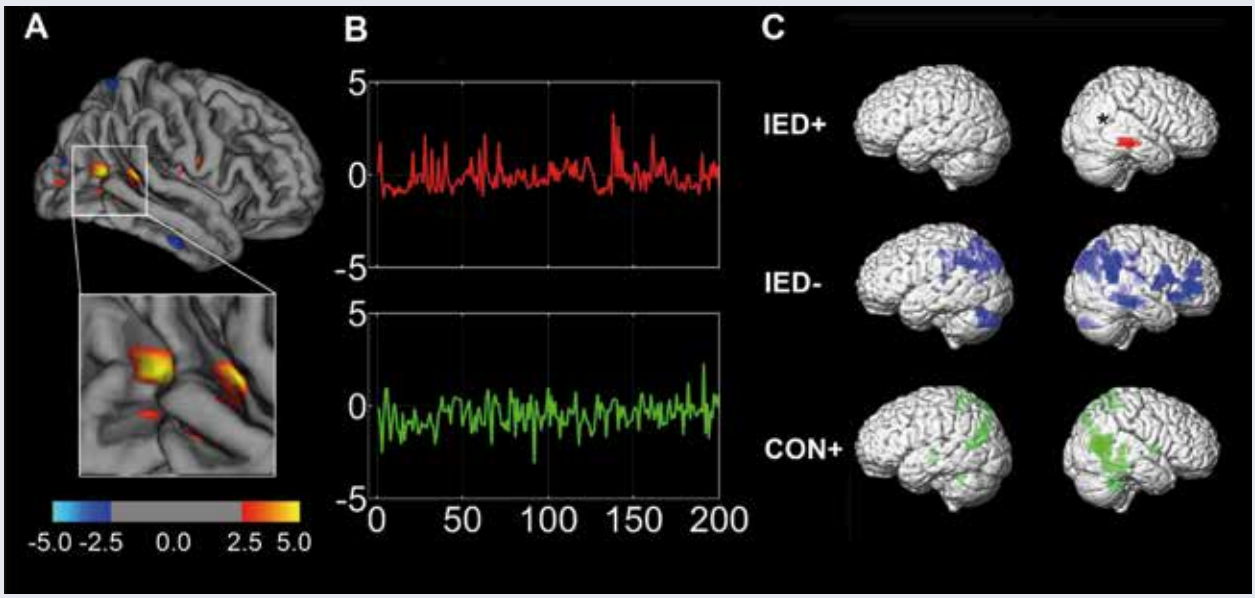

Figure 1. Patient example: lateral TLE.
A: Lesion in the right temporo-parietal cortex leads to extended deactivations of the default-mode network during interictal epileptiform discharges (IED), and shows pathological resting-state connectivity to the same areas. A: surface-based cortical thickness analysis (increase in hot colors, decrease in cool colors). Color bar represents z-scores compared to healthy controls. Insert shows a magnification of the largest cluster of cortical thickness increase in the right temporo-parietal junction, corresponding to an extended cortical heterotopia.
B: Upper row, (rectified) time course of IED, derived from a multivariate analysis of the EEG inside the scanner during simultaneous EEG-fMRI. Lower row, time course of BOLD-signal fluctuations from the same examination, extracted from the cortical thickness cluster seen in Panel A. Time courses are normalized to unit standard deviations of each time series (y-axis). For clarity, only the first 200 of 460 time points (scans) have been plotted (x-axis).
C: BOLD-correlation maps superimposed on 3D renderings of the patient's brain (peak threshold $p < .001$, uncorrected, extent threshold $p < .05$, FDR-corrected). Upper row: positive (IED+) correlation between BOLD-signal and IED time course in the lateral and inferior temporal gyrus on the right. Middle row: negative (IED-) correlations between BOLD-signal and IED time course in an extended network including (i) on the right the lateral and inferior temporal gyrus, the parietal operculum, the inferior frontal cortex (ii) on the left the anterior cerebellum, and (iii) bilaterally the precuneus and the inferior parietal cortex. Lower row: positive resting-state functional connectivity (CON+) between the cortical heterotopia and a network overlapping with IED- above, including (i) right inferior temporal cortex and (ii) bilateral inferior parietal cortex and precuneus. (*) indicates approximate center of mass from Panel A.

(**Figure 1**, Panel A). These included notably two large clusters of increased cortical thickness in the temporo-parietal junction and the middle temporal gyrus, corresponding to an extended cortical heterotopia, but also significant atrophy in the fusiform gyrus (not shown). It has recently been shown that these malformations might still be functionally connected to healthy cortex [52], which might have epileptogenic effects. We therefore calculated the functional connectivity using cross-correlations between the BOLD-signal from the heterotopic cortex (**Figure 1**, Panel B, lower row) and the rest of the brain. We found a bilateral functional network (**Figure 1**, Panel C, lower row) that included the inferior parietal cortex and the precuneus bilaterally, areas known to participate in the DMN. Interestingly, a broadly similar network was found to be anticorrelated with, or deflected during, IED (Panel C, middle row), which extended into right frontal areas and the contralateral anterior cerebellum. Note that this pattern of deactivation has already been shown in a group of TLE patients using cerebral blood flow measurements with SPECT [40], underscoring the validity of our single-subject results. Note also that the region that correlated positively with the IED time course (Panel C, upper row) was restricted to a localized region close to the heterotopia, in strong contrast to the network-wide, possibly pathological functional connectivity effects (Panel C, lower row). Due to the volume of heterotopic cortex, no surgery could be performed.

Case 2

This 21 years old female suffered from longstanding pharmacoresistant epilepsy (from 5 years of age) due to left MTS (**Figure 2**, Panel A). She underwent presurgical EEG-fMRI to identify BOLD-correlates linked to IED (**Figure 2**, Panel B, upper row) that could be found

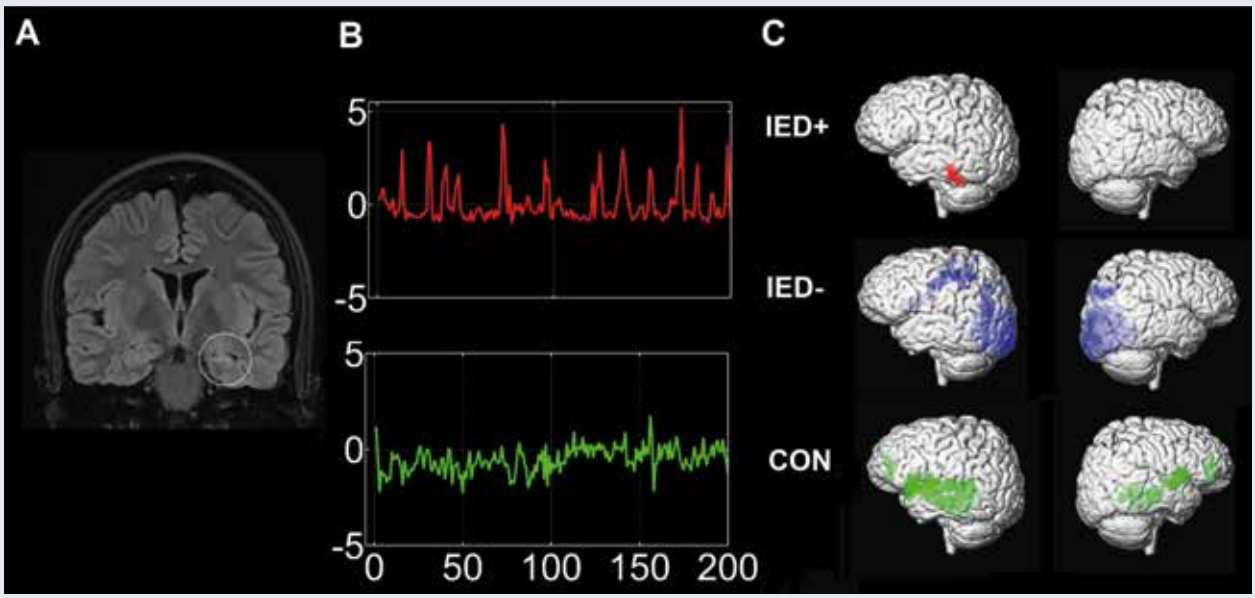

Figure 2. Patient example: mesial TLE with left hippocampal sclerosis.
A: Coronal section through a fluid-attenuated inversion recovery image shows left signal hyperintensity and volume loss of the hippocampal formation.
B: Upper row, (rectified) time course of IED from simultaneous EEG-fMRI, as in Figure 1. Lower row, time course of BOLD-signal fluctuations, extracted from a cytoarchitectonic probabilistic map of the left hippocampal CA1 region. Time courses are normalized and plotted as in Figure 1.
C: BOLD-correlation maps superimposed on 3D renderings of the patient's brain (peak threshold $p < .001$, uncorrected, extent threshold $p < .05$, FDR-corrected). Upper row, significantly positive (IED+) correlation between BOLD-signal and IED time course in left posterior parahippocampal gyrus (projects onto brain surface due to semitransparent plotting). Middle row: Significantly negative (IED-) correlations between BOLD-signal and IED time course in an extended network including (i) left postcentral gyrus (ii) bilateral cuneus, precuneus and inferior parietal cortex. Lower row: Positive resting-state functional connectivity (CON+) between left hippocampus and (i) left lateral temporal cortex, (ii) right hippocampus (iii) bilateral anterior cingulate cortex and insula.

in the depth of the left posterior temporal lobe (semi-transparent rendering in **Figure 2**, Panel C, upper row). Similarly to the 1st case, there was a widespread deactivation including the bilateral posterior parietal cortex, cuneus and precuneus and the left sensorimotor cortex. We used the BOLD-time series from the epileptogenic lesion to generate brain-wide maps of functional connectivity (**Figure 2**, Panel C) and detected a bilateral mesio-temporal connectivity network including bilaterally the hippocampus, insula, anterior cingulate and parietal operculum, and the lateral temporal cortex on the left (**Figure 2**, Panel C). In contrast to Case 1, there was no apparent overlap between IED- and functional connectivity networks. Of note, the left polar and lateral temporal regions visible on the functional connectivity map were included in the surgical resection. The patient has remained seizure-free (current follow-up 2.5 years).

Conclusions

An increasing body of literature – further illustrated by two clinical cases – indicates that epiletogenic lesions have widespread effects on the network structure of the brain. Here, we provided two examples of a network perspective on epilepsy that could further implicate clinical research and practice in future. One practical implication of the network concept is that it may radically alter our current classification of epilepsies [53]. Further, a concept of network organization along strategic nodes and connections may influence surgical planning. Several outcome studies indicated that seizure freedom can be attained in 60-70% of TLE patients with different resective approaches (anterior, medial or lateral temporal lobectomy and combinations thereof) [17, 54].

Despite the promises of a network-based perspective in epileptology, translation to the bedside remains challenging. From a methodological point of view, integrating multimodal data sets into a coherent analysis framework is a non-trivial problem, and will certainly necessitate advanced statistical modeling techniques. Much research is needed in this area. On the other

hand, there are practical questions for the daily clinical routine that need to be answered, before these methods can be brought to fruition. For instance, what is the sensitivity and specificity of neuroimaging techniques, alone or in combination [55]? How can results be reported in a rapid, easily understandable manner? What is the added value of multimodality neuroimaging and network analysis for patients and doctors; do they really inform clinical decision-making and improve treatment outcomes, or just add another layer of complexity to an already challenging situation? As we have shown with practical examples, methods are already in place to examine these questions and might help to advance epilepsy into a truly network-based medical discipline [53, 56, 57].

References

1. *Llinas RR. The contribution of Santiago Ramon y Cajal to functional neuroscience. Nat Rev Neurosci 2003; 4: 77-80*
2. *Alstott J, Breakspear M, Hagmann P et al. Modeling the impact of lesions in the human brain. PLoS Comput Biol 2009; 5: e1000408*
3. *Laufs H. Functional imaging of seizures and epilepsy: evolution from zones to networks. Curr Opin Neurol 2012; 25: 194-200*
4. *Komaba Y, Osono E, Kitamura S, Katayama Y. Crossed cerebellocerebral diaschisis in patients with cerebellar stroke. Acta Neurol Scand 2000; 101: 8-12*
5. *Lin DD, Kleinmann JT, Wityk RJ. Crossed cerebellar diaschisis in acute stroke detected by dynamic susceptibility contrast MR perfusion imaging. AJNR Am J Neuroradiol 2009; 30: 710-715*
6. *Srinivasan A, Miller W, Stys P, Goyal M et al. Crossed cerebellar diaschisis in stroke. Neurology 2004; 62: 2130*
7. *Rabinowicz AL, Salas E, Beserra F et al. Changes in regional cerebral blood flow beyond the temporal lobe in unilateral temporal lobe epilepsy. Epilepsia 1997; 38: 1011-1014*
8. *Cole AJ. Status epilepticus and periictal imaging. Epilepsia 2004; 45(Suppl 4): 72-77*
9. *Spencer SS. Neural networks in human epilepsy: evidence of and implications for treatment. Epilepsia 2002; 43: 219-227*
10. *Lopes da Silva F, Blanes W, Kalitzin SN et al. Epilepsies as dynamical diseases of brain systems: basic models of the transition between normal and epileptic activity. Epilepsia 2003; 44(Suppl 12): 72-83*
11. *Rummel C, Goodfellow M, Gast H et al. A systems-level approach to human epileptic seizures. Neuroinformatics 2013; 11: 159-173*
12. *Rosenow F, Luders H. Presurgical evaluation of epilepsy. Brain 2001; 124: 1683-1700*
13. *Ell PJ, Costa DC. Role of routine functional brain imaging in temporal lobe epilepsy. Lancet 1989; 1: 959*
14. *Wang A, Peters TM, de Ribaupierre S, Mirsattari SM. Functional magnetic resonance imaging for language mapping in temporal lobe epilepsy. Epilepsy Res Treat 2012; 2012: 198183*
15. *Bernasconi N, Bernasconi A, Caramanos Z et al. Mesial temporal damage in temporal lobe epilepsy: a volumetric MRI study of the hippocampus, amygdala and parahippocampal region. Brain 2003; 126: 462-469*
16. *Jackson GD, Berkovic SF, Duncan JS, Connelly A. Optimizing the diagnosis of hippocampal sclerosis using MR imaging. AJNR Am J Neuroradiol 1993; 14: 753-762*
17. *Engel J, Jr. Surgery for seizures. N Engl J Med 1996; 334: 647-652*
18. *Mueller CA, Scorzin J, von Lehe M et al. Seizure outcome 1 year after temporal lobe epilepsy: an analysis of MR volumetric and clinical parameters. Acta Neurochir (Wien), 2012; 154: 1327-1336*
19. *Jardim AP, Neves RS, Caboclo LO et al. Temporal lobe epilepsy with mesial temporal sclerosis: hippocampal neuronal loss as a predictor of surgical outcome. Arq Neuropsiquiatr 2012; 70: 319-324*
20. *Malmgren K, Thom M. Hippocampal sclerosis--origins and imaging. Epilepsia 2012; 53(Suppl 4): 19-33*
21. *Blümcke I, Thom M, Aronica E et al. The clinicopathologic spectrum of focal cortical dysplasias: a consensus classification proposed by an ad hoc Task Force of the ILAE Diagnostic Methods Commission. Epilepsia 2011; 52: 158-174*
22. *Duncan J. The current status of neuroimaging for epilepsy. Curr Opin Neurol 2009; 22: 179-184*
23. *Wagner J, Weber B, Urbach H et al. Morphometric MRI analysis improves detection of focal cortical dysplasia type II. Brain 2011; 134: 2844-2854*
24. *Focke NK, Symms MR, Burdett JL, Duncan JS. Voxel-based analysis of whole brain FLAIR at 3T detects focal cortical dysplasia. Epilepsia 2008; 49: 786-793*
25. *Duncan JS. Imaging in the surgical treatment of epilepsy. Nat Rev Neurol 2010; 6: 537-550*
26. *Wong BY, Prince DA. The lateral spread of ictal discharges in neocortical brain slices. Epilepsy Res 1990; 7: 29-39*
27. *Gale K. Subcortical structures and pathways involved in convulsive seizure generation. J Clin Neurophysiol 1992; 9: 264-277*
28. *Rafiq A, DeLorenzo RJ, Coulter DA. Generation and propagation of epileptiform discharges in a combined entorhinal cortex/hippocampal slice. J Neurophysiol 1993; 70: 1962-1974*
29. *Bear J, Fountain NB, Lothman EW. Responses of the superficial entorhinal cortex in vitro in slices from naive and chronically epileptic rats. J Neurophysiol 1996; 76: 2928-2940*
30. *Bertram EH. Functional anatomy of spontaneous seizures in a rat model of limbic epilepsy. Epilepsia 1997; 38: 95-105*
31. *Doucet G, Naveau M, Petit L et al. Brain activity at rest: a multiscale hierarchical functional organization. J Neurophysiol 2011; 105: 2753-2763*
32. *Salmenperä T, Kälviäinen R, Partanen K, Pitkänen A. Quantitative MRI volumetry of the entorhinal cortex in temporal lobe epilepsy. Seizure 2000; 9: 208-215*
33. *Keller SS, Roberts N. Voxel-based morphometry of temporal lobe epilepsy: an introduction and review of the literature. Epilepsia 2008; 49: 741-757*
34. *Bernhardt BC, Worsley KJ, Besson P et al. Mapping limbic network organization in temporal lobe epilepsy using morphometric correlations: insights on the relation between mesiotemporal connectivity and cortical atrophy. Neuroimage 2008; 42: 515-524*
35. *Riederer F, Lanzenberger R, Kaya M et al. Network atrophy in temporal lobe epilepsy: a voxel-based morphometry study. Neurology 2008; 71: 419-425*
36. *Cascino GD. Temporal lobe epilepsy is a progressive neurologic disorder: Time means neurons! Neurology 2009; 72: 1718-1719*
37. *Powell HW, Parker GJ, Alexander DC et al. Hemispheric asymmetries in language-related pathways: a combined functional MRI and tractography study. Neuroimage 2006; 32: 388-399*
38. *Bernhardt BC, Bernasconi N, Concha L, Bernasconi A. Cortical thickness analysis in temporal lobe epilepsy: reproducibility and relation to outcome. Neurology 2010; 74: 1776-1784*

39. Wiest R, Estermann L, Scheidegger O et al. Widespread grey matter changes and hemodynamic correlates to interictal epileptiform discharges in pharmacoresistant mesial temporal epilepsy. J Neurol 2013; ss: www-ddd
40. Weder BJ, Schindler K, Loher TJ et al. Brain areas involved in medial temporal lobe seizures: a principal component analysis of ictal SPECT data. Hum Brain Mapp 2006; 27: 520-534
41. Bernhardt BC, Chen Z, He Y et al. Graph-theoretical analysis reveals disrupted small-world organization of cortical thickness correlation networks in temporal lobe epilepsy. Cereb Cortex 2011; 21: 2147-2157
42. Van den Heuvel MP, Stam CJ, Boersma M, Hulshoff Pol HE. Small-world and scale-free organization of voxel-based resting-state functional connectivity in the human brain. Neuroimage 2008; 43: 528-539
43. Liao W, Zhang Z, Pan Z et al. Altered functional connectivity and small-world in mesial temporal lobe epilepsy. PLoS One 2010; 5: e8525
44. Seidenberg M, Kelly KG, Parrish J et al. Ipsilateral and contralateral MRI volumetric abnormalities in chronic unilateral temporal lobe epilepsy and their clinical correlates. Epilepsia 2005; 46: 420-430
45. Bettus G, Guedj E, Joyeux F et al. Decreased basal fMRI functional connectivity in epileptogenic networks and contralateral compensatory mechanisms. Hum Brain Mapp 2009; 30: 1580-1591
46. Morgan VL, Rogers BP, Sonmezturk HH et al. Cross hippocampal influence in mesial temporal lobe epilepsy measured with high temporal resolution functional magnetic resonance imaging. Epilepsia 2011; 52: 1741-1749
47. Tracy J, Osipowicz K, Spechler Pet al. Functional connectivity evidence of cortico-cortico inhibition in temporal lobe epilepsy. Hum Brain Mapp 2012; Sept 15: Epub ahead of print
48. Voets NL, Beckmann CF, Cole DM et al. Structural substrates for resting network disruption in temporal lobe epilepsy. Brain 2012; 135: 2350-2357
49. Dale AM, Fischl B, Sereno MI. Cortical surface-based analysis. I. Segmentation and surface reconstruction. Neuroimage 1999; 9: 179-194
50. Fischl B, Sereno MI, Dale AM. Cortical surface-based analysis. II: Inflation, flattening, and a surface-based coordinate system. Neuroimage 1999; 9: 195-207
51. Thesen T, Quinn BT, Carlson C et al. Detection of epileptogenic cortical malformations with surface-based MRI morphometry. PLoS One 2011; 6: e16430
52. Christodoulou JA, Walker LM, Del Tufo SN et al. Abnormal structural and functional brain connectivity in gray matter heterotopia. Epilepsia 2012; 53: 1024-1032
53. Richardson MP. Large scale brain models of epilepsy: dynamics meets connectomics. J Neurol Neurosurg Psychiatry 2012; 83: 1238-1248
54. Bell ML, Rao S, So EL et al. Epilepsy surgery outcomes in temporal lobe epilepsy with a normal MRI. Epilepsia 2009; 50: 2053-2060
55. Hauf M, Jann K, Schindler K et al. Localizing seizure-onset zones in presurgical evaluation of drug-resistant epilepsy by electroencephalography/fMRI: effectiveness of alternative thresholding strategies. AJNR Am J Neuroradiol 2012; 33: 1818-1824
56. Barabasi AL, Gulbahce N, Loscalzo J. Network medicine: a network-based approach to human disease. Nat Rev Genet 2011; 12: 56-68
57. Engel J Jr, Thompson PM, Stern JM et al. Connectomics and epilepsy. Curr Opin Neurol 2013; 26: 186-194

Address for correspondence:
Prof. Dr. med. Roland Wiest
Support Center for Advanced Neuroimaging (SCAN)
Institute of Diagnostic and Interventional Neuroradiology
Inselspital, Freiburgstrasse
CH 3010 Bern
Tel. 0041 31 6322655
Fax 0041 31 6324872
roland.wiest@insel.ch