

Proximity of Premolar Roots to Maxillary Sinus: A Radiographic Survey Using Cone-beam Computed Tomography

Thomas von Arx, DMD, Ivo Fodich, DDS, and Michael M. Bornstein, DMD

Abstract

Introduction: The proximity of the roots of the posterior maxillary teeth to the maxillary sinus is a constant challenge to the dental practitioner. Because the majority of studies have assessed the relationship regarding molars, the present study focused on premolars. **Methods:** Cone-beam computed tomographic images of 192 patients were reconstructed in sagittal, coronal, and axial planes to quantify the distances between the root apices of the maxillary premolars and the adjacent maxillary sinus. Measurements were taken for each root, and data were correlated with age, sex, side, and presence of both or absence of 1 of the 2 premolars. **Results:** A total of 296 teeth (177 first and 119 second premolars) were evaluated. The mean distances from buccal roots of the first premolars to the border of the maxillary sinus in the sagittal, coronal, and axial planes ranged from 5.15 ± 2.99 to 8.28 ± 6.27 mm. From palatal roots, the mean distances ranged from 4.20 ± 3.69 to 7.17 ± 6.14 mm. The mean distances of second premolars were markedly shorter in buccal roots between 2.32 ± 2.19 and 3.28 ± 3.17 mm and in palatal roots between 2.68 ± 3.58 and 3.80 ± 3.71 mm, respectively. The frequency of a premolar root protrusion into the maxillary sinus was very low in first premolars (0%–7.2%) but higher in second premolars (2.5%–13.6%). Sex, age, side, and presence/absence of premolars failed to significantly influence the mean distances between premolar roots and the maxillary sinus. **Conclusions:** Based on the calculated mean distances of the present study, only few premolars (and if so second premolars) would present a risk of violating the border of the maxillary sinus during conventional or surgical endodontic treatment or in case of tooth extraction. (*J Endod* 2014;40:1541–1548)

Key Words

Cone-beam computed tomography, maxillary premolar, maxillary sinus

From the Department of Oral Surgery and Stomatology, School of Dental Medicine, University of Bern, Bern, Switzerland.

Address requests for reprints to Prof Thomas von Arx, Department of Oral Surgery and Stomatology, School of Dental Medicine, University of Bern, Freiburgstrasse 7, CH-3010 Bern, Switzerland. E-mail address: thomas.vonarx@zmk.unibe.ch 0099-2399/\$ - see front matter

Copyright © 2014 American Association of Endodontists. <http://dx.doi.org/10.1016/j.joen.2014.06.022>

The anatomic relationship between the teeth and the maxillary sinus has been a constant challenge in dentistry, in particular for nonsurgical and surgical endodontics as well as for extraction or surgical removal of posterior maxillary teeth (1–3). Furthermore, periradicular and periodontal pathoses originating from posterior maxillary teeth may spread into the maxillary sinus (4–8).

A very small maxillary sinus is present at birth, but it gradually increases in volume in adolescents and young adults. At about the age of 12 years, the sinus floor is level with the nasal floor. Around the age of 20 years, the floor of the maxillary sinus is situated 5 mm inferior to the nasal floor (9). A computed tomographic (CT) study reported that the growth of the maxillary sinus continues until the third decade in males and the second decade in females (10). Often, the floor of the maxillary sinus expands (sinus recesses) between the roots of the posterior teeth, resulting in a close proximity of roots and sinus. Radiographically, the roots may appear to penetrate the floor of the maxillary sinus and protrude into the antrum, but, in fact, it is the maxillary sinus that has extended around the roots (pneumatization of alveolar process).

In general, panoramic radiography is an unreliable method for determination of the topographic relationship between posterior teeth and the maxillary sinus (3, 11). Therefore, recent studies have focused on using CT (4, 12, 13) or cone-beam computed tomographic (CBCT) imaging (14–18) for assessing the proximity between the roots and the sinus floor.

Some of the studies mentioned previously have limited their research to molars (4, 14, 17). Therefore, the primary objective of the present study was to perform a detailed analysis of the radiographic relationship between the apices of maxillary premolars and the floor of the maxillary sinus using CBCT imaging. The secondary objective was to correlate the data with age, sex, side of evaluation, and status of premolars.

Materials and Methods

CBCT images of the maxilla taken in our department from October 2012 to July 2013 were retrospectively evaluated. Because of the retrospective nature of the evaluation, the study was exempt from formal approval by the institutional review board. Because the present study focused on the relationship between premolars and the maxillary sinus, only cases showing the area of the maxillary premolars (region of interest [ROI]) were included in this survey. Cases presenting with the following findings were excluded from further analysis:

1. Premolars showing periapical or periradicular lesions
2. Status after sinus floor elevation
3. Foreign material in the ROI
4. Images with artifacts such as motion, beam hardening or scatter

A total of 202 CBCT images taken in 192 patients fulfilled the inclusion criteria. The CBCT images were obtained with a 3D Accuitomo XYZ Slice View Tomograph (Morita, Kyoto, Japan) with fields of view (FOVs) varying between 16 cm^2 ($4 \times 4 \text{ cm}$) and 140 cm^2 ($10 \times 14 \text{ cm}$), and basic voxel sizes varying between 0.08 mm and 0.25 mm. Operating parameters were set at 5.0 mA and 90 kV and exposure times of 10.5 (high-speed modus) or 17.5 seconds (standard modus). For all CBCT images, the FOV was selected according to the clinical situation and the planned therapy; the FOVs were grouped into small ($<40 \text{ cm}^2$), medium ($40\text{--}100 \text{ cm}^2$), and large/

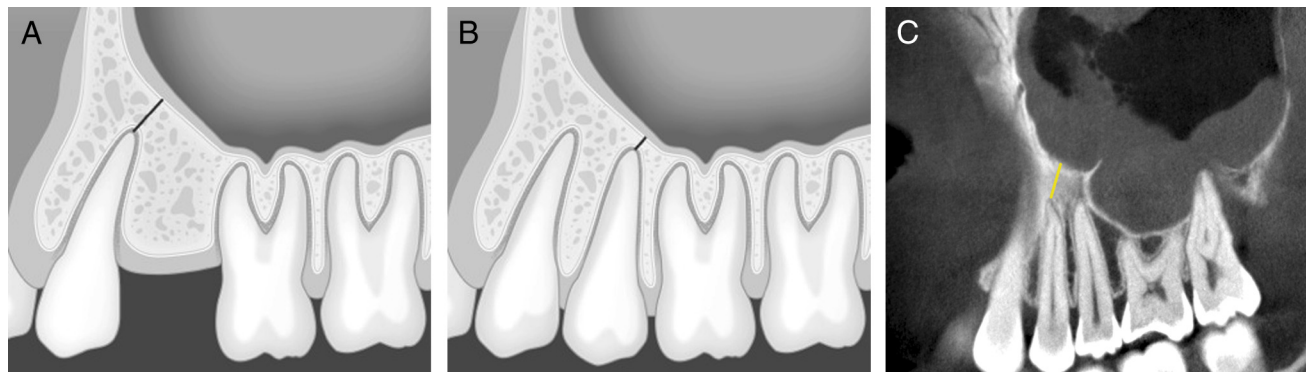


Figure 1. (A) A schematic illustration of the measurement of the shortest distance from the first premolar to the floor of the maxillary sinus (sagittal plane). (B) A schematic illustration of the measurement of the shortest distance from the second premolar to the floor of the maxillary sinus (sagittal plane). (C) A sagittal CBCT view showing the shortest distance from the first premolar to the floor of the maxillary sinus.

maxillofacial (>100 cm²). The data were reconstructed with slices at an interval of 0.5 mm, which were positioned parallel to the horizontal plane of the posterior maxillary alveolar crest. Subsequently, the roots of the premolars were identified, and for each root, the sagittal, coronal, and axial planes for measurements were determined as follows:

1. *Sagittal image:* Through the central long axis of the root (anteroposterior orientation)
2. *Coronal image:* Through the central long axis of the root (mediolateral orientation)
3. *Axial image:* Through the apex of the root (horizontal orientation)

The CBCT images were evaluated on a Dell 380 Precision workstation (Dell SA, Geneva, Switzerland) and a 19-inch Eizo Flexscan monitor with a resolution of 1280 × 1024 pixels (Eizo Nanao AG, Wädenswil, Switzerland). The following analyses and measurements (primary objectives) were performed using specialized computer software (i-Dixel, Version 2.0.4, Morita):

1. Shortest vertical/oblique distance from the root apex of any buccal, palatal, or accessory root of first and second premolars to the closest

border of the maxillary sinus (sagittal views [Fig. 1A–C] and coronal views [Fig. 2A–C]) (negative value if the root tip was located above the floor of the maxillary sinus)

2. Shortest horizontal distance from the root apex of any buccal, palatal, or accessory root of first and second premolars to the closest border of the maxillary sinus (axial view [Fig. 3A–C]) (negative value if the root tip was located inside the border of the maxillary sinus)

In addition, the sex and age of each patient were recorded as well as the side of evaluation and the presence/absence of 1 of the 2 premolars to correlate these data with the obtained radiographic measurements (secondary objectives).

Statistics

All data were first analyzed descriptively. To detect significant differences between distances of the buccal versus palatal premolar apices to the border of the maxillary sinus for sagittal, coronal, and axial CBCT scans, nonparametric longitudinal analysis of variance analyses were used. To detect significant differences between the distances of the

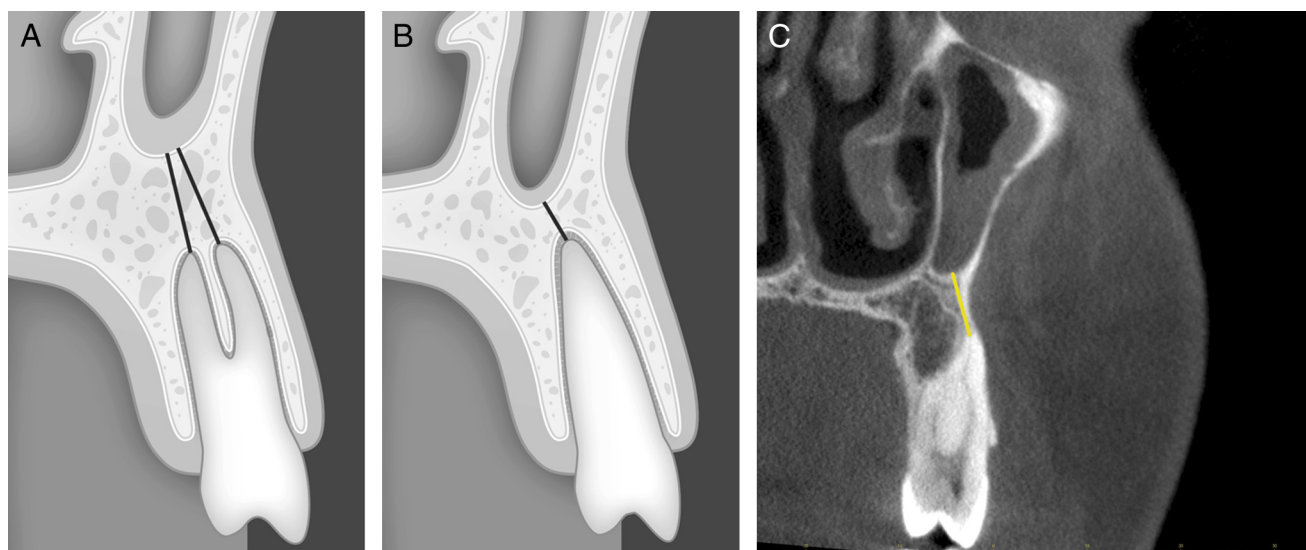


Figure 2. (A) A schematic illustration of the measurement of the shortest distance from both roots of the first premolar to the floor of maxillary sinus (coronal plane). (B) A schematic illustration of the measurement of the shortest distance from the second premolar to the floor of the maxillary sinus (coronal plane). (C) A coronal CBCT view showing the shortest distance from the first premolar to the floor of the maxillary sinus.

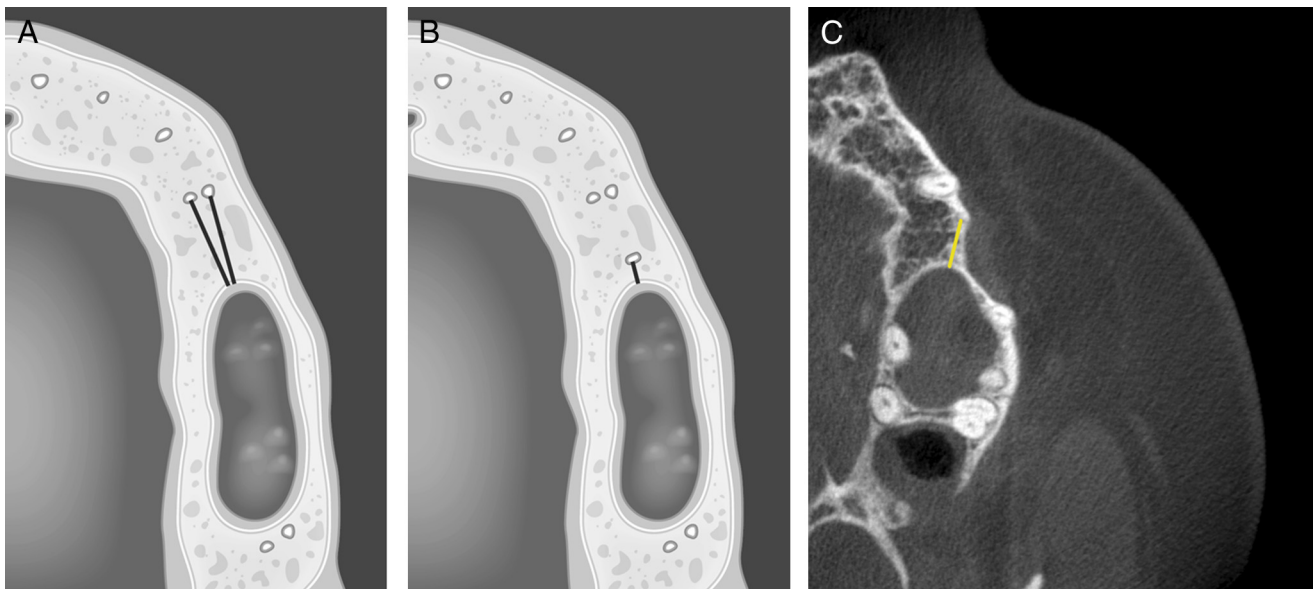


Figure 3. (A) A schematic illustration of the measurement of the shortest distance from both roots of the first premolar to the floor of the maxillary sinus (axial plane). (B) A schematic illustration of the measurement of the shortest distance from the second premolar to the floor of the maxillary sinus (axial plane). (C) An axial CBCT view showing the shortest distance from the first premolar to the floor of the maxillary sinus.

premolar apices (pooled data sets) to the border of the maxillary sinus and sex, age, side of evaluation, and presence/absence of 1 of the 2 premolars, nonparametric analysis of variance analysis was performed for longitudinal data according to the method described by Brunner et al (19). For the statistical analysis of the frequency of root positions relative to the sinus, Fisher exact tests were used. The analyses were explorative in nature; thus, no correction for multiple testing was applied. For the statistical analysis, the Internet-based R software package (R 2.15.1; <http://www.r-project.org>; The R Foundation for Statistical Computing, Vienna, Austria) was used. Furthermore, the extension packages exactRankTests and nparLD were used.

Results

A total of 296 premolars were assessed in 192 patients (males: 42.7%, females: 57.3%) who had a mean age of 58.4 ± 20.5 years (range, 19–81 years). The evaluation per situations ($n = 202$) showed that both premolars were present (46.5%), only the first premolar was present (41.1%), or only the second premolar was present (12.4%) (Table 1). Among the evaluated premolars, 59.8% were first premolars, and 40.2% were second premolars (Table 2). A total of 407 roots were observed with 405 analyzed roots. The most frequently assessed roots were buccal roots of first premolars (43.5%). Two first premolars each presented an accessory buccal root (Table 3), which were excluded in the present analysis.

Primary Objectives

In the sagittal plane, the mean distances from the buccal and palatal roots of the first premolars to the floor of the maxillary sinus were

TABLE 1. Distribution of Evaluated Situations ($n = 202$)

	Right side	Left side	Total (%)
Only first premolar present	40	43	83 (41.1)
Only second premolar present	11	14	25 (12.4)
Both premolars present	44	50	94 (46.5)
Total	95	107	202 (100)

5.15 ± 2.99 mm and 4.20 ± 3.69 mm, respectively (Tables 4–6). The palatal roots were about 1 mm closer to the maxillary sinus floor than the buccal roots, which was statistically significant ($P = .002$). The values for the second premolars were 2.32 ± 2.19 mm and 2.68 ± 3.58 mm, respectively ($P = .86$). In the coronal plane, the mean distances from the buccal and palatal roots of the first premolars to the floor of the maxillary sinus were 8.28 ± 6.27 mm and 7.17 ± 6.14 mm, respectively. The palatal roots were again about 1 mm closer to the maxillary sinus floor than the buccal roots ($P = .08$). The values for the second premolars were 3.28 ± 3.17 mm and 3.69 ± 4.51 mm, respectively ($P = .89$). In the axial plane, the mean distances from the buccal and palatal roots of the first premolars to the floor of the maxillary sinus were 5.86 ± 3.54 mm and 5.71 ± 3.89 mm, respectively ($P = .86$). The values for the second premolars were 2.40 ± 2.71 mm and 3.80 ± 3.71 mm, respectively ($P = .07$).

Secondary Objectives

In males, premolar roots were on average situated closer to the maxillary sinus than in females irrespective of the assessed root and the CBCT plane but without reaching statistical significance ($P = .19$ for sagittal values; $P = .32$ for coronal values; $P = .11$ for axial values) (Tables 7 and 8). Regarding age, no consistent pattern was observed for the minimum distances between root apices and the border of the maxillary sinus comparing the mean values of the different age groups ($P = .11$ for sagittal values, $P = .24$ for coronal values, and $P = .10$ for axial values). With respect to the side analysis, mean distances on the patient’s right side tended to be greater in the sagittal plane but shorter in the other planes compared with the left

TABLE 2. Distribution of Evaluated Premolars ($n = 296$)

	Right side	Left side	Total (%)
First premolars	84	93	177 (59.8)
Second premolars	55	64	119 (40.2)
Total	139	157	296 (100)

TABLE 3. Distribution of Evaluated Roots (*n* = 407)

	Right side	Left side	Total (%)
First premolar			
Buccal root	84	93	177 (43.5)
Palatal root	41	43	84 (20.6)
Accessory root	1	1	2 (0.5)
Second premolar			
Buccal root	55	64	119 (29.2)
Palatal root	16	9	25 (6.1)
Accessory root	—	—	—
Total	197	210	407(100%)

side. Yet, the differences were not statistically significant (*P* = .68 for sagittal values, *P* = .17 for coronal values, and *P* = .63 for axial values). Concerning the presence or absence of premolars, the mean distances tended to be greater if both premolars were present but without reaching statistical significance (*P* = .20 for sagittal values, *P* = .86 for coronal values, and *P* = .57 for axial values). Descriptively, the following constant findings were observed: when the second premolar was missing, the mean distances between root apices of first premolars and the sinus floor were always shorter (irrespective of the CBCT plane) compared with the situation with both premolars present (differences of means ranged between 0.49 and 1.0 mm). In contrast, when the first premolar was missing, the mean distances between the root apices of second premolars and the sinus floor were always greater (irrespective of the CBCT plane) compared with the situation with both premolars present (differences of means ranged between 1.24 and 1.68 mm).

Frequency Analysis

The majority of first premolar buccal apices (97.7%–99.3%) and palatal apices (92.2%–92.9%) were located outside of the confines of the maxillary sinus (Tables 9 and 10). The corresponding percentages were lower in second premolars (89%–94.1% for buccal apices and 76.0%–86.4% for palatal apices, respectively). Significant differences were found comparing the location of palatal versus buccal roots of the first premolars relative to the sinus border in coronal (*P* = .03) and axial planes (*P* = .01) but not in sagittal planes (*P* = .08). For the second premolars, the location of palatal versus buccal roots of the first premolars relative to the sinus border was significantly different for sagittal (*P* = .02) and coronal planes (*P* = .02) but not for axial planes (*P* = .72). When comparing the first with the second premolars, the location of buccal roots exhibited statistically significant differences only in axial planes (*P* = .003) but not in sagittal (*P* = .07) and coronal planes (*P* = .08). For palatal roots, only sagittal planes were significantly different (*P* = .03), but neither coronal (*P* = .12) nor axial planes (*P* = .39).

TABLE 4. Measurements of Distances (mm) between the Apices of Premolar Roots and the Maxillary Sinus in the Sagittal Plane (*n* = 405)

	Right side				Left side				All			
	<i>N</i>	Mean ± SD	Min	Max	<i>N</i>	Mean ± SD	Min	Max	<i>N</i>	Mean ± SD	Min	Max
First premolar												
Buccal root	84	5.32 ± 3.27	−1.32	17.16	93	4.99 ± 2.72	−1.51	11.10	177	5.15* ± 2.99	−1.51	17.16
Palatal root	41	4.19 ± 3.74	−0.92	13.96	43	4.21 ± 3.68	−2.11	15.37	84	4.20* ± 3.69	−2.11	15.37
Second premolar												
Buccal root	55	2.46 ± 2.12	−1.38	8.61	64	2.20 ± 2.26	−1.85	11.87	119	2.32 ± 2.19	−1.85	11.87
Palatal root	16	1.24 ± 2.99	−4.71	5.21	9	4.13 ± 3.97	0	12.59	25	2.68 ± 3.58	−4.71	12.59

SD, standard deviation.

**P* = .002.

Discussion

The present radiographic study aimed at measuring the distances between the root apices of maxillary premolars and the floor of the maxillary sinus using reformatted CBCT images. Premolars have traditionally not attracted the same attention compared with molars regarding their proximity to the floor of the sinus. That may be explained by the fact that teeth most frequently associated with oroantral communication in exodontia are first or second molars (1, 20). However, several studies have documented the mesial extension of the maxillary sinus above or even beyond the first premolar, highlighting the possibility of a close relationship also between premolars and the floor of the antrum (21, 22). Kim et al (21) assessed the mesial extension of the maxillary sinus in 33 hemisectioned cadaver heads using CT reformatted panoramic views of 24 sides. In 58% of specimens, the anterior limit of the maxillary sinus was located in the first premolar area, in 33% in the canine area, and in 8% in the second premolar area. Kopecka et al (22) evaluated 583 panoramic radiographs of edentulous maxillae. In 14 cases (2.4%), the anterior border of the maxillary sinus was above the canine, in 565 cases (96.9%) it was above the first premolar, and in the remaining 4 cases (0.7%) it was above the second premolar.

Analyzing the data regarding measurements between the premolar roots and the floor of the maxillary sinus floor, the following statements can be made:

1. The mean distances of first premolars were always greater than those of second premolars irrespective of the root, side, or plane (except the comparison of palatal roots in the axial plane on the left side, but *n* = 7 was low). The greatest difference of any data set amounted to 5.60 mm comparing buccal roots of the first and second left premolars in the coronal plane (8.57 mm vs 2.97 mm).
2. In the first premolars, palatal roots were always located closer to the sinus than buccal roots in any plane. In second premolars, the same finding was observed on the right sides, but on the left sides the palatal roots were located further away from the sinus than the buccal roots. This might be explained by the fact that some of the palatal roots of the left second premolars were very short.
3. Measurements obtained in the coronal planes were always greater than those in the sagittal planes for all roots and sides. This is explained by the fact that usually the most inferior point of the maxillary sinus is located in the first molar area with the sinus floor gradually ascending anteriorly over the premolars. Thus, the shortest distance from the apex to the sinus on the sagittal image was mostly taken in an oblique direction, but the corresponding coronal section was perpendicular relative to the sagittal section, explaining the higher values of measurements obtained with coronal images.
4. The same observation was made comparing axial and sagittal measurements with higher values in the axial plane (except for the left

TABLE 5. Measurements of Distances (mm) between the Apices of Premolar Roots and the Maxillary Sinus in the Coronal Plane ($n = 346$)

	Right side				Left side				All			
	N	Mean ± SD	Min	Max	N	Mean ± SD	Min	Max	N	Mean ± SD	Min	Max
First premolar												
Buccal root	67	7.94 ± 6.26	0	26.15	74	8.57 ± 6.3	0	21.93	141	8.28 ± 6.27	0	26.15
Palatal root	33	6.84 ± 6.08	-0.74	24.74	31	7.51 ± 6.38	0.92	21.88	64	7.17 ± 6.14	-0.74	24.74
Second premolar												
Buccal root	55	3.63 ± 3.70	0.49	16.09	63	2.97 ± 2.77	-1.35	13.93	118	3.28 ± 3.17	-1.35	16.09
Palatal root	15	3.03 ± 4.74	-3.03	14.48	8	4.94 ± 4.26	0.81	13.25	23	3.69 ± 4.51	-3.03	14.48

SD, standard deviation.

TABLE 6. Measurements of Distances (mm) between the Premolar Roots and the Maxillary Sinus in the Axial Plane ($n = 330$)

	Right side				Left side				All			
	N	Mean ± SD	Min	Max	N	Mean ± SD	Min	Max	N	Mean ± SD	Min	Max
First premolar												
Buccal root	67	5.85 ± 3.51	-0.87	15.77	81	5.86 ± 3.47	0.68	17.39	148	5.86 ± 3.54	-0.87	17.39
Palatal root	33	5.69 ± 3.96	-0.68	14.49	36	5.72 ± 3.89	-1.49	17.42	69	5.71 ± 3.89	-1.49	17.42
Second premolar												
Buccal root	40	2.87 ± 2.75	-1.27	14.01	51	2.12 ± 2.71	-1.21	16.38	91	2.40 ± 2.71	-1.27	16.38
Palatal root	15	2.84 ± 3.71	-1.68	8.17	7	5.74 ± 3.98	2.03	14.54	22	3.80 ± 3.71	-1.68	14.54

SD, standard deviation.

TABLE 7. Measurements of Distances (mm) in the First Premolars with Respect to the Secondary Study Parameters

	Sagittal plane				Coronal plane				Axial plane			
	N	Mean ± SD	Min	Max	N	Mean ± SD	Min	Max	N	Mean ± SD	Min	Max
Sex												
Male	74	4.29 ± 2.76	-1.32	11.91	63	7.70 ± 6.55	0	23.90	66	5.36 ± 3.55	-0.87	15.77
Female	103	5.10 ± 3.15	-1.81	15.56	79	8.53 ± 6.27	0.18	26.15	83	5.98 ± 3.54	0.1	17.40
Age												
≤20 y	1	1.54	1.54	1.54	1	0.74	0.74	0.74	1	2.02	2.02	2.02
21-40 y	17	5.27 ± 3.97	0.13	15.56	13	9.05 ± 5.21	0.40	19.2	14	5.12 ± 3.47	0.88	12.38
41-60 y	78	4.31 ± 2.8	-1.81	10.62	70	8.36 ± 6.52	0	23.99	65	5.41 ± 3.43	-0.87	15.77
>60 y	81	5.15 ± 2.94	0	11.91	58	7.85 ± 6.40	0	26.15	69	6.15 ± 3.63	0.13	17.40
Side												
Right	84	4.86 ± 3.00	-1.32	15.56	67	7.72 ± 6.34	0	26.15	68	5.67 ± 3.58	-0.87	15.77
Left	93	4.67 ± 3.01	-1.81	12.01	75	8.52 ± 6.39	0	21.90	81	5.73 ± 3.53	0.1	17.40
Presence/absence of premolars												
Both premolars present	94	5.07 ± 3.00	0	15.56	73	8.74 ± 6.34	0	23.99	79	5.93 ± 3.54	0.13	17.40
Second premolar missing	83	4.42 ± 2.99	-1.81	11.91	69	7.54 ± 6.3	0	26.15	70	5.44 ± 3.47	-0.87	15.77

SD, standard deviation.

buccal roots of the second premolars), showing that the maxillary sinus is closer to the premolar apices in the vertical than in the horizontal dimension.

- Comparing coronal and axial measurements, coronal values were always higher than axial values except for the left and overall palatal roots of the second premolars, reflecting the fact that the maxillary sinus moves away from the root apices (pyramidal shape of maxillary sinus with its base medially [lateral wall of nasal cavity] and its apex laterally [zygomatic bone]).

Previous radiographic studies providing data about the position of posterior roots relative to the floor of the maxillary sinus have used panoramic radiographs (16), CT scans (4, 12, 13), or CBCT imaging (14-18) (Table 11). However, the reliability of panoramic radiography in the prediction of root position/root projection of posterior maxillary teeth with respect to the maxillary sinus has been shown to be doubtful

(3, 11). Sharan and Madjar (11) compared paired panoramic radiographs and CT scans of 80 subjects regarding the concordance of root position (second premolars and first and second molars) relative to the sinus floor. Only 39% of the roots that projected on the sinus cavity in panoramic radiographs also showed protrusion into the sinus with CT imaging. (For second premolars, the rate was 33.3%.) The mean projection length in the panoramic radiographs was 3.1 ± 2.54 mm compared with 1.5 ± 1.50 mm in CT scans ($P < .001$).

Of the summarized studies in Table 11, only few investigations have provided metric measurements for premolar distances to be compared with the data of the present study. In fact, only 2 studies used a similar methodology (CBCT imaging) to measure the distances between premolar roots and the sinus floor (15, 16). Kilic et al (15) used coronal CBCT planes and reported a mean distance of 8.42 mm (right side) and 6.58 mm (left side) for first premolars and 3.75 mm (right side) and 3.73 mm (left side) for second premolars. However, as shown

TABLE 8. Measurements of Distances (mm) in the Second Premolars with Respect to the Secondary Study Parameters

	Sagittal plane				Coronal plane				Axial plane			
	N	Mean ± SD	Min	Max	N	Mean ± SD	Min	Max	N	Mean ± SD	Min	Max
Sex												
Male	53	2.1 ± 2.18	-2.13	12.23	52	2.98 ± 3.20	-1.35	16.09	44	2.12 ± 2.64	-1.21	15.46
Female	66	2.32 ± 2.19	-1.86	8.61	66	3.51 ± 3.20	-1.21	14.12	47	2.64 ± 2.66	-1.25	14.01
Age												
≤20 y	—	—	—	—	—	—	—	—	—	—	—	—
21–40 y	13	1.82 ± 2.46	-2.13	8.61	13	3.75 ± 4.10	0.65	14.12	9	1.39 ± 1.68	-0.95	5.42
41–60 y	59	2.0 ± 2.00	-1.86	7.42	59	2.72 ± 2.81	-1.35	16.09	46	2.05 ± 1.95	-1.25	8.59
>60 y	47	2.58 ± 2.27	-1.85	12.23	46	3.86 ± 3.24	0	13.59	36	3.07 ± 3.35	-0.84	15.46
Side												
Right	55	2.33 ± 2.20	-2.13	8.61	55	3.72 ± 3.22	-1.21	16.09	40	2.76 ± 2.69	-1.25	14.01
Left	64	2.14 ± 2.19	-1.85	12.23	63	2.90 ± 3.21	1.35	13.59	51	2.10 ± 2.65	-1.21	15.46
Presence/absence of premolars												
Both premolars present	94	1.90 ± 2.19	-2.13	8.61	94	2.94 ± 3.21	1.35	16.09	75	2.17 ± 2.65	-1.25	15.46
First premolar missing	25	3.45 ± 2.22	1.15	12.23	24	4.62 ± 3.36	0.46	13.59	16	3.41 ± 2.78	-0.87	8.74

SD, standard deviation.

in the present study, the use of only coronal measurements may provide overestimated distances and not the true shortest distance between the root apex and sinus floor. Georgescu et al (16) only included premolars with fused roots and measured the distances on reformatted panoramic and cross-sectional CBCT images. The mean distances between first premolars and the sinus floor amounted to 6.35 mm (panoramic view) and 7.56 mm (cross section), and between the second premolars and the sinus floor, it was 4.5 mm (panoramic view) and 4.64 mm (cross-section), respectively. These data also confirm the higher values obtained in coronal (cross-section) compared with sagittal (panoramic) planes.

Metric measurements between maxillary roots and adjacent anatomic structures obtained with CBCT imaging are considered accurate. Howe (14) assessed the concordance of CBCT and gross dissection measurements for dimensions of maxillary bone in 69 maxillary first molars of 37 cadaver specimens. The data sets displayed a Pearson correlation coefficient of $r = 0.85$ with a positive bias for CBCT imaging of 0.4 mm.

Regarding the frequency of a premolar root protruding into the maxillary sinus, Sharan and Madjar (11) reported such a finding in 8.3% of second premolars for coronal CT scans. (The first premolars

were not evaluated.) Much lower figures were reported for root protrusions of first (0%) and second premolars (0.9%) in a CBCT study of 50 patients (18). In the present study, the first premolar roots protruded into the sinus cavity in 0%–0.6% of buccal roots and in 0%–3.1% of palatal roots depending on the reformatted CBCT plane. Root protrusions of second premolars were observed more frequently with 2.5%–7.7% in buccal and 8.7%–13.6% in palatal roots, respectively.

Comparing the calculated mean distances and the secondary study parameters, no statistically significant correlations were found. However, males tended to have their premolar roots closer to the maxillary sinus compared with females. This observation may be explained by the fact that premolar roots are generally longer in males than in females, and the maxillary sinus on average presents larger dimensions in males than in females (21, 23, 24). An invariable observation was that the absence of 1 premolar influenced the mean distance between the root and the maxillary sinus in the other premolar. In 25 situations with the first premolar missing, the mean distance between the second premolar and the maxillary sinus was greater compared with when both premolars were present. Because only 4 second premolars (16%) had migrated anteriorly into the position of the

TABLE 9. Frequency Analysis of the Root Position of the First Premolars with Respect to the Border of the Maxillary Sinus

	Sagittal plane		Coronal plane*		Axial plane*	
	N	%	N	%	N	%
Buccal roots						
Root tip below/outside border of MS	173	97.7	140	98.6	147	99.3
Root tip at border of MS	1	0.6	2	1.4	0	0
Root tip above/inside border of MS	3	1.7	0	0	1	0.7
Total	177	100	142	100	148	100
Palatal roots						
Root tip below/outside border of MS	78	92.9	59	92.2	64	92.8
Root tip at border of MS	1	1.2	2	3.1	0	0
Root tip above/inside border of MS	5	5.9	3	4.7	5	7.2
Total	84	100	64	100	69	100

MS, maxillary sinus.

*The distribution of the percentages comparing buccal and palatal roots was statistically significantly different in the coronal plane ($P = .03$) and in the axial plane ($P = .01$).

TABLE 10. Frequency Analysis of the Root Position of the Second Premolars with Respect to the Border of the Maxillary Sinus

	Sagittal plane*		Coronal plane*		Axial plane	
	N	%	N	%	N	%
Buccal roots						
Root tip below/outside border of MS	111	93.2	111	94.1	81	89
Root tip at border of MS	4	3.4	4	3.4	3	3.3
Root tip above/inside border of MS	4	3.4	3	2.5	7	7.7
Total	119	100	118	100	91	100
Palatal roots						
Root tip below/outside border of MS	19	76	18	78.3	19	86.4
Root tip at border of MS	3	12	3	13	0	0
Root tip above/inside border of MS	3	12	2	8.7	3	13.6
Total	25	100	23	100	22	100

MS, maxillary sinus.

*The distribution of the percentages comparing the buccal and palatal roots was statistically significantly different in the sagittal plane ($P = .02$) and the coronal plane ($P = .02$).

TABLE 11. Overview of Studies (in chronologic order) Assessing Root Positions Relative to the Floor of the Maxillary Sinus

Authors	Study material	Methodology	Metric measurements	Evaluated teeth
Eberhardt et al, 1992 (12)	38 patients	CT (sites were examined in sagittal, coronal, and axial planes)	Yes (distance from root to sinus floor)	First premolars through to second molars
Kwak et al, 2004 (13)	33 sides of hemi-sectioned cadaver heads	Demineralized maxillae were sectioned through long axis of teeth and scanned images were analyzed	Yes (distance from root to sinus floor and from root to appropriate cortical plate)	First premolars through to second molars
Ariji et al, 2006 (4)	120 patients	CT (axial plane)	No (horizontal root positions within alveolar process)	First and second molars only
Sharan and Madjar, 2006 (11)	80 patients	Comparison of panoramic radiography and CT (coronal plane)	No (qualitative classification of vertical root position relative to sinus floor)	Second premolars, first and second molars
Howe, 2009 (14)	37 human cadaver maxillae with 69 first molars	Comparison of CBCT and gross dissection (coronal plane)	Yes (minimum distance from root to sinus floor and from root to appropriate cortical plate)	First molars only
Kilic et al, 2010 (15)	92 patients	CBCT (coronal plane)	Yes (minimum distance from root to sinus floor)	First premolars through to third molars
Georgescu et al, 2012 (16)	51 patients	Comparison of CBCT (panoramic and cross sections) and panoramic radiography	Yes (distance from root to sinus floor)	First premolars* through to second molars
Jung and Cho, 2012 (17)	83 patients	CBCT (coronal plane)	Yes (distance from root to sinus floor and horizontal distance to appropriate cortical plate)	First and second molars
Pagin et al, 2013 (18)	50 patients	CBCT (sagittal, coronal and axial planes)	No (qualitative classification of vertical root position relative to sinus floor)	First premolars through to third molars
Present study	192 patients	CBCT (sagittal, coronal and axial planes)	Yes (minimum distance from root to sinus border)	First and second premolars

CBCT, cone-beam computed tomography; CT, computed tomography.

*Only premolars with fused roots were assessed.

first premolar, the anterior position of the second premolar could only partly explain those findings. The opposite was found in the first premolar when the second premolar was missing with shorter mean distances between the first premolar and the maxillary sinus. Removal, loss, or agenesis of the second premolar may have either resulted in an expansion of the maxillary sinus or a more anterior position of the first molar, accounting for the closer position of the maxillary sinus floor to the first premolar. An issue not addressed in the present study was whether subjects had any history of orthodontic treatment. External root resorption (blunting) caused by orthodontics may also affect the measured distances from root surfaces to the border of the maxillary sinus.

Conclusions

The following conclusions regarding the proximity of premolar roots to the maxillary sinus can be drawn from this CBCT-based investigation:

1. Palatal roots of first premolars were always located closer to the maxillary sinus than buccal roots (irrespective of the CBCT plane)
2. Roots of second premolars were, on average, positioned much closer to the maxillary sinus than roots of first premolars
3. Protrusion of roots inside the maxillary sinus was rare in first premolars and low in second premolars

4. Sex, age, side, and absence of 1 premolar failed to have a significant effect on the mean distance between premolar roots and the border of the maxillary sinus
5. If the distance between premolar roots and the maxillary sinus appears to be critical, taking a CBCT scan is suggested for diagnosis, treatment planning, and surgical intervention.

Acknowledgments

The authors thank Lukas Martig, Institute of Mathematical Statistics and Actuarial Science, University of Bern, Bern, Switzerland, for his assistance during the statistical analysis.

The authors deny any conflicts of interest related to this study.

References

1. Punwutikorn J, Waikakul A, Pairuchvej V. Clinically significant oroantral communications—a study of incidence and site. *Int J Oral Maxillofac Surg* 1994;23:19–21.
2. Oberli K, Bornstein MM, von Arx T. Periapical surgery and the maxillary sinus: radiographic parameters for clinical outcome. *Oral Surg Oral Med Oral Pathol Oral Radiol Endod* 2007;103:848–55.
3. Nedbalski TR, Laskin DM. Use of panoramic radiography to predict possible maxillary sinus membrane perforation during dental extraction. *Quintessence Int* 2008;39:661–4.
4. Ariji Y, Obayashi N, Goto M, et al. Roots of the maxillary first and second molars in horizontal relation to alveolar cortical plates and maxillary sinus: computed tomography assessment for infection spread. *Clin Oral Investig* 2006;10:35–41.

5. Bornstein MM, Wasmer J, Sendi P, et al. Characteristics and dimensions of the Schneiderian membrane and apical bone in maxillary molars referred for apical surgery: a comparative radiographic analysis using limited cone beam computed tomography. *J Endod* 2012;38:51–7.
6. Lu Y, Liu Z, Zhang L, et al. Associations between maxillary sinus mucosal thickening and apical periodontitis using cone-beam computed tomography scanning: a retrospective study. *J Endod* 2012;38:1069–74.
7. Phothikhun S, Suphanantachat S, Chuenchompoonut V, Nisapakultrorn K. Cone-beam computed tomographic evidence of the association between periodontal bone loss and mucosal thickening of the maxillary sinus. *J Periodontol* 2012;83:557–64.
8. Shanbhag S, Karnik P, Shirke P, Shanbhag V. Association between periapical lesions and maxillary sinus mucosal thickening: a retrospective cone-beam computed tomographic study. *J Endod* 2013;39:853–7.
9. Sharan A, Madjar D. Maxillary sinus pneumatization following extractions: a radiographic study. *Int J Oral Maxillofac Implants* 2008;23:48–56.
10. Jun BC, Song SW, Park CS, et al. The analysis of maxillary sinus aeration according to aging process; volume assessment by 3-dimensional reconstruction by high-resolution CT scanning. *Otolaryngol Head Neck Surg* 2005;132:429–34.
11. Sharan A, Madjar D. Correlation between maxillary sinus floor topography and related root position of posterior teeth using panoramic and cross-sectional computed tomography imaging. *Oral Surg Oral Med Oral Pathol Oral Radiol Endod* 2006;102:375–81.
12. Eberhardt JA, Torabinejad M, Christiansen EL. A computed tomographic study of the distances between the maxillary sinus floor and the apices of the maxillary posterior teeth. *Oral Surg Oral Med Oral Pathol* 1992;73:345–6.
13. Kwak HH, Park HD, Yoon HR, et al. Topographic anatomy of the inferior wall of the maxillary sinus in Koreans. *Int J Oral Maxillofac Surg* 2004;33:382–8.
14. Howe RB. First molar radicular bone near maxillary sinus: a comparison of CBCT analysis and gross anatomic dissection for small bony measurement. *Oral Surg Oral Med Oral Pathol Oral Radiol Endod* 2009;108:264–9.
15. Kilic C, Kamburoglu K, Yuksei SP, Ozen T. An assessment of the relationship between the maxillary sinus floor and the maxillary posterior teeth root tips using dental cone-beam computerized tomography. *Eur J Dent* 2010;4:462–7.
16. Georgescu CE, Rusu MC, Sandulescu M, et al. Quantitative and qualitative bone analysis in the maxillary lateral region. *Surg Radiol Anat* 2012;34:551–8.
17. Jung YH, Cho BH. Assessment of the relationship between maxillary molars and adjacent structures using cone beam computed tomography. *Imaging Sci Dent* 2012;42:219–24.
18. Pagin O, Centurion BS, Rubira-Bullen IR, Alvares Capelozza AL. Maxillary sinus and posterior teeth: accessing close relationship by cone-beam computed tomographic scanning in a Brazilian Population. *J Endod* 2013;39:748–51.
19. Brunner E, Domhof S, Langer F. *Nonparametric Analysis of Longitudinal Data in Factorial Experiments*. New York: Wiley; 2002.
20. Hirata Y, Kino K, Nagaoka S, et al. A clinical investigation of oro-maxillary sinus perforation due to tooth extraction (article in Japanese). *Kokubyo Gakkai Zasshi* 2001;68:249–53.
21. Kim HJ, Yoon HR, Kim KD, et al. Personal-computer-based three-dimensional reconstruction and simulation of maxillary sinus. *Surg Radiol Anat* 2002;24:393–9.
22. Kopecka D, Simunek A, Brazda T, et al. Relationship between subsinus bone height and bone volume requirements for dental implants: a human radiographic study. *Int J Oral Maxillofac Implants* 2012;27:48–54.
23. Gosau M, Rink D, Driemel O, Draenert FG. Maxillary sinus anatomy: a cadaveric study with clinical implications. *Anat Rec* 2009;292:352–4.
24. Sahlstrand-Johnson P, Jannert M, Strömbeck A, Abul-Kasim K. Computed tomography measurements of different dimensions of maxillary and frontal sinuses. *BMC Med Imaging* 2011;11:8.