

Assessing the Accuracy Factors in the Determination of Postoperative Acetabular Cup Orientation Using Hybrid 2D–3D Registration

Guoyan Zheng¹

Single standard anteroposterior radiograph-based methods for measuring cup orientation following total hip arthroplasty (THA) are subject to substantial errors if the individual pelvic orientation with respect to X-ray plate is not taken into consideration. Previously, we proposed to use a hybrid 2D–3D registration scheme to determine the postoperative acetabular cup orientation and developed an object-oriented cross-program called “HipMatch.” However, its accuracy and robustness have not been fully investigated. To assess the potential factors that may affect the accuracy and robustness of the hybrid 2D–3D registration scheme in determining the postoperative acetabular cup orientation, a comprehensive validation study using a cadaver pelvis was performed. Nine X-ray radiographs taken from different pelvic positions relative to the X-ray plate and two computed tomography volumes of the pelvis with one acquired before the cup implantation and the other acquired after the cup implantation were used in the validation study. Potential factors that may affect the accuracy and robustness of the hybrid 2D–3D registration scheme were experimentally determined. Our experimental results demonstrate that (1) the plain radiograph-based method is not accurate; (2) the hybrid 2D–3D registration scheme helps to improve the estimation accuracy; (3) the hybrid 2D–3D registration scheme can robustly and accurately estimate the cup orientation even when a big portion of the radiograph is occluded; and (4) image resolution has minor effect on the estimation accuracy. The hybrid 2D–3D registration scheme is an accurate and robust method to measure exact cup orientation in THA. It holds the promise to be a valuable tool for clinical routine usage for providing evidence-based information.

KEY WORDS: Postoperative cup orientation, X-ray radiograph, 2D–3D registration, intensity-based registration, validation

INTRODUCTION

Total hip arthroplasty (THA) has high social-economic impact. In developed countries including South Korea and Japan, more than 1.1

million THAs were operated in 2006¹. Among them, more than 650,000 hip joint replacements and hip revision surgeries were performed in the European Union. USA alone contributed another 420,000 hip joint arthroplasties¹.

Proper component positioning is essential for THA in regards to both the short-term complications and long-term survival results^{2–6}. Previous studies demonstrate that the higher rates of pelvis osteolysis, the severity of the polyethylene wear, and the component migration have all been well associated with the malpositioning of the acetabular component, and surgical experience indicates that the malorientation of the acetabular component in terms of anteversion and inclination is the major cause of dislocation^{2–6}. It is thus very important to develop an accurate method to measure the postoperative cup orientation for a reasonable follow-up after THA.

Two-dimensional anteroposterior (AP) pelvic radiograph is the standard imaging means for measuring the postoperative cup orientation^{7–10}. Although it has an inferior accuracy in comparison to 3D techniques based on computed tomography^{7,8}, it is used routinely because of its simplicity, availability, and minimal expense associated with its acquisition. While plain pelvic

¹From the ARTORG Research Center–ISTB, University of Bern, Stauffacherstrasse 78, CH-3014, Bern, Switzerland.

Correspondence to: Guoyan Zheng, ARTORG Research Center–ISTB, University of Bern, Stauffacherstrasse 78, CH-3014, Bern, Switzerland; tel: +41-31-6315956; fax: +41-31-6315960; e-mail: guoyan.zheng@iee.org

Copyright © 2009 by Society for Imaging Informatics in Medicine

Online publication 21 July 2009

doi: 10.1007/s10278-009-9226-4

radiographs are easily obtained, their accurate interpretations are subject to substantial errors if the individual pelvis orientation with respect to X-ray plate is not taken into consideration^{7,8,11}. For example, the increased pelvic tilt will result in significant decreases in apparent prosthetic cup anteversion and vice versa¹². The errors resulted from the incorrect interpretation of the cup orientation affect the accuracy of studies correlating cup position to osteolysis, wear, and instability.

When a preoperative computed tomography (CT) scan is available, 2D–3D image registration methods^{13–16} have been introduced to measure the postoperative cup orientation with respect to an anatomical reference extracted from the preoperative CT scan, which is a plane called the anterior pelvic plane (APP) defined by the anterior superior iliac spines (ASIS) and the pubic tubercles^{11,17,18}. In such methods, both the prosthesis and the preoperative CT scan are first registered to the postoperative X-ray image, which then allows for computing the position of the implant with respect to the APP extracted from the preoperative CT scan. Although early encouraging results are reported in several studies^{13–16}, the extensive application of these methods in clinical routine is still limited. This may be explained by their requirement of a computer-aided design (CAD) model of the prosthesis^{14–16}, which often is difficult to be organized from the manufacturer due to the proprietary issue and by their requirement of either multiple radiographs^{13,16} or a radiograph-specific calibration^{14,15}, both of which are not available for most retrospective studies or earlier cup designs.

To address these issues, previously, we proposed a hybrid 2D–3D registration scheme¹⁹ combining an iterative landmark-to-ray registration with a 2D–3D intensity-based registration to estimate a rigid transformation between a preoperative CT volume and the postoperative X-ray radiograph for an accurate determination of cup orientation. No registration between the prosthesis and the X-ray radiograph is required, thus eliminating the necessity of possessing the CAD models of the prosthesis. Based on this scheme, an object-oriented cross-platform program named “HipMatch” has been developed²⁰.

Several factors may affect the determination accuracy of our approach, including the registration strategy, the image occlusion caused by a gonadal shielding, and the resolution of the X-ray

radiograph. This paper presents a comprehensive validation study of our approach using a cadaver pelvis. The questions that we would like to answer by this validation study are: (1) is it necessary to use the intensity-based 2D–3D registration? or put it in another way, is the use of the landmark-based 2D–3D registration alone accurate enough for our task? (2) Is the estimation obtained from our approach still accurate enough when part of the X-ray radiograph is occluded by a gonadal shielding? (3) What is the effect of the resolution of the X-ray radiograph on the estimation accuracy? The answers to these questions are important for the future clinical applications of our approach.

MATERIALS AND METHODS

Problem Formulation

The basic idea of determining cup orientation using 2D–3D registration can be summarized by the following equation (see Fig. 1 for details)^{19,20}:

$$\vec{n}_{APP} = T_{APP}^{CT} \times T_{CT}^R \times \vec{n}_R \quad (1)$$

where \vec{n}_R means the orientation of the cup measured in the postoperative X-ray radiograph coordinate system; T_{CT}^R is the rigid transformation between the postoperative X-ray radiograph coordinate system and the preoperative CT data coordinate system, and T_{APP}^{CT} is the transformation between the preoperative CT data coordinate system and a coordinate system defined on APP (see Fig. 1 for details). In order to know the cup orientation with respect to the APP that is extracted from the preoperative CT data (pre-op APP), Eq. 1 tells us that we can first compute the cup orientation with respect to the postoperative X-ray radiograph coordinate system and then transform it to the coordinate system defined on the preoperative APP through a transformation chain. The advantages of such a formulation include (a) the independence of a specific CAD model of the cup and (b) the elimination of a radiograph-specific calibration. The only information that we assume to know about the postoperative X-ray radiograph is the image scale (pixel/mm) and the distance from the focal point to the imaging plane or to the film. As long as the postoperative radiograph is acquired in a standardized way, which is performed in a clinical routine¹⁰, they can be estimated by performing one-time calibration²¹.

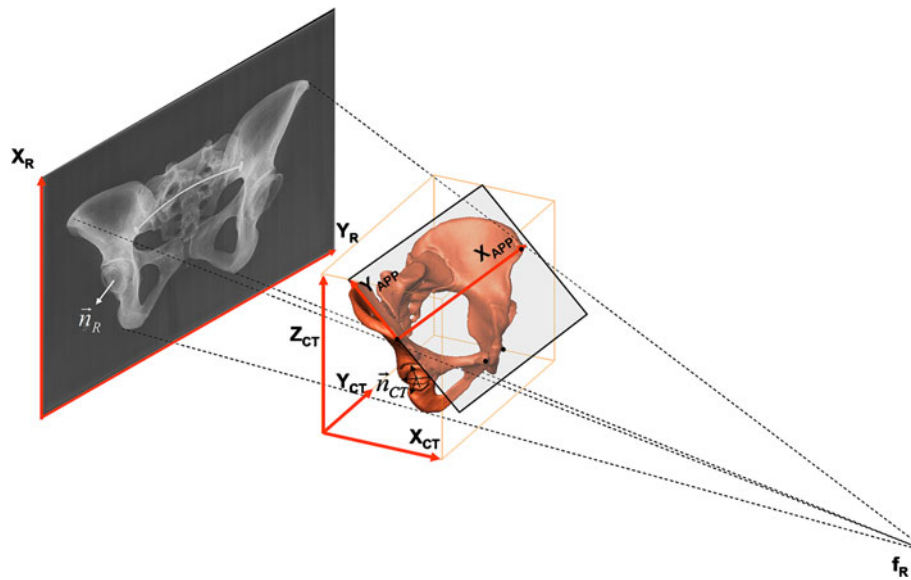


Fig 1. Schematic representation of 2D–3D registration for determination of cup orientation from single standard X-ray radiograph.

The computations of \vec{n}_R and T_{APP}^{CT} are trivial. In this work, we use the method introduced in⁹ to find \vec{n}_R and the method published in¹⁷ to find T_{APP}^{CT} . The challenge lies in the computation of T_{CT}^R , which is solved by the hybrid 2D–3D registration scheme^{19,20} combining an iterative landmark-to-ray registration with a 2D–3D intensity-based registration.

Cup Orientation Determination Protocol

Our cup orientation estimation protocol includes the following five steps:

1. CT data processing and landmark extraction: In this step, we first extract the surface models of both pelvis and femur from the CT volume data and then define the region of interest, which will be used in step 4 to exclude the contribution of most of the femur part to the digitally reconstructed radiograph (DRR)—an image obtained from the CT volume data by simulating X-ray projection. We then interactively extract two sets of landmarks from the CT data: (a) landmarks for measuring cup orientation, including the left and the right ASIS, and the pubic tubercles; they are used to define the APP and to compute T_{APP}^{CT} . (b) Landmarks for registration, including the left and the right acetabular centers (by interactive sphere fit-

ting), the pubic symphysis, and the middle of the sacrococcygeal joint (see Fig. 2 for details).

2. X-ray radiograph landmark extraction: In this step, two sets of landmarks are interactively picked from the radiograph: (a) three landmarks for measuring cup orientations as described in⁹ (see Fig. 3a for details), which are used to calculate the radiographic cup orientation \vec{n}_R , and (b) the corresponding projections of those CT landmarks for registration, including the left and the right acetabular centers, the upper border of the symphysis, and the middle of the sacrococcygeal joint. The local coordinate

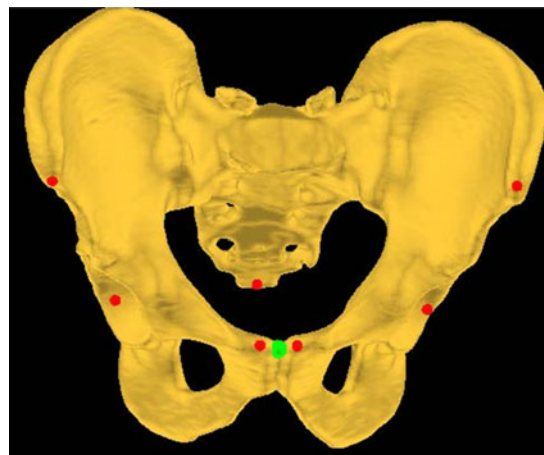


Fig 2. Landmarks extracted from a preoperative CT volume.

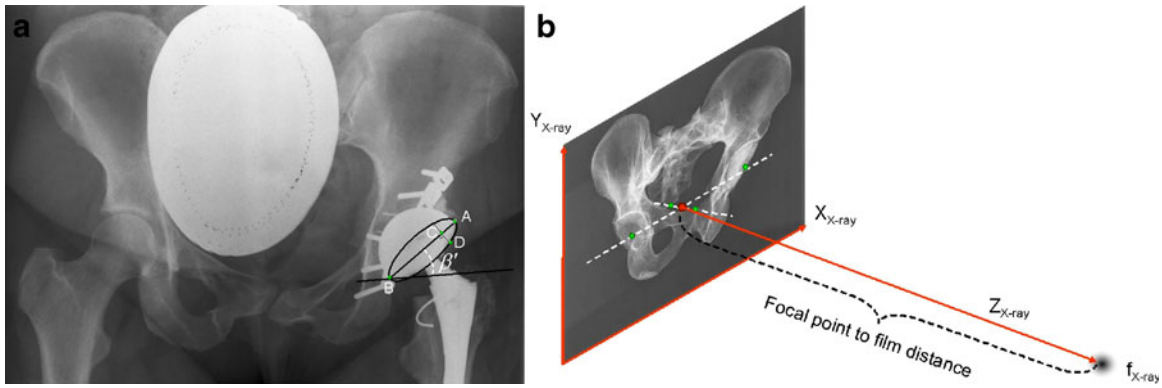


Fig 3. a Three landmarks and the measurement lines used in the method introduced in [2] for measuring the cup orientation (α' = anteversion, β' = inclination) out of the AP pelvic radiograph. A line is drawn at one fifth distance of the maximum diameter $|AB|$ and perpendicular to the major axis AB of the projected ellipse. It intersects with line AB at point C and with the visible arc of the cup projection at point D. Then, the anteversion of the implanted cup measured out of the plain radiograph is: $\alpha' = \arcsin\left(\frac{|CD|}{0.4|AB|}\right)$. b Schematic radiograph coordinate system and the cone-beam projection model established using the extracted landmarks.

reference and the cone-beam projection model of the radiograph is then established as follows (see Fig. 3b for details). The intersection between the line connecting the middle of the sacrococcygeal joint and the upper border of the symphysis and the line connecting the acetabular centers is assumed to be the cone-beam projection center and is taken as the coordinate origin. The central projection line is perpendicular to the radiograph plane and its opposite direction is regarded as Z-axis.

3. Landmark-based 2D–3D registration: Using those 3D landmarks picked from the CT data and their corresponding 2D landmarks picked from the radiograph, a landmark-based 2D–3D registration is performed. Such a problem is known as the perspective-n-points problem in computer vision community, and both analytic solutions and iterative solutions exist before²². To avoid ambiguity, we adopted an iterative strategy²³. The estimated rigid transformation is then treated as the starting value for next step. Figure 4a shows a screenshot of our program after the landmark-based 2D–3D registration.
4. Intensity-based 2D–3D registration: The rigid transformation obtained from the last step will be fine-tuned by an intensity-based 2D–3D registration. In this work, we used a spline-based multi-resolution 2D–3D image registration scheme²⁴ incorporating a robust similarity measure that is derived from a Markov random field theory²⁵, allowing for effective incorporation of spatial information into the intensity-

based 2D–3D registration. For details about the 2D–3D image registration scheme and the robust similarity measure, we refer to the previously published works^{24,25}. Figure 4b shows a screenshot of our program after the intensity-based 2D–3D registration.

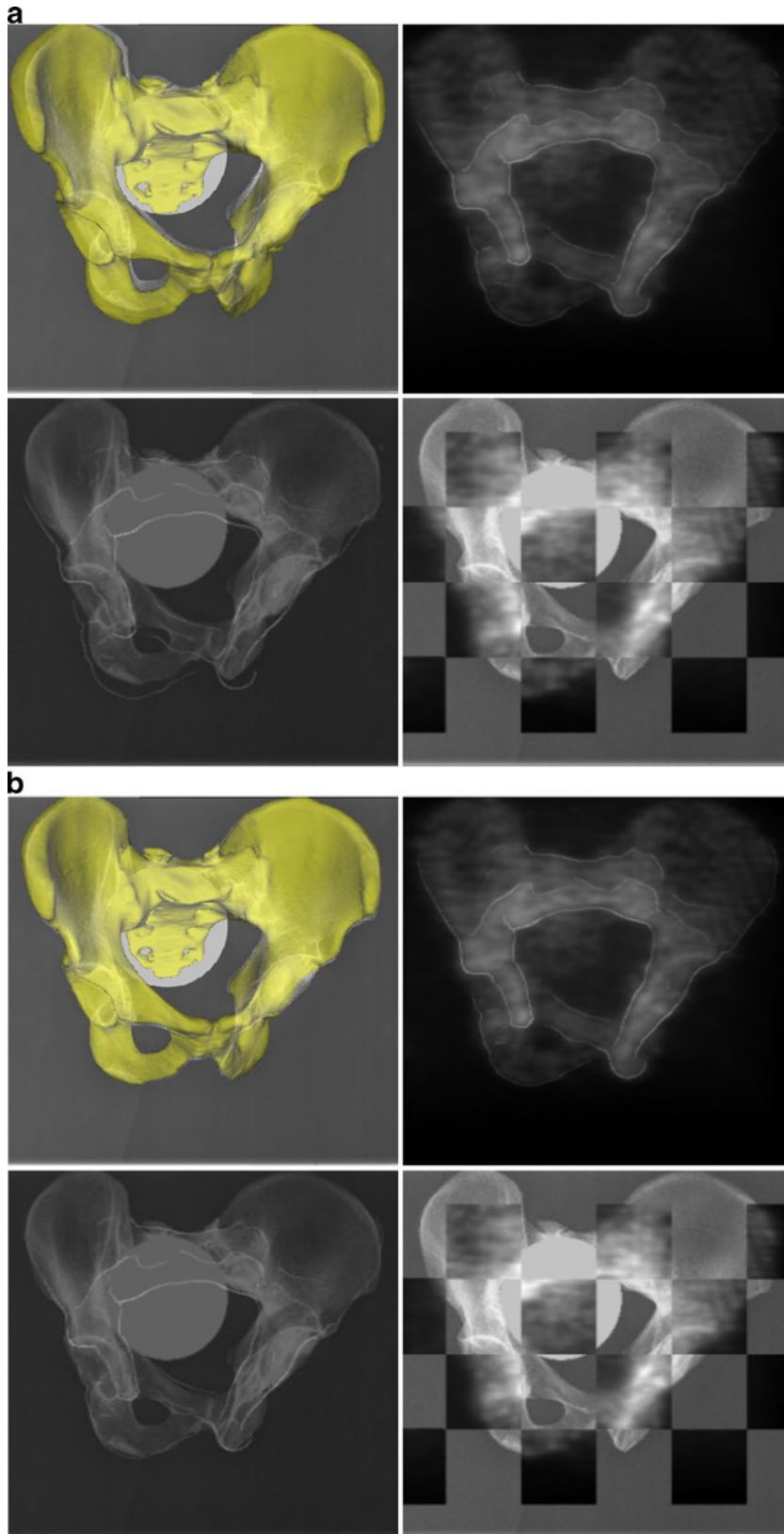
5. Cup orientation determination: In this step, we will determine the cup orientation relative to the anterior pelvic plane of the patient using Eq. 1.

Experiments

Experimental Setup

To quantitatively evaluate the estimation accuracy of our approach, a cadaver pelvis and an all-

Fig 4. a Screenshot of our program after the landmark-based 2D–3D registration. The estimated rigid transformation is taken as the start value of the intensity-based 2D–3D registration. In this image, the *top left window* shows the superposition of the segmented CT surface model on the X-ray image; the *top right window* shows the DRR created from a down-sampled CT data; the *bottom left window* shows the superposition of the edges extracted from the DRR on the X-ray images; and the *bottom right window* shows the check board display of the DRR and the X-ray image. b Screenshot of our program after the intensity-based 2D–3D registration. The estimated cup orientation angles with respect to the APP are calculated based on the 2D–3D registration result. In this image, the *top left window* shows the superposition of the segmented CT surface model on the X-ray image; the *top right window* shows the DRR created from a down-sampled CT data; the *bottom left window* shows the superposition of the edges extracted from the DRR on the X-ray images; and the *bottom right window* shows the check board display of the DRR and the X-ray image.



polyethylene acetabular component (Charles F. Thackray, Leeds, UK) were used. Before the cup was implanted, we did a CT scan of the cadaver pelvis (pre-op CT). After the cup was implanted, we took nine radiographs by putting the pelvis in different tilt and rotation positions relative to the

X-ray plate. The definitions of the tilt and the rotation as well as the acquired nine radiographs are shown in Figure 5a, b, respectively. To get the ground truth about the cup orientation relative to the anterior pelvis plane of the cadaveric pelvis, we did another CT scan of the pelvis after the

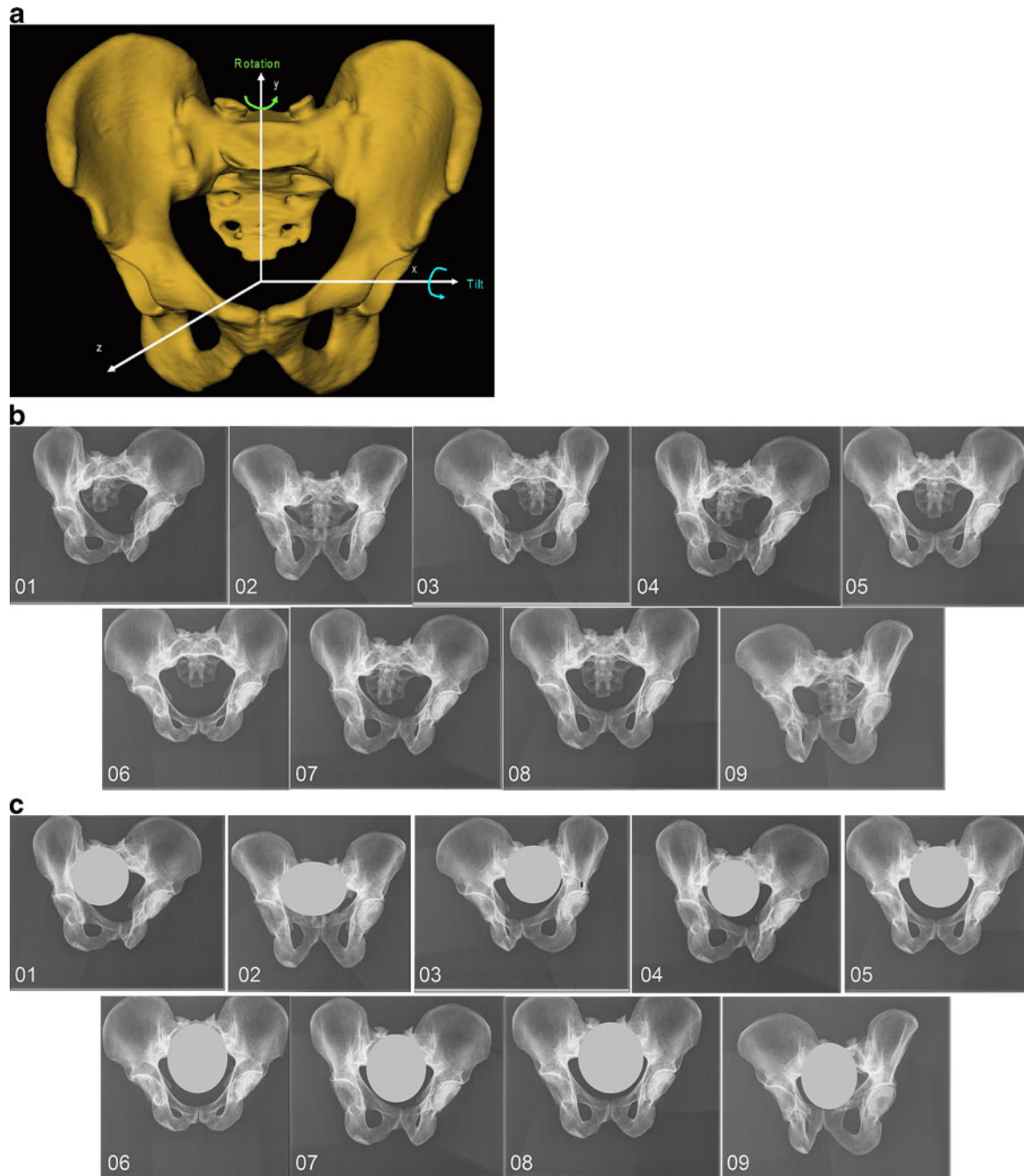


Fig 5. a Definitions of the tilt and the rotation of the pelvis relative to the X-ray plate. b Acquired nine X-ray radiographs of the pelvis. c Nine X-ray radiographs with simulated occlusions.

prosthesis was implanted (post-op CT). The method introduced in¹⁷ was used to extract the ground truth from the post-op CT scan.

Our program then reads the CT data and the X-ray images in DICOM format. Both CT scans have voxel dimensions of $0.826 \times 0.826 \times 2 \text{ mm}^3$ and image sizes of $512 \times 512 \times 125$ voxels. All X-ray radiographs have pixel dimensions of $0.143 \times 0.143 \text{ mm}^2$ and image sizes between $2,761 \times 2,345$ and $2,990 \times 2,462$ pixels.

A gonadal shielding during diagnostic X-ray procedure is an effective way of reducing radiation dose to patient's reproductive organs to decrease the risk of genetic effects in future generations²⁶. However, the utilization of the gonadal shielding also causes the occlusion of a big portion of the X-ray radiograph, which poses a challenge to the intensity-based 2D–3D registration. In this paper, we investigated the effect of the gonadal shielding on the determination accuracy using simulated data created from the nine X-ray radiographs. To simulate the occlusion caused by a gonadal shielding, we intentionally set a region covering around one fifth of the valid image area of each radiograph with constant gray value as shown in Figure 5c.

To investigate the effect of the resolution of the X-ray radiograph on the determination accuracy, three groups of new images were created by down-sampling each one of the original nine X-ray radiographs with three different sampling rates along each dimension: 2, 4, and 8, respectively. The resultant images have lower resolutions than the original ones, i.e., the first group has image sizes between $1,380 \times 1,172$ and $1,495 \times 1,231$ pixels; the second group has image sizes between 690×586 and 747×615 pixels; and the third group has image sizes between 345×293 and 373×307 pixels. Further down-sampling the images makes it difficult, if it is not impossible, to identify the cup projection rim from those down-sampled images.

For all experiments, we used an Intel Centrino Duo Core 2.33-GHz laptop with 4 GB of RAM. All programming was done using Visual C++ 2005 on Windows Vista; additional functionality was implemented using a cross-platform graphical user interface programming framework Qt 3.3.6 (TrollTech, Oslo, Norway). Each time, the differences between the measurement results and the ground truth were regarded as the measurement errors. All measurement errors were then input to Microsoft Excel® 2003 (Microsoft Corporation,

Redmond, USA) for statistics. The significant level was chosen as $\alpha=0.01$.

Experimental Studies

Using the above setup, we designed and conducted the following three studies:

1. Effect of registration strategy on the determination accuracy: The purposes of this study were twofold. First, we would like to measure the estimation accuracy achieved by each registration step. Second, we would like to know whether the use of the landmark-based 2D–3D registration alone is enough for our task. For these purposes, each time, one of the nine radiographs was used together with the pre-op CT data to determine the cup orientation relative to the anatomical reference extracted from the CT data. Three measurement results were then recorded and compared to the ground truth: (1) the measurement results using the conventional plain film techniques described in⁹; (2) the measurement results after the landmark-based 2D–3D registration was applied; and (3) the measurement result after both the landmark-based 2D–3D registration and the intensity-based 2D–3D registration were applied.
2. Effect of image occlusion on the determination accuracy: The aim of this study was to evaluate the effect of the image occlusion caused by a gonadal shielding on the determination accuracy. In this study, each time, one of the nine radiographs with simulated occlusions was used together with the pre-op CT data to estimate the cup orientation. The estimated results were recorded and compared to the ground truth.
3. Effect of image resolution on the determination accuracy: The purpose of this study was to evaluate the effect of the X-ray image resolution on the estimation accuracy. Each time, one of the down-sampled images from the three groups was used together with the pre-op CT data to estimate the cup orientation. The estimated results were recorded and compared to the ground truth.

EXPERIMENTAL RESULTS

The results of the registration strategy study are presented in Table 1. Errors of $11.6^\circ \pm 6.8^\circ$ were

Table 1. Registration Strategy Study Results

Angle	Img_01	Img_02	Img_03	Img_04	Img_05	Img_06	Img_07	Img_08	Img_09	average
Estimation errors when the plain film technique was used										
Anteversion (deg)	13.5	1.6	1.9	20.4	9.9	18.7	17.3	12.0	9.5	11.6 ± 6.8
Inclination (deg)	1.2	5.8	2.9	1.9	0.1	0.3	1.2	2.0	0.8	1.8 ± 1.7
Estimation errors after the landmark-based 2D–3D registration										
Anteversion (deg)	5.7	3.0	2.2	3.5	4.0	4.7	4.5	4.3	1.4	3.7 ± 1.3
Inclination (deg)	1.7	0.3	2.8	0.9	1.1	2.3	0.9	4.2	3.1	1.9 ± 1.3
Estimation errors after the intensity-based 2D–3D registration										
Anteversion (deg)	2.1	0.1	0.9	2.3	0.4	0.5	1.7	1.7	0.1	1.1 ± 0.9
Inclination (deg)	0.7	0.9	0.9	0.3	0.3	1.4	0.8	0.3	1.0	0.7 ± 0.4

found for determining the anteversion (range, 1.6° to 20.4°) and errors of $1.8^\circ \pm 1.7^\circ$ were found for determining the inclination (range, 0.1° to 5.8°) when the conventional plain film measurement technique as introduced in⁹ was used. Our findings are coincident with other recently published findings^{7,8,11,16} that the radiographic measurement of anteversion is unreliable. As observed in our experiment, the anteversion difference between the radiographic measurement and the ground truth depends on the pelvis orientation during the acquisition and could be almost as big as 20°. When only the landmark-based 2D–3D registration was used, the errors for estimating the anteversion were reduced to $3.7^\circ \pm 1.3^\circ$ (range, 1.4° to 5.7°) and the errors for estimating the inclination were changed to $1.9^\circ \pm 1.3^\circ$ (range, 0.3° to 4.2°). Using a paired two-tailed *t* test, it was found that the differences between the radiographic measurements of the anteversion and those obtained by applying only the landmark-based 2D–3D registration were statistically significant ($p=0.0046 < 0.01$), while the differences for the inclination observation were not ($p=0.88 > 0.01$). The results demonstrate (1) that the planar radiograph-based method⁹ may be accurate for measuring the inclination, but definitely not accurate enough for measuring anteversion, and (2) that the landmark-based 2D–3D registration can significantly improve the anteversion measurement accuracy. When both the landmark-based 2D–3D registration and the intensity-based 2D–3D registration were

applied, the errors for estimating the anteversion were reduced to $1.1^\circ \pm 0.9^\circ$ (range, 0.1° to 2.3°) and the errors for estimating the inclination were reduced to $0.7^\circ \pm 0.4^\circ$ (range, 0.3° to 1.4°). Statistically, the differences between the measurements obtained from applying the hybrid 2D–3D registration scheme and those obtained from applying only the landmark-based 2D–3D registration were significant for anteversion observation ($p=0.00011 < 0.01$), but not for inclination observation ($p=0.026 > 0.01$). Such results demonstrate that the intensity-based 2D–3D registration helps to further improve the anteversion estimation accuracy and that for a precise estimation of the anteversion, it is necessary to use the hybrid 2D–3D registration scheme combining the landmark-based 2D–3D registration with the intensity-based 2D–3D registration. However, such an improvement is not without a cost. It took our program on average 165 s to finish the hybrid 2D–3D registration.

The estimation errors for the image occlusion study are presented in Table 2. With the simulated gonadal shielding, the errors were slightly higher: $2.0^\circ \pm 1.7^\circ$ for estimating anteversion and $0.7^\circ \pm 0.3^\circ$ for estimating inclination. When the results obtained using the original X-ray radiographs were compared to those obtained using the X-ray radiographs with simulated gonadal shielding, it was found that the differences between these two measurement results were not statistically significant ($p=0.021 > 0.01$ for anteversion observation and $p=0.47 > 0.01$ for inclination observation).

Table 2. Image Occlusion Study Results

Angle	Img_01	Img_02	Img_03	Img_04	Img_05	Img_06	Img_07	Img_08	Img_09	average
Anteversion (deg)	4.6	0.7	1.2	4.5	0.9	1.3	3.1	1.6	0.0	2.0 ± 1.7
Inclination (deg)	0.9	0.6	1.1	0.4	0.3	1.2	0.5	0.5	0.5	0.7 ± 0.3

Table 3. Image Resolution Study Results

angle	Img_01	Img_02	Img_03	Img_04	Img_05	Img_06	Img_07	Img_08	Img_09	average
Estimation errors when images from the first group were used										
Anteversion (deg)	2.5	0.8	2.1	2.1	0.8	0.8	0.9	0.0	0.5	1.2 ± 0.9
Inclination (deg)	1.0	0.6	0.4	0.2	0.5	2.1	0.0	0.1	0.6	0.6 ± 0.6
Estimation errors when images from the second group were used										
Anteversion (deg)	3.0	0.1	1.8	2.6	0.2	0.0	3.5	0.6	1.2	1.4 ± 1.3
Inclination (deg)	0.9	1.1	1.0	0.0	0.2	1.4	0.2	0.5	0.5	0.6 ± 0.5
Estimation errors when images from the third group were used										
Anteversion (deg)	1.9	0.2	0.9	2.8	0.2	1.8	2.0	0.7	1.9	1.4 ± 0.9
Inclination (deg)	0.4	0.5	1.2	0.5	0.0	2.2	0.8	0.8	1.2	0.8 ± 0.6

The estimation errors for the image resolution study are presented in Table 3. When images from the first group were used, errors of $1.2^{\circ} \pm 0.9^{\circ}$ were found for estimating anteversion and errors of $0.6^{\circ} \pm 0.6^{\circ}$ were found for estimating inclination. It took our program on average 22 s to finish the registrations. When images from the second group were used, the errors were changed to $1.4^{\circ} \pm 1.3^{\circ}$ for estimating anteversion and $0.6^{\circ} \pm 0.5^{\circ}$ for estimating inclination. The execution time for the 2D–3D registration was reduced to 4 s on average. Using further down-sampled images such as those from the third group, the errors were found to be $1.4^{\circ} \pm 0.9^{\circ}$ for estimating anteversion and $0.8^{\circ} \pm 0.6^{\circ}$ for estimating inclination. This time, it took our program on average only 1 s to finish the 2D–3D registrations. When the results obtained using any one of the three groups of the down-sampled images were compared to those obtained using the original X-ray radiographs, none of the differences were found to be statistically significant (see Table 4 for the statistical analysis results).

DISCUSSIONS AND CONCLUSIONS

Compared to previously published studies on determining postoperative cup orientation using

2D–3D registration^{13–16}, the study presented in this paper is more comprehensive. The focuses of previous studies are mainly on the experimental and clinical validation of using 2D–3D registration for accurate determination of postoperative cup orientation. Thus, none of the previous studies has investigated the potential factors that may affect the accuracy and robustness of the 2D–3D registration, which will ultimately determine the postoperative cup orientation measurement accuracy, and none of the previously introduced methods^{13–16} has been validated on X-ray radiograph with gonadal shielding. To the best knowledge of the author, the study presented in this paper is the first one that tries to experimentally determine those potential factors. Our experimental results indicate that: (1) the landmark-based 2D–3D registration can significantly increase the estimation accuracy. However, the use of landmark-based 2D–3D registration alone is not accurate enough for our task. Intensity-based 2D–3D registration helps to further improve the estimation accuracy. (2) A gonadal shielding in the X-ray radiograph does affect the estimation accuracy. However, with the hybrid 2D–3D registration scheme, the changes on the estimation accuracy are not statistically significant. Such results demonstrate that our approach can robustly and accurately estimate the cup orientation even when a big

Table 4. Paired Two-Tailed T Test Results When the Results Obtained Using One of the Three Groups of Down-Sampled Images Were Compared to Those Obtained Using the Original X-Ray Radiographs

<i>p</i> values	Results of the 1st group of down-sampled images vs. those of the original X-ray radiographs	Results of the 2nd group of down-sampled images vs. those of the original X-ray radiographs	Results of the 3rd group of down-sampled images vs. those of the original X-ray radiographs
<i>p</i> value of anteversion observation	0.79 > 0.01	0.27 > 0.01	0.33 > 0.01
<i>p</i> value of inclination observation	0.45 > 0.01	0.41 > 0.01	0.43 > 0.01

portion of the radiograph is occluded by a gonadal shielding. (3) Image resolution has a minor effect on the determination accuracy. Such results demonstrate that we do not need an X-ray radiograph with full resolution to achieve an accurate determination of the postoperative cup orientation when the proposed approach is used, though for clinical purpose, a full-resolution X-ray radiograph will be preferred. It is suggested that we can use a down-sampled X-ray radiograph together with the preoperative CT as the input to the proposed approach, which will lead to an improved run time. The lower the image resolution is, the shorter the run time will be. However, there is a trade-off between the execution time and the resolution required for a clear identification of the cup projection rim.

As a limitation of our study, one has to discuss taking the one-time postoperative CT-based measurement as the ground truth. Previously, several studies^{7,8,27,28} have suggested that CT-based methods seem to be the most reliable method for noninvasive postoperative assessment of the acetabular cup orientation with experienced and trained observers. Nevertheless, intra- and inter-observer variability is still present²⁸. However, the influence of such variability on the results could not be determined with our study setup. Furthermore, any difference in extracting the APP from the preoperative CT and from the postoperative CT would result in differences in the accuracy evaluations, even though the definition of the APP was shown to be very reproducible²⁹.

Another limitation of this study is that it was based on one pelvis, although we used in total 18 X-ray radiographs, with nine of them acquired from different pelvic positions relative to the X-ray plate and the other nine created with simulated gonadal shielding. Due to the small sample size, the reproducibility and the reliability of the proposed approach cannot be answered in the present study.

While accurate, the proposed approach has limitations. The first limitation is the types of the cup that can be measured by our approach. Our approach can only be applied to those cups that have a circular opening surface. Nevertheless, our approach is applicable to all types of bearings due to the fact that the method according to Pradhan⁹ is used to calculate the cup version from the plain radiograph. The second limitation is that our approach in its current form is limited only to

those hips that have had a CT study at some point during the treatment. However, as demonstrated by our recent work³⁰, such a constraint can be totally eliminated through a statistically deformable registration of a statistical shape model of the pelvis to the X-ray image, which is solved by adapting the method that we introduced in³¹ to the application context of the present paper.

In summary, compared to previously introduced methods^{13–16}, our approach has several advantages. Our approach does not need a proprietary CAD model of the prosthesis, and our approach does not ask for multiple radiographs or a radiograph-specific calibration. Thus, our approach is more appropriate for long-term retrospective studies, which has been demonstrated by the convincing results of a recent validation study³². In this study, measurements on blinded and randomized radiographs of 80 cadaver and 327 patient hips were performed. When compared to CT-based measurements, our approach showed a mean accuracy of $0.7^\circ \pm 1.7^\circ$ (-3.7° to 4.0°) for inclination and $1.2^\circ \pm 2.4^\circ$ (-5.3° to 5.6°) for anteversion in the cadaver trials and $1.7^\circ \pm 1.7^\circ$ (-4.6° to 5.5°) for inclination and $0.9^\circ \pm 2.8^\circ$ (-5.2° to 5.7°) for anteversion in the clinical trial³². We are confident that our approach can be used retrospectively to provide evidence-based information for evaluating surgical technologies (e.g., surgical navigation) and implant design.

ACKNOWLEDGMENT

The author is grateful to Dr. Simon Steppacher, Dr. Xuan Zhang, and Dr. Moritz Tannast for their help in the experimental setup and to the anonymous reviewers for their constructive comments which helped improve the original manuscript.

REFERENCES

1. Kiefer H: Differences and opportunities of THA in the USA, Asia and Europe. In: Chang J-D, Billau K Eds. *Ceramics in Orthopaedics. Proceedings of the 12th BIOLOX® Symposium on Bioceramics and Alternative Bearings in Joint Arthroplasty*, Seoul, Republic of Korea, September 7–8, 2007. Springer, 2007, pp 3–8
2. Ali Kahn MA, Brakenbury PH, Reynolds IS: Dislocation following total hip replacement. *J Bone Jt Surg Br* 63B(2):214–218, 1981
3. McCollum DE, Gray WJG: Dislocation after total hip arthroplasty. Causes and prevention. *Clin Orthop* 261:159–170, 1990
4. Sarmiento A, Ebramzadeh E, Gogan WJ, McKellop HA: Cup containment and orientation in cemented total hip arthroplasties. *J Bone Jt Surg Br* 72B(6):996–1002, 1990

5. Bader RJ, Steinhauser E, Willmann G, Gradinger R: The effects of implant position, design and wear on the range of motion after total hip arthroplasty. *Hip Int* 11(2):80–90, 2001
6. Lewinnek GE, Lewis JL, Tarr R, Compere CL, Zimmerman JR: Dislocations after total hip-replacement arthroplasties. *J Bone Jt Surg Am* 60(2):217–220, 1978
7. Thomas T, Handel M, Herold T, Perlick L, Paetzel C, Grifka J: Position of the acetabular cup-accuracy of radiographic calculation compared to CT-based measurement. *Eur J Radiol* 58:294–300, 2006
8. Marx A, von Knoch M, Pförtner J, Wiese M, Saxler G: Misinterpretation of cup anteversion in total hip arthroplasty using planar radiography. *Arch Orthop Trauma Surg* 126:487–492, 2006
9. Pradhan R: Planar anteversion of the acetabular cup as determined from plain nteroposterior radiographs. *J Bone Jt Surg Br* 81-B:431–435, 1999
10. Della Valle CJ, Kaplan K, Jazrawi A, Ahmed S, Jaffe WL: Primary total hip arthroplasty with a flanged, cemented all-polyethylene acetabular component: evaluation at a minimum of 20 years. *J Arthroplasty* 19:23–26, 2004
11. Tannast M, Langlotz U, Siebenrock KA, Wiese KM, Bernsmann K, Langlotz F: Anatomical referencing of cup orientation in total hip arthroplasty. *Clin Orthop Relat Res* 436:144–150, 2005
12. Sellers RG, Lyles D, Dorr LD: The effect of pelvic rotation on alpha and theta angles in total hip arthroplasty. *Contemp Orthop* 17:67–70, 1988
13. Larose D, Cassenti L, Jaramaz B, Moody JE, Kanade T, DiGioia AM: Post-operative measurement of acetabular cup position using X-ray/CT registration. Proceedings of the 3rd International Conference on Medical Image Computing and Computer-Assisted Intervention (MICCAI 2000). LNCS 1935, 2000, pp 1104–1113
14. Blendea S, Eckman K, Jaramaz B, Levison TJ, DiGioia III, AM: Measurements of acetabular cup position and pelvic spatial orientation after total hip arthroplasty using computed tomography/radiography matching. *Comput Aided Surg* 10:37–43, 2005
15. Jaramaz B, Eckman K: 2D/3D registration for measurement of implant alignment after total hip replacement. Proceedings of the 9th International Conference on Medical Image Computing and Computer-Assisted Intervention (MICCAI 2006), LNCS 4191, 2006, pp 653–661
16. Penney GP, Edwards PJ, Hipwell JH, Slomczykowski M, Revie I, Hawkes DJ: Postoperative calculation of acetabular cup position using 2D–3D registration. *IEEE Trans Biomed Eng* 54:342–348, 2007
17. Jaramaz B, DiGioia III, AM, Blackwell M, Nikou C: Computer assisted measurement of cup placement in total hip replacement. *Clin Orthop Relat Res* 354:70–81, 1998
18. Langlotz U, Grützner PA, Bernsmann K, Kowal J, Tannast M, Caversaccio M, Nolte L-P: Accuracy considerations in navigated cup placement for THR. *Proc Inst Mech Eng [H]* 221:739–753, 2007
19. Zheng G, Steppacher S, Zhang X, Tannast M: Precise estimation of postoperative cup alignment from single standard X-ray radiograph with gonadal shielding. Proceedings of 2007 International Conference on Medical Image Computing and Computer Assisted Intervention (MICCAI 2007), Part II, LNCS 4792. Springer, 2007, pp 951–959
20. Zheng G, Zhang X, Steppacher S, Murphy SB, Siebenrock KA, Tannast M: HipMatch: an object-oriented cross-platform program for accurate determination of cup orientation using 2D–3D registration of single standard X-ray radiograph and a CT volume. *Comput Methods Programs Biomed* 95:236–248, 2009 doi:10.1016/j.cmpb.2009.02.009
21. The B: Digital radiographic peroperative planning and postoperative monitoring of total hip replacements—techniques, validation and implementation. Doctoral dissertations, University Medical Center Groningen, The Netherlands, 2006
22. Gao X-S, Hou X-R, Tang J, Cheng H-F: Complete solution classification for the perspective-three-point problem. *IEEE Trans Pattern Anal Mach Intell* 25:930–943, 2003
23. Wunsch P, Hirzinger G: Registration of CAD-models to image by iterative inverse perspective matching. Proceedings of the 1996 International Conference on Pattern Recognition (ICPR 1996), 1996, pp 78–83
24. Jonić S, Thévenaz P, Zheng G, Nolte L-P, Unser M: An optimized spline-based registration of a 3D CT to a set of C-Arm images. *Int J Biomed Imaging* 1–12, 2006 doi:10.1155/IJBI/2006/47197
25. Zheng G, Zhang X, Jonić S, Thévenaz P, Unser M, Nolte L-P: Point similarity measures based on MRF modeling of difference images for spline-based 2D-3D rigid registration of X-ray fluoroscopy to CT images. Proceedings of the 3rd International Workshop on Biomedical Image Registration (WBIR 2006), LNCS 4057, 2006, pp 186–194
26. Doolan A, et al: Gonad protection for the antero-posterior projection of the pelvis in diagnostic radiography in Dublin. *Radiography* 10:15–21, 2004
27. Beckmann J, Lüring C, Tingart M, Aders S, Grifka J, Köck FX: Cup positioning in THA: current status and pitfalls. A systematic evaluation of the literature. *Arch Orthop Trauma Surg* 1–10, 2008 doi:10.1007/s00402-008-0686-7
28. Lin F, Lim D, Wixson RL, Milos S, Hendrix RW, Makhosou M: Validation of a computer navigation system and a CT method for determination of the orientation of implanted acetabular cup in total hip arthroplasty: a cadaver study. *Clin Biomech* 23:1004–1011, 2008
29. Langlotz U, Grutzner PA, Bernsmann K, et al: Accuracy considerations in navigated cup placement for total hip arthroplasty. *Proc Inst Mech Eng [H]* 221:739–753, 2007
30. Zheng G: Statistically deformable 2D/3D registration for accurate determination of post-operative cup orientation from single standard X-ray radiograph. Proceedings of the 12th International Conference on Medical Image Computing and Computer-assisted Intervention (MICCAI 2009). Springer, 2009 (accepted)
31. Zheng G, Gonzalez Ballester MA, Styner MA, Nolte L-P: Reconstruction of patient-specific 3D bone surface from 2D calibrated fluoroscopic images and point distribution model. Proceedings of the 9th International Conference on Medical Image Computing and Computer-Assisted Intervention (MICCAI 2006), vol I, LNCS 4190, 2006, pp 25–32
32. Steppacher S, Moritz T, Zheng G, Zhang X, Kowal J, Suzanne A, Klaus S, Stephen M: Validation of a new method for determination of cup orientation in THA. *J Orthop Res*, 2009 (in press). doi:10.1002/jor.20929