Anteverting Periacetabular Osteotomy for Symptomatic Acetabular Retroversion

Results at Ten Years

Klaus A. Siebenrock, MD, Claudio Schaller, MD, Moritz Tannast, MD, Marius Keel, MD, and Lorenz Büchler, MD

Investigation performed at the Department of Orthopedic Surgery, Inselspital Bern, University of Bern, Bern, Switzerland

Background: Acetabular retroversion is associated with pincer-type femoroacetabular impingement and can lead to hip osteoarthritis. We report the ten-year results of a previously described patient cohort that had corrective periacetabular osteotomy for the treatment of symptomatic acetabular retroversion.

Methods: Clinical and radiographic parameters were assessed preoperatively and at two and ten years postoperatively. A Kaplan-Meier survivorship analysis of the twenty-two patients (twenty-nine hips) with a mean follow-up (and standard deviation) of 11 ± 1 years (range, nine to twelve years) was performed. In addition, a univariate Cox regression analysis was done with conversion to total hip arthroplasty as the primary end point and progression of the osteoarthritis, a fair or poor result according to the Merle d'Aubigné score, or the need for revision surgery as the secondary end points.

Results: The mean Merle d'Aubigné score improved significantly from 14 ± 1.4 points (range, 12 to 17 points) preoperatively to 16.9 ± 0.9 points (range, 15 to 18 points) at ten years ($p < 0.001$). There were also significant improvements with regard to hip flexion ($p = 0.003$), internal rotation ($p = 0.003$), and adduction ($p = 0.002$) compared with the preoperative status. No significant increase of the mean Tönnis osteoarthritis score was seen at ten years ($p = 0.06$). The cumulative ten-year survivorship, with conversion to a total hip arthroplasty as the primary end point, was 100%. The cumulative ten-year survivorship in achievement of one of the secondary end points was 71% (95% confidence interval, 54% to 88%). Predictors for poor outcome were the lack of femoral offset creation and overcorrection of the acetabular version resulting in excessive anteversion.

Conclusions: Anteverting periacetabular osteotomy for acetabular retroversion leads to favorable long-term results with preservation of the native hip at a mean of ten years. Overcorrection resulting in excessive anteversion of the hip and omitting concomitant offset creation of the femoral head-neck junction are associated with an unfavorable outcome.

Level of Evidence: Therapeutic Level IV. See instructions for Authors for a complete description of levels of evidence.

Peer Review: This article was reviewed by the Editor-in-Chief and one Deputy Editor, and it underwent blinded review by two or more outside experts. It was also reviewed by an expert in methodology and statistics. The Deputy Editor reviewed each revision of the article, and it underwent a final review by the Editor-in-Chief prior to publication. Final corrections and clarifications occurred during one or more exchanges between the author(s) and copyeditors.

Pincer-type femoroacetabular impingement, defined as acetabular overcoverage of the femoral head that leads to an early pathological contact between the prominent acetabular rim and the femoral neck, is an established cause of hip pain and osteoarthritis[1-3]. Acetabular retroversion is an acetabular morphology that leads to pincer-type femoroacetabular impingement[2-5]. It is defined on radiographs by positive cross-over[4-6], posterior wall[4], and ischial spine signs[7,8] (see Appendix). There is increasing evidence that acetabular retroversion is the result of an externally rotated hemipelvis rather than a local osseous protuberance of the acetabulum[7-12]. The logical surgical treatment of a retroverted acetabulum should consist of an anteverting reorientation of the acetabulum by a periacetabular osteotomy[13-15] (see Appendix). A previous report of the early

Disclosure: None of the authors received payments or services, either directly or indirectly (i.e., via his or her institution), from a third party in support of any aspect of this work. One or more of the authors, or his or her institution, has had a financial relationship, in the thirty-six months prior to submission of this work, with an entity in the biomedical arena that could be perceived to influence or have the potential to influence what is written in this work. No author has had any other relationships, or has engaged in any other activities, that could be perceived to influence or have the potential to influence what is written in this work. The complete **Disclosures of Potential Conflicts of Interest** submitted by authors are always provided with the online version of the article.

TABLE I Demographic Data on the Patients

Parameter	Value
Total no. of patients (hips)	22 (29)
Bilateral involvement *(% of hips)*	24
Male patients *(% of hips)*	66
Age* *(yr)*	23 ± 8 (14-41)
Height* *(cm)*	174 ± 6 (163-181)
Weight* *(kg)*	66 ± 7 (54-74)
Body mass index* *(kg/m²)*	22 ± 2 (18-24)
Previous surgery *(% of hips)*	7†
Duration of symptoms* *(mo)*	17 ± 7 (6-24)
Concomitant offset correction *(% of hips)*	83
Os acetabuli *(% of hips)*	7
Signal alteration of labrum on preop. MRA scan *(% of hips)*	86
Signal alteration of joint cartilage on preop. MRA scan *(% of hips)*	24

*The values of continuous parameters are expressed as the mean and the standard deviation, with the 95% confidence interval in parentheses.
†One hip had had an intertrochanteric varus osteotomy, and one had had surgical hip dislocation with offset creation.

results of this technique showed a significant improvement of symptoms and hip function[15]. However, to date, no long-term follow-up exists as far as we know.

We asked the following questions: (1) Will the clinical measurements (Merle d'Aubigné score, range of motion, and impingement test) improve in the long-term follow-up? (2) Will the radiographic measures (Tönnis grade of osteoarthritis and morphological hip parameters) be maintained over time? (3) What is the cumulative mean ten-year survivorship of the hip after anteverting periacetabular osteotomy for symptomatic acetabular retroversion? (4) What are the predictors for a poor outcome or revision surgery?

Materials and Methods

A retrospective follow-up study of twenty-two consecutive patients (twenty-nine hips) who had an anteverting periacetabular osteotomy from April 1997 to August 1999 was performed. This report is a follow-up of a previous report on the two-year results of the same patient cohort published in this journal[15]. The indications for surgery were (1) clinical findings of femoroacetabular impingement (i.e., hip pain), (2) reproducibility of these symptoms with the impingement test (100% had a positive test), (3) radiographic evidence of acetabular retroversion, and (4) chondrolabral damage seen on a magnetic resonance arthrography (MRA) scan (twenty-four of twenty-nine hips). We evaluated the patients clinically and radiographically ten years postoperatively. These results were then compared with the preoperative and two-year follow-up status, and the initial data were tested for negative predictive factors. This study was approved by the local institutional review board.

Patients

The procedure was performed in twenty-nine hips in twenty-two consecutive patients (Table I). There were no exclusion criteria. The mean age (and standard deviation) of the patients at the time of surgery was 23 ± 8 years (range, fourteen to forty-one years). There were thirteen male (nineteen hips; 66%) and nine female patients (ten hips; 34%). Two hips (7%) had previous surgery. One hip had undergone an intertrochanteric varus osteotomy, and one hip had a surgical hip dislocation with femoral head-neck osteochondroplasty. One patient (one hip; 3%) had Sprengel deformity with macrocephaly. All other patients were otherwise healthy. The diagnosis of femoroacetabular impingement and the indication for surgical treatment were based on a positive correlation among symptoms (typically groin pain), physical findings on examination (in particular, reproducible pain in flexion and internal rotation of the hip), findings of acetabular retroversion on radiographs, and evidence of chondrolabral lesions on MRA scans in twenty-four hips. In the remaining five hips, the patients had a previous MRA scan and corrective periacetabular osteotomy on the contralateral side for acetabular retroversion.

Follow-up Evaluation

No patient was lost to follow-up. The mean duration of follow-up was 11 ± 1 years (range, nine to twelve years). Eighteen patients (twenty-five hips; 86%) were evaluated both clinically and radiographically. Two patients (two hips; 7%) were evaluated on a clinical basis only. They declined a follow-up radiograph because they were pain-free (each had a Merle d'Aubigné score of 18 points). Two patients (two hips; 7%) declined both a clinical and radiographic follow-up and were evaluated by means of a telephone interview only. Since their last follow-up examination two years postoperatively, both had been entirely asymptomatic and neither had further hip surgery.

Clinical Evaluation

The twenty patients (twenty-seven hips) were assessed at the last follow-up evaluation with use of the Merle d'Aubigné and Postel scoring system[16]. According to the Merle d'Aubigné system, a result was considered poor when the score was <12 points; fair when it was 12 to 14 points; good when it was 15, 16, or 17 points; and excellent when it was 18 points. The anterior impingement test (painful flexion and internal rotation of the hip) was assessed. In addition, the full goniometric range of motion and gait were analyzed. All parameters were documented preoperatively and at two and ten years postoperatively (Table II).

Radiographic Evaluation

Routine radiographic evaluation consisted of a preoperative anteroposterior pelvic radiograph and a false-profile view. The anteroposterior pelvic radiograph was made with the patient in the supine position with a standardized technique described earlier[5,6]. All but five hips had a preoperative MRA scan of the hip with intra-articular injection of gadolinium for evaluation of lesions of

TABLE II Clinical Results

Parameter	Preop.	Two-Year Postop.	Ten-Year Postop.
Merle d'Aubigné score[16]* *(points)*	14.0 ± 1.4 (12-17)	16.9 ± 0.9 (15-18)†	16.6 ± 1.2 (14-18)†
Positive anterior impingement test *(% of hips)*	100	24†	17†
Range of motion* *(deg)*			
Flexion	99 ± 9 (90-110)	106 ± 8 (90-120)†	106 ± 9 (90-124)†
Internal rotation in 90° of flexion	11 ± 9 (0-26)	21 ± 10 (5-40)†	20 ± 10 (0-34)†
External rotation in 90° of flexion	33 ± 17 (14-70)	35 ± 15 (15-61)	31 ± 10 (12-47)
Abduction	35 ± 10 (14-47)	34 ± 7 (20-40)	27 ± 8 (18-42)†‡
Adduction	22 ± 9 (10-37)	30 ± 4 (24-36)†	22 ± 10 (1-45)‡

*The values are expressed as the mean and the standard deviation, with the 95% confidence interval in parentheses. †Compared with the preoperative status, the difference was significant ($p < 0.05$). ‡The difference between the two and ten-year results was significant ($p < 0.05$).

the cartilage and labrum. The preoperative MRA scan showed labral alterations in all but one patient. Thirteen hips showed degeneration of the labrum, including ganglion formation in two and a labral tear in ten hips. In addition, twelve hips showed thinning or signal alterations of the adjacent articular cartilage. In one hip, no specific labral or chondral abnormalities were detected. At each follow-up evaluation, an anteroposterior pelvic radiograph and a cross-table lateral radiograph of the proximal part of the femur were made. In order to describe the preoperative and postoperative morphologic features of the acetabulum and the femoral head, thirteen standard radiographic parameters (see Appendix) were assessed by one observer using previously developed and validated computer software (Hip2Norm; University of Bern, Bern, Switzerland)[17-19]. Postoperative radiographic parameters were compared with previously defined normal radiographic values of the acetabulum[20]. Evidence of osteoarthritis of the hip prior to surgery and progression during follow-up were graded according to the classification system of Tönnis et al.[21]. Heterotopic ossifications were graded according to the system of Brooker et al.[22].

Statistical Analysis

We tested normal distribution of all continuous parameters with the Kolmogorov-Smirnov test. The paired Student t test was used for comparison of normally distributed data. The Wilcoxon rank-sum test was used to compare data without normal distribution. Differences between categorical variables were analyzed with the Fisher exact test.

A survivorship analysis was performed according to the Kaplan-Meier method[23]. The primary end point was defined as conversion to total hip arthroplasty. The secondary end points were (1) radiographic progression of the osteoarthritis, (2) a fair or poor score (≤14 points) according to the Merle d'Aubigné system at the latest follow-up evaluation, or (3) any reoperation related to correction of acetabular coverage or persistent impingement. The univariate Cox proportional-hazards model was used to detect factors predicting primary and secondary end points and to calculate the corresponding hazard ratios. Hazard ratios were calculated with the 95% confidence interval (CI).

Source of Funding

One author (M.T.) received funding from the Swiss National Science Foundation. This funding source played no role in study design, data collection, analysis, interpretation, writing, or submission of the manuscript.

Results

Clinical Outcome

At a mean of ten years, the Merle d'Aubigné score had improved significantly compared with the preoperative value

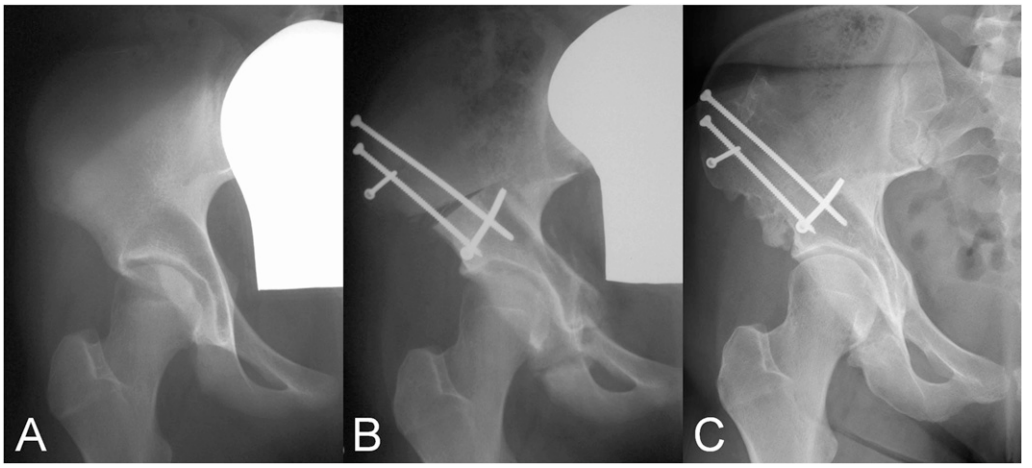

Fig. 1

Figs. 1-A, 1-B, and 1-C A sixteen-year-old female patient with acetabular retroversion. **Fig. 1-A** The preoperative anteroposterior radiograph showing positive crossover[4], posterior wall[4], and ischial spine signs[7,8]. **Fig. 1-B** The postoperative radiograph made after the anteverting periacetabular osteotomy. **Fig. 1-C** At the ten-year follow-up, the Merle d'Aubigné score was 18 points (excellent) without evidence of osteoarthritis.

($p < 0.001$; Table II). There was no significant difference in the Merle d'Aubigné score at two or ten years postoperatively ($p = 0.093$). Of the twenty-seven hips in twenty patients available for clinical follow-up, six (22%) had an excellent result according to the Merle d'Aubigné score (Fig. 1); nineteen (70%), a good result; and two (7%), a fair result. The prevalence of a positive anterior impingement test decreased significantly at the ten-year follow-up compared with the preoperative status ($p < 0.001$; Table II). A significant increase in flexion ($p = 0.003$), internal rotation ($p = 0.003$), and adduction ($p = 0.002$) was seen at the ten-year follow-up compared with the preoperative status. Comparison of the two and ten-year follow-up results showed a significant decrease in abduction ($p = 0.015$) and adduction ($p < 0.001$) (Table II).

Radiographic Outcome

In comparison with the preoperative status, there was a significant increase in the lateral center-edge angle ($p = 0.023$), the superior coverage ($p < 0.001$), and the posterior coverage ($p < 0.001$) (see Appendix). A significant decrease was observed for the postoperative extrusion index ($p = 0.016$), the presence of the crossover sign ($p < 0.001$), the retroversion index ($p < 0.001$), the posterior wall sign ($p < 0.001$), the Sharp angle ($p = 0.001$), and the total anterior coverage ($p < 0.001$). Although four hips progressed from a Tönnis osteoarthritis score of 0 to 1 at ten years, the overall progression of osteoarthritis was not significant ($p = 0.06$; see Appendix). Heterotopic ossifications were seen in fourteen hips in thirteen patients (six hips had grade-1; four, grade-2; and four, grade-3 ossifications). Of those, four hips were rated as having reached an end point. One of the four had grade-1 ossifications, a fair result according to the Merle d'Aubigné system, and progression of arthritis. Two hips with grade-2 ossifications had either evidence of radiographic progression of osteoarthritis or a fair result in the Merle d'Aubigné system. One patient with grade-3 heterotopic ossification underwent excision of the ossifications during revision surgical dislocation of the hip for treatment of a persistent cam-type femoroacetabular impingement.

Survivorship Analysis

No hip had a conversion to total hip arthroplasty. Eight hips (28%) reached at least one secondary end point. Two of the eight hips had radiographic progression of osteoarthritis. Two had radiographic osteoarthritis and a fair or poor Merle d'Aubigné score. Four patients (four hips; 14%) underwent a reoperation related to newly developed posterior impingement (two hips), persistent anterior impingement (one hip), or loss of correction (one hip). The cumulative ten-year survivorship for the primary and secondary end points was 100% and 71% (95% CI, 54% to 88%), respectively.

Among the four reoperations, one patient presented with recurrent symptoms of anterior femoroacetabular impingement at 2.5 years postoperatively. Despite an arthrotomy and offset correction at the time of periacetabular osteotomy, this patient needed subsequent surgical hip dislocation with osteochondroplasty of the femoral head-neck junction (the Merle d'Aubigné score was 18 points at ten years; see Appendix). One patient with excessive acetabular anteversion and clinical signs of posteroinferior femoroacetabular impingement underwent trimming of the posterior acetabular wall through a surgical hip dislocation 1.6 years postoperatively (a Merle d'Aubigné score of 17 points at ten years; Fig. 2). The third patient had both persistent cam-type femoroacetabular impingement and acetabular overcorrection with resulting posterior femoroacetabular

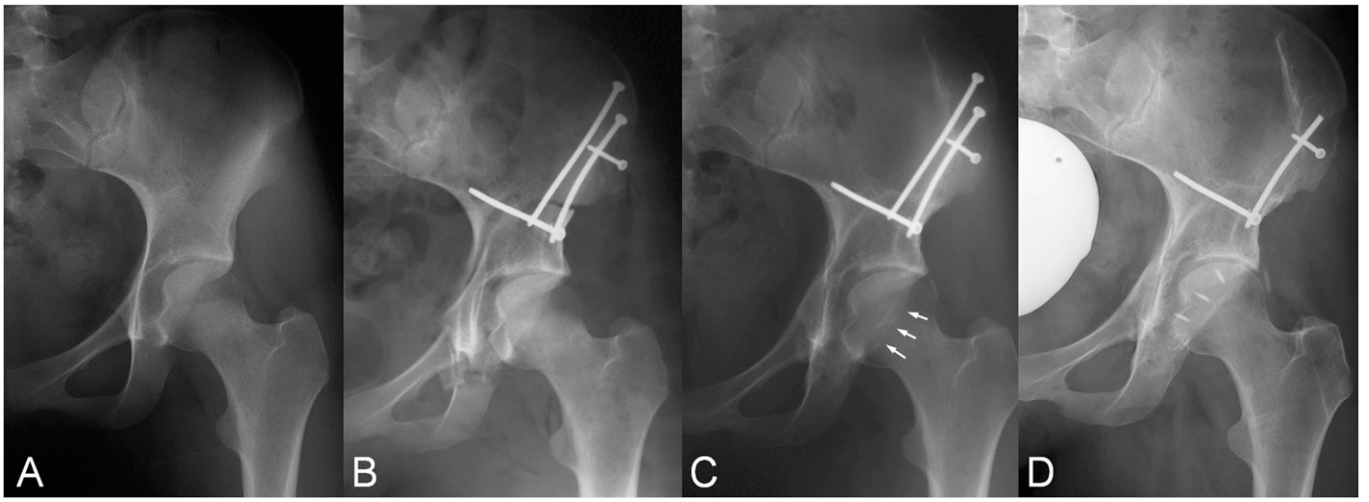

Fig. 2

Figs. 2-A through 2-D An eighteen-year-old female patient with symptomatic acetabular retroversion. **Fig. 2-A** Preoperative radiograph. **Fig. 2-B** Radiograph made after the anteverting periacetabular osteotomy. **Fig. 2-C** Four years postoperatively, the patient reported posterior hip pain. Radiograph made at that time shows a relatively prominent posterior wall with development of a double contour (arrows) as a sign of posterior impingement. **Fig. 2-D** Radiograph showing the final result after the patient subsequently underwent surgical hip dislocation with trimming of the posterior wall and partial screw removal one year later.

TABLE III Comparison of Clinical Results at a Mean Follow-up of at Least Two Years After Different Treatments for Femoroacetabular Impingement

Study	Mean Follow-up Period (Range) *(yr)*	Type of Impingement	No. of Patients (Hips)	Type of Surgery	Scoring Systems*	Results	Survivorship Rate†)
Siebenrock et al.[15] (2003)	2.5 (2-4)	Retroversion	22 (29)	Periacetabular osteotomy	Merle d'Aubigné	26 hips (90%) were graded good to excellent; 3 hips had subsequent surgery	100%
Tannast and Siebenrock[31] (2010)	5.1 (2-7.1)	Mixed	100 (108)	Surgical hip dislocation	Merle d'Aubigné	91% had good to excellent results, depending on preop. osteoarthritis	91%
Steppacher et al.[30] (2014)	6.0 (5-7)	Mixed	75 (97)	Surgical hip dislocation	Merle d'Aubigné	91% had good to excellent clinical results without progression of osteoarthritis	92%
Beck et al.[1] (2004)	4.7 (4-5.2)	Mixed	19 (19)	Surgical hip dislocation	Merle d'Aubigné	9 hips (47%) were graded good to excellent; mean osteoarthritis grade remained unchanged	74%
Murphy et al.[32] (2004)	5.2 (2.0-12.0)	Mixed	23 (23)	Surgical hip dislocation	Merle d'Aubigné	Hips at risk for failure showed advanced preop. osteoarthritis	70%
Peters et al.[38] (2010)	2.2 (1.5-8.0)	Mixed	94 (96)	Surgical hip dislocation	Harris hip score	1 hip had a worse score at the time of follow-up; failures showed advanced preop. osteoarthritis	94%
Naal et al.[39] (2011)	3.8 (1.0-6.6)	Mixed	22 (30)	Surgical hip dislocation	Hip outcome score, SF-12, and UCLA	At time of follow-up, 96% were still competing professionally	100%
Naal et al.[33] (2012)	5.0 (2.0-10.0)	Mixed	185 (233)	Surgical hip dislocation	WOMAC, hip outcome score, SF-12, and UCLA	83% showed good to excellent clinical result at time of follow-up; major revisions in 6%	97%
Chiron et al.[40] (2012)	2.2 (1.0-4.5)	Mixed	106 (118)	Mini-open	Nonarthritic hip score and Harris hip score	18 hips (15%) showed progression of osteoarthritis by 1 point according to Tönnis	97%
Lincoln et al.[41] (2009)	2.0 (1.3-3.0)	Cam	14 (16)	Mini-open with hip arthroscopy	Harris hip score	Improved mean score; no radiographic progression of osteoarthritis	100%
Laude et al.[42] (2009)	2.5 (0.5-4.5)	Mixed	97 (100)	Mini-open with hip arthroscopy	Nonarthritic hip score	Best results in patients <40 yr old without preop. signs of osteoarthritis	89%
Ilizaliturri et al.[43] (2008)	2.4 (2.0-3.0)	Cam	19 (19)	Hip arthroscopy	WOMAC	16 hips (84%) showed an improved score; 3 hips (16%) deteriorated	95%
Brunner et al.[44] (2009)	2.4 (2.0-3.2)	Mixed	53 (53)	Hip arthroscopy	Nonarthritic hip score and sports frequency score	58% returned to their full accustomed level of activity	100%

continued

TABLE III (*continued*)

Study	Mean Follow-up Period (Range) *(yr)*	Type of Impingement	No. of Patients (Hips)	Type of Surgery	Scoring Systems*	Results	Survivorship Rate†)
Philippon et al.[45] (2009)	2.3 (2-2.9)	Mixed	112 (112)	Hip arthroscopy	Harris hip score	Predictors for better outcome were the preop. score, signs of osteoarthritis, and labral repair	92%
Philippon et al.[46] (2010)	2.0 (1.0-3.5)	Cam	28 (28)	Hip arthroscopy	Modified Harris hip score	Arthroscopic treatment of femoroacetabular impingement with labral repair allowed professional hockey players a prompt return to sport; 2 patients (7%) had reinjury and additional hip arthroscopy	100%
Byrd and Jones[47] (2011)	2	Mixed	100 (100)	Hip arthroscopy	Harris hip score	79% showed good to excellent results	100%
Palmer et al.[48] (2012)	3.8	Cam	185 (201)	Hip arthroscopy	Nonarthritic hip score	Clinical score, pain score, and satisfaction level significantly improved; risk for conversion to total hip arthroplasty was advanced preop. osteoarthritis	94%

*SF-12 = Short Form-12, WOMAC = Western Ontario and McMaster Universities Osteoarthritis Index, and UCLA = University of California Los Angeles activity score.
†Conversion to total hip arthroplasty was the end point.

impingement. The cam-type femoroacetabular impingement was not recognized at the time of the initial surgery because no intraoperative arthrotomy was performed. This was corrected 4.4 years after the index operation with a surgical dislocation of the hip. After subsequent arthroscopic resection of intra-articular adhesions and implant removal three years later, a posterior impingement developed because of the relative posterior acetabular overcoverage. Eventually, a trimming of the posterior wall was necessary 10.5 years after the index operation (the Merle d'Aubigné score was 13 points at twelve years). The fourth patient presented with partial loss of correction at the first follow-up visit, needing revision periacetabular osteotomy eight weeks postoperatively.

Fifteen patients had been operatively treated on one side only, and the asymptomatic, contralateral side was not included in the systematic analysis of this study. However, follow-up information revealed that the asymptomatic, contralateral hip in one patient had progressed to Tönnis grade-1 osteoarthritis and the contralateral hip in two patients had a total hip arthroplasty.

Predictive Factors

A Cox regression analysis was performed on the basis of the following end points: (1) conversion to total hip arthroplasty, (2) radiographic progression of the osteoarthritis, (3) a fair or poor Merle d'Aubigné score (≤14 points), or (4) any reoperation related to correction of acetabular coverage or persistent impingement.

Three univariate predictors for the above-defined end points were identified: (1) the lack of offset correction at the time of periacetabular osteotomy (hazard ratio [HR], 11.0; 95% CI, 10.0 to 12.1; $p = 0.021$), (2) deficient anterior coverage of the acetabulum postoperatively (HR, 4.5; 95% CI, 3.7 to 5.2; $p = 0.045$), and (3) excessive posterior acetabular coverage (>55%)[19] of the acetabulum postoperatively (HR, 4.2; 95% CI, 3.5 to 5.0; $p = 0.048$).

Discussion

The goal of this study was to report the mean ten-year outcome of the first twenty-nine hips treated with an anteverting periacetabular osteotomy for symptomatic acetabular retroversion at our institute. After a mean of eleven years, the rate of conversion to a total hip arthroplasty, the clinical and radiographic outcome, and the need for further revision surgery were analyzed. The previously reported good clinical outcome after two years was maintained at ten years. There was a trend toward radiographic progression of osteoarthritis. Overcorrection of the acetabulum and lack of femoral head-neck offset correction were associated with a less favorable outcome.

The study has limitations. One limitation is the lack of a comparative group with no treatment. We are therefore not able to show that the natural history of symptomatic acetabular retroversion can be potentially changed. However, an increasing number of recent publications have suggested that acetabular retroversion is a risk factor for hip pain and osteoarthritis[2-4]. Our results suggest that, in such patients, an anteverting periacetabular osteotomy improves the clinical scores at ten years of follow-up without significant progression of osteoarthritis. Another limitation is the lack of a comparative group with acetabular rim trimming instead of an acetabular reorientation procedure in patients with the same pathomorphology. Such a comparative group does not exist in our database because of the understanding of the pathology at the time of surgery (more than ten years ago). The indication to perform a periacetabular osteotomy instead of acetabular rim trimming was consistently based on a substantially retroverted acetabulum as well as a deficient posterior wall in twenty-four of twenty-nine hips. Trimming of the anterior acetabular rim in those hips would have reduced the lunate surface, potentially resulting in a dysplastic hip.

Thirty-two percent of the patients in our series underwent bilateral anteverting periacetabular osteotomy. Generally, this raises the question of whether a patient-based instead of a joint-based statistical approach would be more appropriate[24,25]. We chose a joint-based approach for statistical analysis for the following reasons. First, we analyze the individual morphology of each joint separately. This implies certain side-specific variations. Second, the postoperative surgical correction has to be judged individually for a hip. Third, none of the negative predictive factors are general factors that simultaneously apply for both hips.

There is increasing evidence that acetabular retroversion represents a malorientation rather than excessive anterior and deficient posterior femoral head coverage[4,7,12]. As in hip dysplasia[9], a redirectional osteotomy of the acetabulum more reliably restores or approaches normal anatomy in hips with substantial retroversion. The cutoff between hips with a low retroversion index, which could be treated by a trimming of the anterosuperior portion of the rim, and hips with a higher retroversion index requiring a periacetabular osteotomy still remains unclear. As a rough guideline, we propose that an acetabular retroversion index[11,15,26] of ≥30% together with posterior wall and ischial spine signs in young patients are an indication for acetabular reorientation rather than trimming of the rim.

To our knowledge, there are no comparable follow-up data about anteverting pelvic osteotomies for acetabular retroversion. Comparing our results with reported data about acetabular rim trimming in mixed or pincer-type femoroacetabular impingement is difficult. There is a large heterogeneity in reporting data, applied surgical techniques, and identification of distinct impingement subtypes (Table III). Some studies have noted an excellent survivorship of the hip but with a substantially shorter follow-up period[27-29]. For studies with a mean follow-up of at least five years[30-33] after rim trimming through a surgical hip dislocation, the survivorship of the hips was reported to range from 70% to 97%. These numbers are considerably lower than our results. One possible explanation might be that the lunate surface with acetabular reorientation is preserved. With rim trimming, the joint contact area can be critically reduced, leading to increased abnormal loading of the remaining cartilage and potentially to earlier failures[30,34].

The 14% revision rate in our series is relatively high. We attribute this to difficulties and the learning curve in finding the optimal acetabular orientation similar to previous experiences for acetabular reorientation in hip dysplasia[35,36]. Three of the four revisions were related to a persistent femoroacetabular impingement. Of those three hips, two developed a posterior impingement due to a newly created posterior overcoverage and one had persistent anterior impingement. The posterior impingement was successfully addressed with posterior rim trimming, while the anterior impingement was relieved with open femoral neck osteochondroplasty. Thus, in hips with normal-appearing posterior coverage indicated by a posterior rim outline lateral to the center of rotation (an absent posterior wall sign), we prefer to perform a rim trimming rather than a corrective periacetabular osteotomy. A recent study has shown that high femoral anteversion combined with a high neck-shaft angle promotes posterior hip impingement[37]. Thus, femoral anteversion is routinely measured preoperatively in our institute. In combination with acetabular retroversion, it should lead to the consideration of decreasing femoral anteversion by a femoral osteotomy or by choosing anterior rim trimming in hips with a rather normal-appearing posterior coverage. Restoration of a physiological femoral head-neck offset and avoidance of an excessive acetabular anteversion were crucial factors for success when an anteverting periacetabular osteotomy was performed for acetabular retroversion.

Appendix

eA Figures demonstrating typical radiographic signs of acetabular retroversion, an illustration of an anteverting periacetabular osteotomy, and radiographs of a patient with symptomatic acetabular retroversion and a cam-type deformity that was treated with an anteverting periacetabular osteotomy; a table comparing preoperative and postoperative radiographic parameters; and a description of the surgical technique used to perform an anteverting reorientation of the acetabulum with a periacetabular osteotomy are available with the online version of this article as a data supplement at jbjs.org. ■

Klaus A. Siebenrock, MD
Claudio Schaller, MD
Moritz Tannast, MD
Marius Keel, MD
Lorenz Büchler, MD
Department of Orthopedic Surgery,
Inselspital Bern,
University of Bern,
3010 Bern, Switzerland.
E-mail address for K.A. Siebenrock: klaus.siebenrock@insel.ch

References

1. Beck M, Leunig M, Parvizi J, Boutier V, Wyss D, Ganz R. Anterior femoroacetabular impingement: part II. Midterm results of surgical treatment. Clin Orthop Relat Res. 2004 Jan;(418):67-73.

2. Ganz R, Parvizi J, Beck M, Leunig M, Nötzli H, Siebenrock KA. Femoroacetabular impingement: a cause for osteoarthritis of the hip. Clin Orthop Relat Res. 2003 Dec;(417):112-20.

3. Giori NJ, Trousdale RT. Acetabular retroversion is associated with osteoarthritis of the hip. Clin Orthop Relat Res. 2003 Dec;(417):263-9.

4. Reynolds D, Lucas J, Klaue K. Retroversion of the acetabulum. A cause of hip pain. J Bone Joint Surg Br. 1999 Mar;81(2):281-8.

5. Tannast M, Siebenrock KA, Anderson SE. Femoroacetabular impingement: radiographic diagnosis—what the radiologist should know. AJR Am J Roentgenol. 2007 Jun;188(6):1540-52.

6. Siebenrock KA, Kalbermatten DF, Ganz R. Effect of pelvic tilt on acetabular retroversion: a study of pelves from cadavers. Clin Orthop Relat Res. 2003 Feb;(407):241-8.

7. Kalberer F, Sierra RJ, Madan SS, Ganz R, Leunig M. Ischial spine projection into the pelvis : a new sign for acetabular retroversion. Clin Orthop Relat Res. 2008 Mar;466(3):677-83. Epub 2008 Feb 10.

8. Kakaty DK, Fischer AF, Hosalkar HS, Siebenrock KA, Tannast M. The ischial spine sign: does pelvic tilt and rotation matter? Clin Orthop Relat Res. 2010 Mar;468(3):769-74. Epub 2009 Aug 7.

9. Fujii M, Nakashima Y, Sato T, Akiyama M, Iwamoto Y. Pelvic deformity influences acetabular version and coverage in hip dysplasia. Clin Orthop Relat Res. 2011 Jun;469(6):1735-42. Epub 2011 Jan 4.

10. Jamali AA, Mladenov K, Meyer DC, Martinez A, Beck M, Ganz R, Leunig M. Anteroposterior pelvic radiographs to assess acetabular retroversion: high validity of the ''cross-over-sign''. J Orthop Res. 2007 Jun;25(6):758-65.

11. Köhnlein W, Ganz R, Impellizzeri FM, Leunig M. Acetabular morphology: implications for joint-preserving surgery. Clin Orthop Relat Res. 2009 Mar;467(3):682-91. Epub 2009 Jan 8.

12. Tannast M, Pfannebecker P, Schwab JM, Albers CE, Siebenrock KA, Büchler L. Pelvic morphology differs in rotation and obliquity between developmental dysplasia of the hip and retroversion. Clin Orthop Relat Res. 2012 Dec;470(12):3297-305.

13. Ganz R, Klaue K, Vinh TS, Mast JW. A new periacetabular osteotomy for the treatment of hip dysplasias. Technique and preliminary results. Clin Orthop Relat Res. 1988 Jul;(232):26-36.

14. Siebenrock KA, Schöll E, Lottenbach M, Ganz R. Bernese periacetabular osteotomy. Clin Orthop Relat Res. 1999 Jun;(363):9-20.

15. Siebenrock KA, Schoeniger R, Ganz R. Anterior femoro-acetabular impingement due to acetabular retroversion. Treatment with periacetabular osteotomy. J Bone Joint Surg Am. 2003 Feb;85(2):278-86.

16. Merle d'Aubigné R, Postel M. Functional results of hip arthroplasty with acrylic prosthesis. J Bone Joint Surg Am. 1954;35:451-75.

17. Tannast M, Zheng G, Anderegg C, Burckhardt K, Langlotz F, Ganz R, Siebenrock KA. Tilt and rotation correction of acetabular version on pelvic radiographs. Clin Orthop Relat Res. 2005 Sep;438:182-90.

18. Tannast M, Mistry S, Steppacher SD, Reichenbach S, Langlotz F, Siebenrock KA, Zheng G. Radiographic analysis of femoroacetabular impingement with Hip2Norm-reliable and validated. J Orthop Res. 2008 Sep;26(9):1199-205.

19. Tannast M, Mistry S, Steppacher SD, Reichenbach S, Siebenroc KA, Zheng G. A comprehensive validation of a new method for correction of radiographic hip parameters for pelvic malpositioning. J Bone Joint Surg Br. 2009 Sep 1;91 (SUPP III):451.

20. Tannast M, Albers CE, Steppacher SD, Siebenrock KA. Hip pain in the young adult. In: Bentley G, editor. European Instructional Lectures. Berlin, Germany: Springer; 2011. pp 141-54.

21. Tönnis D. General radiography of the hip joint. In: Tönnis D, editor. Congenital dysplasia and dislocations of the hip in children and adults. Heidelberg: Springer; 1987. pp 100-42.

22. Brooker AF, Bowerman JW, Robinson RA, Riley LHJ Jr. Ectopic ossification following total hip replacement. Incidence and a method of classification. J Bone Joint Surg Am. 1973 Dec;55(8):1629-32.

23. Kaplan EL, Meier P. Nonparametric estimation from incomplete observations. J Am Statist Assn. 1958;53:457-81.

24. Park MS, Kim SJ, Chung CY, Choi IH, Lee SH, Lee KM. Statistical consideration for bilateral cases in orthopaedic research. J Bone Joint Surg Am. 2010 Jul 21;92(8):1732-7.

25. Zhang Y, Glynn RJ, Felson DT. Musculoskeletal disease research: should we analyze the joint or the person? J Rheumatol. 1996 Jul;23(7):1130-4.

26. Nötzli HP, Wyss TF, Stoecklin CH, Schmid MR, Treiber K, Hodler J. The contour of the femoral head-neck junction as a predictor for the risk of anterior impingement. J Bone Joint Surg Br. 2002 May;84(4):556-60.

27. Bardakos NV, Vasconcelos JC, Villar RN. Early outcome of hip arthroscopy for femoroacetabular impingement: the role of femoral osteoplasty in symptomatic improvement. J Bone Joint Surg Br. 2008 Dec;90(12):1570-5.

28. Larson CM, Giveans MR. Arthroscopic management of femoroacetabular impingement: early outcomes measures. Arthroscopy. 2008 May;24(5):540-6. Epub 2008 Jan 7.

29. Singh PJ, O'Donnell JM. The outcome of hip arthroscopy in Australian football league players: a review of 27 hips. Arthroscopy. 2010 Jun;26(6):743-9. Epub 2010 Mar 31.

30. Steppacher SD, Huemmer C, Schwab JM, Tannast M, Siebenrock KA. Surgical hip dislocation for treatment of femoroacetabular impingement: factors predicting 5-year survivorship. Clin Orthop Relat Res. 2014 Jan;472(1):337-48. Epub 2013 Sep 8.

31. Tannast M, Siebenrock KA. [Open therapy of femoroacetabular impingement] [German]. Oper Orthop Traumatol. 2010 Mar;22(1):3-16.

32. Murphy S, Tannast M, Kim YJ, Buly R, Millis MB. Debridement of the adult hip for femoroacetabular impingement: indications and preliminary clinical results. Clin Orthop Relat Res. 2004 Dec;(429):178-81.

33. Naal FD, Miozzari HH, Schär M, Hesper T, Nötzli HP. Midterm results of surgical hip dislocation for the treatment of femoroacetabular impingement. Am J Sports Med. 2012 Jul;40(7):1501-10. Epub 2012 May 3.

34. Hipp JA, Sugano N, Millis MB, Murphy SB. Planning acetabular redirection osteotomies based on joint contact pressures. Clin Orthop Relat Res. 1999 Jul;(364):134-43.

35. Albers CE, Steppacher SD, Ganz R, Tannast M, Siebenrock KA. Impingement adversely affects 10-year survivorship after periacetabular osteotomy for DDH. Clin Orthop Relat Res. 2013 May;471(5):1602-14. Epub 2013 Jan 25.

36. Leunig M, Siebenrock KA, Ganz R. Rationale of periacetabular osteotomy and background work. Instr Courses Lect. 2001;50:229-38.

37. Steppacher SD, Huemmer C, Schwab JM, Tannast M, Siebenrock KA. Surgical hip dislocation for treatment of femoroacetabular impingement: factors predicting 5-year survivorship. Clin Orthop Relat Res. 2014 Jan;472(1):337-48. Epub 2013 Sep 8.

38. Peters CL, Schabel K, Anderson L, Erickson J. Open treatment of femoroacetabular impingement is associated with clinical improvement and low complication rate at short-term followup. Clin Orthop Relat Res. 2010 Feb;468(2):504-10.

39. Naal FD, Miozzari HH, Wyss TF, Nötzli HP. Surgical hip dislocation for the treatment of femoroacetabular impingement in high-level athletes. Am J Sports Med. 2011 Mar;39(3):544-50. Epub 2010 Dec 20.

40. Chiron P, Espié A, Reina N, Cavaignac E, Molinier F, Laffosse JM. Surgery for femoroacetabular impingement using a minimally invasive anterolateral approach: analysis of 118 cases at 2.2-year follow-up. Orthop Traumatol Surg Res. 2012 Feb;98(1):30-8. Epub 2012 Jan 16.

41. Lincoln M, Johnston K, Muldoon M, Santore R. Combined arthroscopic and modified open approach for cam femoroacetabular impingement: a preliminary experience. Arthroscopy. 2009 Apr;25(4):392-9.

42. Laude F, Sariali E, Nogier A. Femoroacetabular impingement treatment using arthroscopy and anterior approach. Clin Orthop Relat Res. 2009 Mar;467(3):747-52. Epub 2008 Dec 16.

43. Ilizaliturri VMJ Jr, Orozco-Rodriguez L, Acosta-Rodríguez E, Camacho-Galindo J. Arthroscopic treatment of cam-type femoroacetabular impingement: preliminary report at 2 years minimum follow-up. J Arthroplasty. 2008 Feb;23(2):226-34. Epub 2007 Oct 24.

44. Brunner A, Horisberger M, Herzog RF. Sports and recreation activity of patients with femoroacetabular impingement before and after arthroscopic osteoplasty. Am J Sports Med. 2009 May;37(5):917-22. Epub 2009 Feb 26.

45. Philippon MJ, Briggs KK, Yen YM, Kuppersmith DA. Outcomes following hip arthroscopy for femoroacetabular impingement with associated chondrolabral dysfunction: minimum two-year follow-up. J Bone Joint Surg Br. 2009 Jan;91(1):16-23.

46. Philippon MJ, Weiss DR, Kuppersmith DA, Briggs KK, Hay CJ. Arthroscopic labral repair and treatment of femoroacetabular impingement in professional hockey players. Am J Sports Med. 2010 Jan;38(1):99-104. Epub 2009 Dec 4.

47. Byrd JW, Jones KS. Arthroscopic management of femoroacetabular impingement: minimum 2-year follow-up. Arthroscopy. 2011 Oct;27(10):1379-88. Epub 2011 Aug 20.

48. Palmer DH, Ganesh V, Comfort T, Tatman P. Midterm outcomes in patients with cam femoroacetabular impingement treated arthroscopically. Arthroscopy. 2012 Nov;28(11):1671-81. Epub 2012 Sep 6.