

29. Ross J. Acute displacement of the diastolic pressure-volume curve of the left ventricle: role of the pericardium and the right ventricle. *Circulation* 1979;**59**:32–37.
30. Chang SM, Lin CC, Hsiao SH, Lee CY, Huang WC. Pulmonary hypertension and left heart function: insights from tissue Doppler imaging and myocardial performance index. *Echocardiography* 2007;**24**:366–373.
31. Yilmaz R, Gencer M, Ceylan E, Demirbag R. Impact of chronic obstructive pulmonary disease with pulmonary hypertension on both left ventricular systolic and diastolic performance. *J Am Soc Echocardiogr* 2005;**18**:873–881.
32. Gombert-Maitland M, Dufton C, Oudiz RJ, Benza RL. Compelling evidence of long-term outcomes in pulmonary arterial hypertension? A clinical perspective. *J Am Coll Cardiol* 2011;**57**:1053–1061.
33. Oudiz RJ, Galie N, Olschewski H, Torres F, Frost A, Ghofrani HA, Badesch DB, McGoon MD, McLaughlin VV, Roecker EB, Harrison BC, Despain D, Dufton C, Rubin LJ. Long-term ambrisentan therapy for the treatment of pulmonary arterial hypertension. *J Am Coll Cardiol* 2009;**54**:1971–1981.

CARDIOVASCULAR FLASHLIGHT

doi:10.1093/eurheartj/ehu425

Online publish-ahead-of-print 31 October 2014

Vacuum-assisted endovascular thrombectomy of massive inferior vena cava thrombosis

Thomas Rudolf Wyss^{1,2}, Ulrike Huegel¹, Anne Stirnimann¹, and Nils Kucher^{1*}

¹Venous Thromboembolism Research Group, Clinic for Angiology, Swiss Cardiovascular Center, Inselspital University Hospital and University of Bern, 3010 Bern, Switzerland; and ²Department of Cardiovascular Surgery, Swiss Cardiovascular Center, Inselspital University Hospital and University of Bern, Switzerland

* Corresponding author. Tel: +41 31 632 54 39, Fax: +41 31 632 43 80, Email: nils.kucher@insel.ch

This paper was guest edited by Brahmajee Nallamothu (University of Michigan; bnallamo@umich.edu)

Report

A 76-year-old woman presented with acute massive swelling of her left leg (10 cm plus in thigh circumference) and was diagnosed with iliofemoral deep vein thrombosis (DVT) extending to the infra-renal inferior vena cava (IVC; Panel A). Catheter-directed thrombolysis was effective in restoring flow in the iliofemoral veins but the free-floating thrombus in the IVC persisted. Removal of the cava thrombus was performed by vacuum-assisted thrombectomy (AngioVac, CE Mark approval, Angiodynamics, Latham, USA) using an extracorporeal veno-venous bypass system. It includes a 22-French suction cannula placed via the right common femoral vein (Panel B), a centrifugal pump console, a reservoir, a filter, and a 16-French reinfusion cannula placed via the right internal jugular vein. Two passes with the suction cannula led to successful *in toto* extraction of the thrombus (11 cm in length, Panel C). Residual common iliac vein stenosis was treated by a self-expanding nitinol stent (Panel D). Post-interventional therapy included anticoagulation therapy and lower leg graduated compression stockings.

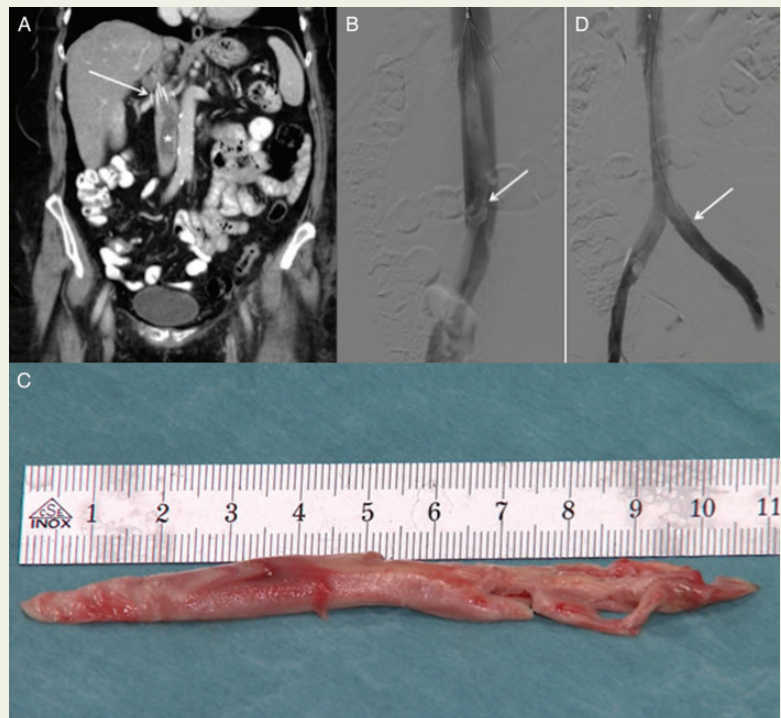
Anticoagulation therapy and compression stockings are the corner stones in the treatment of acute iliofemoral DVT. However, post-thrombotic syndrome may develop in up to 50% of conservatively treated patients. An early thrombus removal strategy may reduce the incidence of post-thrombotic syndrome. Catheter-directed thrombolysis followed by routine stenting of residual venous outflow stenosis is associated with low rates of post-thrombotic syndrome. This case report demonstrates feasibility of this novel suction catheter technique in extensive DVT, when other revascularization measures have failed (Supplementary material online, Video). Clinical studies are warranted to investigate the efficacy and safety of this promising technology.

Panel A: Coronal computed tomography image with inferior vena cava thrombus (white star) and filter (white arrow).

Panel B: Suction cannula (white arrow) placed at the distal end of the thrombus.

Panel C: Extracted well-organized thrombus, 11 cm in length.

Panel D: Completion venography after placement of a self-expanding nitinol stent (white arrow).



Supplementary material is available at *European Heart Journal* online.

Published on behalf of the European Society of Cardiology. All rights reserved. © The Author 2014. For permissions please email: Journals.permissions@oup.com.