OXFORD

Cerebral Cortex, March 2016;26: 943–949

doi: 10.1093/cercor/bhu256
Advance Access Publication Date: 19 October 2014
Original Article

ORIGINAL ARTICLE

Bottom-up Visual Integration in the Medial Parietal Lobe

Tobias Pflugshaupt[1,3], Myriam Nösberger[1], Klemens Gutbrod[4], Konrad P. Weber[1,2], Michael Linnebank[1], and Peter Brugger[1]

[1]Department of Neurology, [2]Department of Ophthalmology, University Hospital Zürich, Zürich, Switzerland, [3]Center of Neurology and Neurorehabilitation, State Hospital Luzern, Luzern, Switzerland, and [4]Department of Neurology, Inselspital, University Hospital Bern, Bern, Switzerland

Address correspondence to Tobias Pflugshaupt, PhD, Center of Neurology and Neurorehabilitation, Luzerner Kantonsspital/State Hospital, 6000 Luzern 16, Switzerland. Email: tobias.pflugshaupt@luks.ch

Abstract

Largely based on findings from functional neuroimaging studies, the medial parietal lobe is known to contribute to internally directed cognitive processes such as visual imagery or episodic memory. Here, we present 2 patients with behavioral impairments that extend this view. Both had chronic unilateral lesions of nearly the entire medial parietal lobe, but in opposite hemispheres. Routine neuropsychological examination conducted >4 years after the onset of brain damage showed little deficits of minor severity. In contrast, both patients reported persistent unusual visual impairment. A comprehensive series of tachistoscopic experiments with lateralized stimulus presentation and comparison with healthy participants revealed partial visual hemiagnosia for stimuli presented to their contralesional hemifield, applying inferential single-case statistics to evaluate deficits and dissociations. Double dissociations were found in 4 experiments during which participants had to integrate more than one visual element, either through comparison or formation of a global gestalt. Against the background of recent neuroimaging findings, we conclude that of all medial parietal structures, the precuneus is the most likely candidate for a crucial involvement in such bottom-up visual integration.

Key words: double dissociation, hemiagnosia, neurovisual disorder, precuneus, tachistoscopic presentation

Introduction

The medial parietal lobe of the human brain extends in a rostral–caudal direction from the pars marginalis of the cingulate sulcus to the occipito-parietal sulcus. It consists of the precuneus, the subparietal sulcus, the posterior part of the cingulate gyrus, and the retrosplenial region. As these association areas are rarely affected by isolated focal damage (Cavanna and Trimble 2006; Leech and Sharp 2014), their function is less known than that of their counterparts on the lateral or inferior surfaces of the cerebrum. Contributing to this relative lack of knowledge, their hidden location in the longitudinal fissure hinders experimental techniques such as transcranial magnetic stimulation. What we know about the function of these regions in the human brain is therefore predominantly based on functional neuroimaging studies conducted in healthy participants.

Reviewing 34 such studies, Cavanna and Trimble (2006) propose that the bilateral precuneus is involved in 3 main areas of higher cognition: Visuo-spatial imagery, retrieval from episodic memory and—through interconnections with medial prefrontal regions—various aspects of self-processing such as first person perspective taking or perceived agency. Further evidence from functional neuroimaging studies suggests that bilateral posterior cingulate (Leech et al. 2012) and retrosplenial regions (Vann et al. 2009) form an essential node of the brain's default network, a system that is active during passive moments or during tasks that require participants to remember past events or imagine upcoming events (Buckner 2013). More specifically, the ventral part of the posterior cingulate cortex may be relevant for internally directed cognition such as memory or planning, while its dorsal part seems to be implicated in the control of attentional focus (Leech and Sharp 2014). According to rare case studies

summarized by Vann et al. (2009), damage to the retrosplenial cortex typically produces amnesia (e.g., Valenstein et al. 1987; McDonald et al. 2001) and/or problems in spatial navigation (e.g., Takahashi et al. 1997; Ino et al. 2007). Finally, the subparietal sulcus has hardly ever been mentioned in clinical–anatomical correlation studies. Richer et al. (1993) propose a role in proprioception, since intracerebral stimulation around this sulcus produced feelings of levitation in pharmaco-resistant epilepsy patients undergoing presurgical investigation.

Here, we present 2 patients with chronic unilateral damage of nearly the entire medial parietal lobe in opposite hemispheres. During standard neuropsychological assessment conducted >4 years after the onset of brain damage, both patients described persisting unusual visual impairment for contralesionally located stimuli. In the following, this impairment will be analyzed in detail, with a series of tachistoscopic experiments forming the core of the investigation.

Materials and Methods

Patients

Demographic and Clinical Background

At the time of the experimental investigation, SS was a 23-year-old, right-handed, female psychology student with Swiss German as her first language. Four and a half years earlier, she had suffered left parietal intracerebral bleeding due to a ruptured arteriovenous malformation that was surgically embolized on the following day. Neurological examination 2 years later revealed no pathological findings. Immediately prior to our experimental investigation, uncorrected near visual acuity measured at 30 cm was 1.25 and thus normal for both eyes. Visual fields were also unaffected as shown by automated static perimetry (Supplementary Fig. 1). Routine MRI of the head performed 5 months before the experimental investigation revealed parenchymal damage extending over large parts of the left medial parietal lobe, whereas primary and secondary visual areas in the occipital lobe as well as in the lateral parietal cortex were spared (Fig. 1). Notably, her lesion also included the entire callosal splenium, indicated by the mere absence of the latter on sagittal slices.

The second patient was LK, a 43-year-old, right-handed, and native German speaking male lecturer who made a PhD in biology. Five years before the experimental investigation, an anaplastic astrocytoma was resected from his right parietal lobe. According to repeated clinical examination over the following years, a mild sensorimotor impairment of the left leg was the only persisting neurological symptom. Identical to SS, he displayed normal near visual acuity measured at 30 cm (i.e., 1.25 for both eyes) and no visual field defect within the area relevant for the tachistoscopic experiments described below in automated static perimetry at the time of the experimental investigation (Supplementary Fig. 1). As a side remark, LK showed a "pie on the floor" field defect in the periphery of the left lower quadrant, consistent with his right parietal lesion. Similar to SS, follow-up MRI of the head revealed brain damage affecting the entire medial parietal lobe and the callosal splenium—again sparing occipital as well as lateral parietal areas—with 2 major differences: In his case, the right but not the left parietal lobe was damaged, and LK's lesion dorsally extended more toward the central sulcus, explaining the sensorimotor impairment of his left leg (Fig. 1).

Neuropsychological Assessment

Prior to the experimental investigation described below, both patients underwent routine neuropsychological examination at the neurological outpatient clinic of the University Hospital Zürich, aimed at evaluating potential cognitive residua. Concerning subjective complaints, SS spontaneously described fatigue,

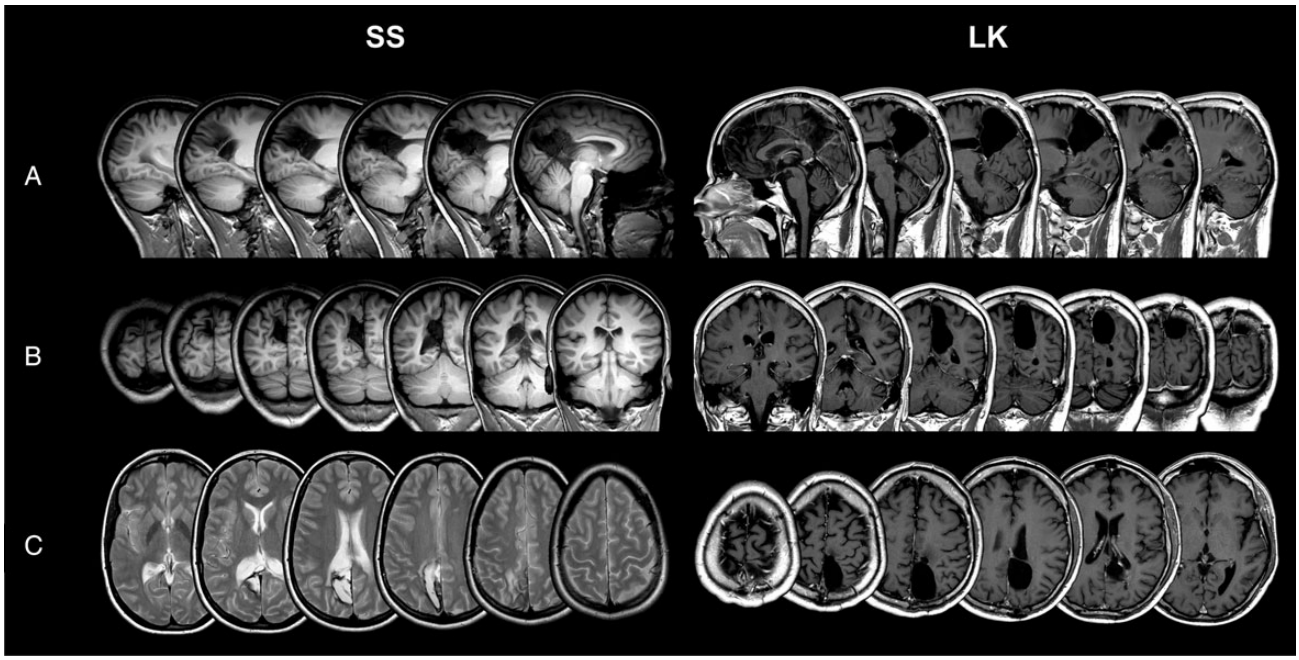

Figure 1. Brain lesions of SS (left) and LK (right) as depicted with standard clinical MRI. (*A*) T_1-weighted sagittal slices through the lesioned hemisphere, covering the entire lesion extent from medial to lateral. (*B*) T_1-weighted coronal slices, covering the entire lesion extent from rostral to caudal. (*C*) T_2- (SS) or T_1-weighted (LK) axial slices, covering the entire lesion extent from dorsal to ventral. Lesions appear as cerebrospinal fluid—isointense areas. Multislices were created with MRIcron (Rorden and Brett 2000) (http://www.mccauslandcenter.sc.edu/mricro/mricron/, last accessed 14 October 2014). Single slices are oriented according to the neurological convention, that is, the left side of the image corresponds to the left side of the brain.

occasional headaches, slowed reading and mental arithmetic, as well as impaired recognition of right-sided visual stimuli ("I see right-sided things but have difficulties identifying them") as residual impairments. In contrast, LK mentioned the sensorimotor impairment of his left leg, spatial navigation problems in novel environments, impaired perception of duration, slowed reading and writing, rare eye hand-coordination problems when typing, and impaired recognition of left-sided visual stimuli ("When the left-sided visual environment lacks structure, everything turns into mush").

A battery of standardized, norm-referenced tests examining attentional, mnestic, visuoconstructive, and executive functions revealed minor impairments only. SS displayed a mild-to-moderate deficit in free recall from verbal long-term memory, LK a mildly reduced visuo-spatial span, and both patients showed a mild deficit in nonverbal response inhibition (Supplementary Table 1). According to additional screening tests, neither SS nor LK presented visual agnosia—tested under normal free-viewing conditions—visual hemineglect, optic ataxia, aphasia, acalculia, or ideomotor apraxia (Supplementary Table 2).

Language laterality was examined with the "Bergen Dichotic Listening Test" (Hugdahl 1995). In the nonforced condition, SS and LK showed laterality indices (LI) of +85 and +92, respectively (range from left to right: −100 to +100). In other words, both patients displayed a pronounced right-ear advantage for spoken syllables, which indicates left-hemispheric language dominance (Hugdahl 2011). Moreover, handedness laterality quotients (LQ; range from left to right: −100 to +100) based on the questionnaire developed by Salmaso and Longoni (1985) were +79 in SS and +100 in SS. Both values represent strong right-handedness and are associated with a probability for left-hemisphere language dominance of 93% and 95%, respectively, applying the formula of Knecht et al. (2000).

Tachistoscopic Experiments

To investigate the subjectively reported visual impairment for contralesional stimuli, a series of 15 tachistoscopic experiments were conducted. During these experiments, SS and LK sat 50 cm in front of a 14″ notebook screen (31×24°), with a chin rest and a forehead stop ensuring constant distance. Basically they had to name, discriminate, or localize a large variety of visual stimuli (e.g., colors, fragmented forms, objects, Navon letters, words, and faces) briefly presented at 6.5° (stimulus center) to the left or right of a central fixation cross (CFC) in the horizontal plane. Every experiment included 4 practice trials and 20 or 40 test trials that were uniformly distributed across both sides and presented in a pseudorandomized order. Each trial began with the CFC shown for 1000 ms, followed by the lateral stimulus (size range: 1–6° × 1–9°) displayed in addition to the CFC. Then, a mask of visual noise appeared for 500 ms to suppress afterimages, succeeded by an untimed response window during which patients gave oral responses. A second experimenter sitting opposite the patient carefully controlled central fixation during the presentation of the lateral stimulus. Task-specific presentation durations of the lateral stimulus (50, 100, 150, or 200 ms) were multiples of the screen's refresh rate and based on task difficulty as derived from a pilot study with 5 healthy participants, assigning the shortest duration to the easiest tasks. Detailed description of all 15 experiments that were programmed and run with E-Prime 2.0™ (Psychology Software Tools, Inc., Pittsburgh, PA, USA) is given in Supplementary Table 3.

The results of SS and LK from these experiments were compared with those of 12 healthy control participants (6 females; mean age: 32 years, age range: 21–53) with an academic background (students, holders of a BSc, MSc, or PhD). Ten of them (83%) showed a right-ear advantage (mean LI: +17, LI range: −18 to +45) in the nonforced condition of the "Bergen Dichotic Listening Test" (Hugdahl 1995), and all of them displayed strong right-handedness (mean LQ: +84, LQ range: +40 to +100) in the questionnaire of Salmaso and Longoni (1985). For the statistical analysis of impairments (patient vs. controls), single dissociations between hemifields (left vs. right, within-patient), and double dissociations between patients, we applied inferential single-case methods and statistically based criteria for classical and strong dissociations (Crawford and Garthwaite 2005; Crawford et al. 2010). For example, the criteria for a classical double dissociation would be fulfilled if (1) SS showed—relative to controls—a significant deficit on task X (e.g., left-sided color naming), but not on task Y (e.g., right-sided color naming), (2) LK displayed the opposite pattern, and (3) the difference between task X and task Y significantly differed from corresponding values of the control group in both SS and LK. Moreover, both patients and all controls gave written informed consent prior to participation.

Results

Four of the 15 tachistoscopic experiments revealed double dissociations (Table 1). When comparing colors or letters with a central reference stimulus and when discriminating positions, SS displayed significant deficits only for right-sided stimuli whereas LK showed the opposite pattern. The findings from each of these 3 experiments fulfilled the criteria for a classical double dissociation. When identifying the global shape of Navon letters, SS again showed significant impairment for right-sided stimuli only, whereas LK had problems with both left- and right-sided global shapes. However, his performance for left-sided stimuli was significantly worse than that for right-sided ones, fulfilling the criteria for a strong dissociation. As schematically illustrated in Figure 2, the overall pattern of double dissociations is consistent: Both SS and LK exclusively or predominantly showed impairment for stimuli presented to their contralesional visual hemifield.

In addition, single dissociations were found in SS's performance during the color naming, size comparison, orientation comparison, object comparison, and form completion tasks. She again exclusively or predominantly displayed deficits for stimuli presented to her contralesional right visual hemifield (Table 2). Conversely, LK had problems when localizing visual stimuli presented to his contralesional left hemifield, in contrast to flawless performance for right-sided stimuli. Neither SS nor LK showed pathological dissociations between hemifields when they had to name objects, read letters, identify the local shape of Navon letters, evaluate the lexical status of letter strings, read words, or recognize faces (Supplementary Table 4).

Discussion

We have introduced 2 patients with medial parietal brain damage in opposite hemispheres who display partial impairment when processing visual stimuli presented to their contralesional hemifield. In the absence of task-relevant homonymous visual field defects, their difficulties are probably best categorized as an incomplete variant of visual hemiagnosia, a disorder previously reported in rare case studies. For example, Mazzucchi et al. (1985) described a patient with right temporo-occipital brain damage who demonstrated pronounced difficulties recognizing visual stimuli such as colors, letters, words, objects, or faces presented to his left hemifield. Complicating both the experimental

Table 1 Double dissociations found in the tachistoscopic experiments with lateralized stimulus presentation

Experiment	Patient	Side		Controls (N = 12)	Singlims_ES[a]			RSDT_ES[a]			Dissocs_ES[a]
		Left	Right	Mean (SD)	t (df = 11)	$P_{one\text{-}tailed}$	z^b_{CC}	t (df = 11)	$P_{one\text{-}tailed}$	z^b_{DCC}	Dissociation
Color comparison	SS	19		19.17 (0.83)	−0.197	0.424	−0.205				
			15	19.67 (0.49)	−9.157	<0.001***	−9.531	5.698	<0.001***	6.363	Classical
	LK	16		19.17 (0.83)	−3.669	0.002**	−3.819				
			20	19.67 (0.49)	0.647	0.265	0.673	2.799	0.009**	−3.065	Classical
Letter comparison	SS	19		19.50 (0.52)	−0.924	0.188	−0.962				
			16	19.33 (0.78)	−4.102	0.001**	−4.269	2.387	0.018*	2.655	Classical
	LK	15		19.50 (0.52)	−8.314	<0.001***	−8.654				
			20	19.33 (0.78)	0.825	0.213	0.859	6.544	<0.001***	−7.636	Classical
Navon letter reading (global letter)	SS	10		9.75 (0.62)	0.387	0.353	0.403				
			6	9.75 (0.45)	−8.006	<0.001***	−8.333	5.061	<0.001***	5.541	Classical
	LK	5		9.75 (0.62)	−7.361	<0.001***	−7.661				
			8	9.75 (0.45)	−3.736	0.002**	−3.889	2.210	0.025*	−2.393	Strong
Position discrimination	SS	19		17.50 (1.93)	1.550	0.075	1.613				
			13	18.67 (1.67)	−3.262	0.004**	−3.395	4.460	<0.001***	5.199	Classical
	LK	10		17.50 (1.93)	−7.748	<0.001***	−8.065				
			19	18.67 (1.67)	0.190	0.426	0.198	6.978	<0.001***	−8.577	Classical

[a]Single-case methods developed by Crawford et al. (2010). Singlims_ES compares the test score of a patient with those of a control group, RSDT_ES compares the difference between 2 test scores (here left vs. right) of a patient against corresponding differences of a control group, and Dissocs_ES tests whether the pattern of a patient in 2 tasks meets the criteria for a classical or strong dissociation.
[b]Point estimates of the effect size measured in standard deviation units.
*Significant at $\alpha = 0.05$.
**Significant at $\alpha = 0.01$.
***Significant at $\alpha = 0.001$.

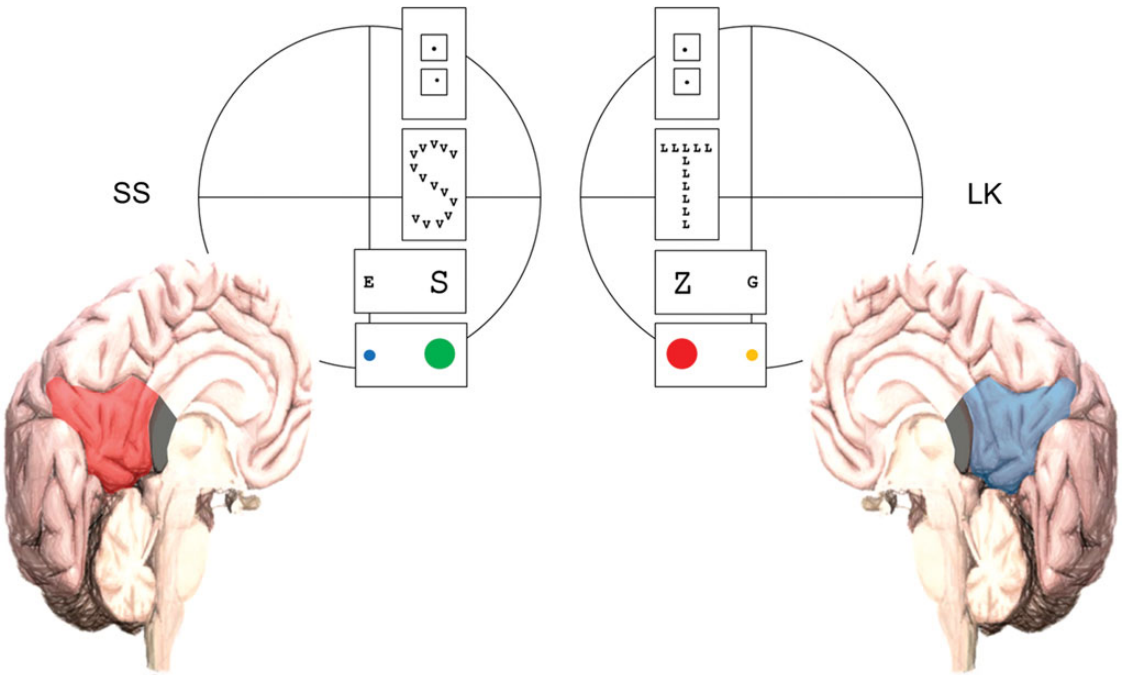

Figure 2. Schematic illustration of brain lesions and double dissociations found in tachistoscopic experiments with lateralized stimulus presentation. Medial parietal lesions are highlighted in red (SS) or blue (LK), the lesion of the callosal splenium in dark gray. Both patients showed classical or strong dissociations between hemifields in the color comparison, letter comparison, Navon global letter reading, and position discrimination tasks. Stimulus examples are shown in the hemifield where the worse performance was observed. Source note: The sagittal brain view was downloaded from http://www.healthline.com/human-body-maps/brain, last accessed 14 October 2014.

investigation and the interpretation as an agnostic disorder to some degree, Goldmann perimetry revealed left upper homonymous quadrantanopia extending over the horizontal meridian in both of his eyes. A purer case of visual hemiagnosia was later introduced by Charnallet et al. (1988). Their patient had left occipital brain damage—apparently sparing the primary

Table 2 Single dissociations found in the tachistoscopic experiments with lateralized stimulus presentation

Experiment	Patient	Side		Controls (N = 12)	Singlims_ES[a]			RSDT_ES[a]			Dissocs_ES[a]
		Left	Right	Mean (SD)	t (df = 11)	$P_{one\text{-}tailed}$	z^b_{CC}	t (df = 11)	$P_{one\text{-}tailed}$	z^b_{DCC}	Dissociation
Color naming	SS	8		8.75 (0.97)	−0.743	0.237	−0.773				
			6	9.17 (0.72)	−4.230	<0.001***	−4.403	3.478	0.003**	4.008	Classical
	LK	7		8.75 (0.97)	−1.733	0.056	−1.804				
			8	9.17 (0.72)	−1.561	0.073	−1.625	0.176	0.432	−0.198	None
Size comparison	SS	16		18.42 (1.31)	−1.775	0.052	−1.847				
			13	18.75 (0.87)	−6.350	<0.001***	−6.609	2.733	0.010**	2.953	Classical
	LK	19		18.42 (1.31)	0.425	0.340	0.443				
			19	18.75 (0.87	0.276	0.394	0.287	0.089	0.465	0.096	None
Orientation comparison	SS	19		18.50 (1.00)	0.480	0.320	0.500				
			12	18.83 (0.72)	−9.114	<0.001***	−9.486	6.555	<0.001***	7.557	Classical
	LK	19		18.50 (1.00)	0.480	0.320	0.500				
			18	18.83 (0.72)	−1.108	0.146	−1.153	1.137	0.140	1.251	None
Object comparison	SS	18		19.75 (0.45)	−3.736	0.002**	−3.889				
			16	19.92 (0.29)	−12.987	<0.001***	−13.517	7.854	<0.001***	9.847	Strong
	LK	19		19.75 (0.45)	−1.601	0.069	−1.667				
			20	19.92 (0.29)	0.265	0.398	0.276	1.764	0.053	−1.987	None
Form completion	SS	9		9.08 (0.90)	−0.085	0.467	−0.089				
			6	8.67 (1.15)	−2.231	0.024*	−2.322	1.922	0.040*	2.161	Classical
	LK	6		9.08 (0.90)	−3.288	0.004**	−3.422				
			7	8.67 (1.15)	−1.395	0.095	−1.452	1.699	0.059	−1.906	None
Localizing	SS	10		9.75 (0.45)	0.534	0.302	0.556				
			10	10.00 (0.00)	No data[c]						
	LK	6		9.75 (0.45)	−8.006	<0.001***	−8.333				
			10	10.00 (0.00)	No data[c]						

[a]Single-case methods developed by Crawford et al. (2010).
[b]Point estimates of the effect size measured in standard deviation units.
[c]All controls flawlessly localized right-sided stimuli. The resulting lack of statistical spread prevented the use of Singlims_ES for this variable, and that of RSDT_ES and Dissocs_ES for this experiment.
*Significant at $\alpha = 0.05$.
**Significant at $\alpha = 0.01$.
***Significant at $\alpha = 0.001$.

visual cortex as confirmed by full visual fields in Goldmann perimetry—and showed severe difficulties identifying a similarly wide variety of visual stimuli presented to his right hemifield.

Compared with these cases, the visual hemiagnosia of SS and LK appears more subtle, as evident by unimpaired performances during the letter reading or object naming experiment, for example. The 4 tasks that revealed double dissociations between our 2 patients—that is, color comparison, letter comparison, position discrimination, and identification of global Navon letter shapes—have one particular feature in common: They require participants to integrate more than one visual element, either through comparison or formation of a global gestalt. This also applies for the size comparison, orientation comparison, object comparison, and form completion tasks, which provoked single dissociations between hemifields in SS.

An alternative interpretation of the main findings in SS and LK would be that both may suffer from a deficit in attending to contralesional stimuli, rather than in visually integrating them. Support for this notion emerges from studies linking the precuneus to spatial attention in healthy participants (Mahayana et al. 2014) or to spatial hemineglect in brain-damaged patients (Molenberghs et al. 2012). We cannot completely rule out an influence of spatial inattention on our findings. But such influence seems marginal at most, as neither SS nor LK showed any sign of a contralesional hemineglect in standard cancelation or line bisection tasks (cf. Supplementary Table 2).

Given the evidence pointing toward a role of the precuneus (Cavanna and Trimble 2006) and the retrosplenial cortex (Vann et al. 2009) in mnestic processing, it may surprise that SS and LK showed minor memory deficits only. However, both patients underwent routine neuropsychological examination >4 years after the onset of brain damage, a time period long enough to allow at least partial recovery. Impaired learning of new routes and spatial disorientation due to unilateral retrosplenial damage, for example, is known to resolve within a few months in the majority of reported cases (Maguire 2001; Epstein 2008). All the more impressive is the observation that the visual integration impairment SS and LK show for contralesionally presented stimuli seems very persistent.

Since both SS and LK had a fully disconnected callosal splenium in addition to unilateral damage of the medial parietal lobe, it is important to discuss whether their impairment should be interpreted topologically—thereby assigning bottom-up visual integration function to the medial parietal lobe—or hodologically in terms of a disconnection syndrome. We have strong arguments in favor of the topological approach. First, crossed behavioral findings in the 2 patients suggest an association with their crossed lesion portion—that is, the medial parietal damage—rather than with the uniform lesion of the unpaired splenium. Second, complete callosotomy in patients with left-hemisphere language dominance typically leads to anomia in speech and writing for visual stimuli presented to the left

hemifield, whereas correctly matching or outlining the very same stimuli is still possible (Sperry et al. 1969). SS and LK who both show strong evidence for left-hemisphere language dominance differ from this pattern in at least 2 regards: SS displayed difficulties mainly with right-sided stimuli, and the visual impairment of both patients included basic perceptual matching.

Further support for a topological interpretation emerges from functional neuroimaging findings, indicating that the most prominent part of the medial parietal lobe, the precuneus, may contribute to bottom-up visual integration. Himmelbach et al. (2009)—applying an event-related design—found bilateral activity differences in the precuneus and the primary intermediate sulcus of a patient with subtotal simultanagnosia due to posterior cortical atrophy, when they contrasted successful with failed identification of global Navon letter shapes. Huberle and Karnath (2012) compared intact with disturbed perception of global square or circle shapes in healthy participants and showed bilateral activity differences in the temporo-parietal junction, the precuneus (predominantly left-sided), and the anterior cingulate cortex. Tanskanen et al. (2008) recorded cortical responses of healthy participants to contour versus no-contour visual stimuli and found the most prominent differences in the bilateral precuneus and occipito-parietal sulcus. Moreover, the precuneus seems involved in complex forms of visual integration such as the perception of biological motion in point-light animations (Ptito et al. 2003; Saygin and Sereno 2008).

Taken together with our results, these findings suggest that the bilateral precuneus contributes not only to internally directed cognition such as visual imagery, retrieval from episodic memory, or self-processing (Cavanna and Trimble 2006), but also to externally directed, bottom-up integration of visual elements. The double dissociations observed in SS and LK further suggest a retinotopical organization insofar as the left precuneus might be involved in the integration of visual elements in the right hemifield and vice versa. Given its rich connectivity with numerous cortical and subcortical areas (Cavanna and Trimble 2006) and its contribution to integrating functions such as awareness or consciousness (Cavanna 2007), the bilateral precuneus might also be involved in bridging externally directed and internally directed cognition, together with other multimodal association areas such as the lateral prefrontal cortex (Mesulam 1998; Dixon et al. 2014).

With regard to limitations of the present study, an intrinsic constraint of any case report is first mentioned, that is, the debatable generalizability of the findings. Furthermore, the arguments mentioned above favoring a topological over a hodological interpretation refer to a comparison of the medial parietal lesion with the splenial disconnection. It is, however, possible that, within the medial parietal lobe, not only cortical damage but also damage to the proximal white matter might contribute to the unusual visual impairment observed in SS and LK. Finally, visual integration is likely based on a network of brain regions. Here, we propose that the bilateral precuneus may be an important node of this network. Others have emphasized, for example, the bilateral temporo-parietal junction (Fink et al. 1997; Huberle and Karnath 2012; Rennig et al. 2013) or the bilateral primary intermediate sulcus located between the angular and the supramarginal gyrus (Himmelbach et al. 2009).

Supplementary Material

Supplementary material can be found at: http://www.cercor.oxfordjournals.org/

Notes

We thank SS, LK, and all control participants for their time and effort as well as Ursula Gautschy for acquiring the visual fields. *Conflict of Interest*: None declared.

References

Buckner RL. 2013. The brain's default network: origins and implications for the study of psychosis. Dialogues Clin Neurosci. 15 (3):351–358.

Cavanna AE. 2007. The precuneus and consciousness. CNS Spectr. 12(7):545–552.

Cavanna AE, Trimble MR. 2006. The precuneus: a review of its functional anatomy and behavioural correlates. Brain. 129 (3):564–583.

Charnallet A, Carbonnel S, Pellat J. 1988. Right visual hemiagnosia: a single case report. Cortex. 24(2):347–355.

Crawford JR, Garthwaite PH. 2005. Testing for suspected impairments and dissociations in single-case studies in neuropsychology: evaluation of alternatives using Monte Carlo simulations and revised tests for dissociations. Neuropsychology. 19:318–331.

Crawford JR, Garthwaite PH, Porter S. 2010. Point and interval estimates of effect sizes for the case-controls design in neuropsychology: rationale, methods, implementations, and proposed reporting standards. Cogn Neuropsychol. 27:245–260.

Dixon ML, Fox KC, Christoff K. 2014. A framework for understanding the relationship between externally and internally directed cognition. Neuropsychologia. 62:321–330.

Epstein RA. 2008. Parahippocampal and retrosplenial contributions to human spatial navigation. Trends Cogn Sci. 12:388–396.

Fink GR, Halligan PW, Marshall JC, Frith CD, Frackowiak RS, Dolan RJ. 1997. Neural mechanisms involved in the processing of global and local aspects of hierarchically organized visual stimuli. Brain. 120:1779–1791.

Himmelbach M, Erb M, Klockgether T, Moskau S, Karnath HO. 2009. fMRI of global visual perception in simultanagnosia. Neuropsychologia. 47(4):1173–1177.

Huberle E, Karnath HO. 2012. The role of temporo-parietal junction (TPJ) in global Gestalt perception. Brain Struct Funct. 217(3):735–746.

Hugdahl K. 1995. Dichotic listening: probing temporal lobe functional integrity. In: Davidson RJ, Hugdahl K, editors. Brain asymmetry. Cambridge (MA): MIT Press. p. 123–156.

Hugdahl K. 2011. Fifty years of dichotic listening research - still going and going and. . .. Brain Cogn. 76(2):211–213.

Ino T, Doi T, Hirose S, Kimura T, Ito J, Fukuyama H. 2007. Directional disorientation following left retrosplenial haemorrhage: a case report with fMRI studies. Cortex. 43(2):248–254.

Knecht S, Dräger B, Deppe M, Bobe L, Lohmann H, Flöel A, Ringelstein EB, Henningsen H. 2000. Handedness and hemispheric language dominance in healthy humans. Brain. 12:2512–2518.

Leech R, Braga R, Sharp DJ. 2012. Echoes of the brain within the posterior cingulate cortex. J Neurosci. 32(1):215–222.

Leech R, Sharp DJ. 2014. The role of the posterior cingulate cortex in cognition and disease. Brain. 137(1):12–32.

Maguire EA. 2001. The retrosplenial contribution to human navigation: a review of lesion and neuroimaging findings. Scand J Psychol. 42:225–238.

Mahayana IT, Tcheang L, Chen CY, Juan CH, Muggleton NG. 2014. The precuneus and visuospatial attention in near and far

space: a transcranial magnetic stimulation study. Brain Stimul. 7(5):673–679.

Mazzucchi A, Posteraro L, Nuzzi G, Parma M. 1985. Unilateral visual agnosia. Cortex. 21(2):309–316.

McDonald CR, Crosson B, Valenstein E, Bowers D. 2001. Verbal encoding deficits in a patient with a left retrosplenial lesion. Neurocase. 7:407–417.

Mesulam MM. 1998. From sensation to cognition. Brain. 121 (6):1013–1052.

Molenberghs P, Sale MV, Mattingley JB. 2012. Is there a critical lesion site for unilateral spatial neglect? A meta-analysis using activation likelihood estimation. Front Hum Neurosci. 6:78.

Ptito M, Faubert J, Gjedde A, Kupers R. 2003. Separate neural pathways for contour and biological-motion cues in motion-defined animal shapes. Neuroimage. 19(2):246–252.

Rennig J, Bilalić M, Huberle E, Karnath HO, Himmelbach M. 2013. The temporo-parietal junction contributes to global gestalt perception-evidence from studies in chess experts. Front Hum Neurosci. 7:513.

Richer F, Martinez M, Robert M, Bouvier G, Saint-Hilaire JM. 1993. Stimulation of human somatosensory cortex: tactile and body displacement perceptions in medial regions. Exp Brain Res. 93 (1):173–176.

Rorden C, Brett M. 2000. Stereotaxic display of brain lesions. Behav Neurol. 12:191–200.

Salmaso D, Longoni AM. 1985. Problems in the assessment of hand preference. Cortex. 21(4):533–549.

Saygin AP, Sereno MI. 2008. Retinotopy and attention in human occipital, temporal, parietal, and frontal cortex. Cereb Cortex. 18(9):2158–2168.

Sperry RW, Gazzaniga MS, Bogen JE. 1969. Interhemispheric relationships: the neocortical commissures; syndromes of hemisphere disconnection. In Vinken PJ, Bruyn GW, editors. Handbook of clinical neurology, Vol. 4. Amsterdam: North Holland. p. 273–290.

Takahashi N, Kawamura M, Shiota J, Kasahata N, Hirayama K. 1997. Pure topographic disorientation due to right retrosplenial lesion. Neurology. 49(2):464–469.

Tanskanen T, Saarinen J, Parkkonen L, Hari R. 2008. From local to global: cortical dynamics of contour integration. J Vis 8(7):15, 1–12.

Valenstein E, Bowers D, Verfaellie M, Heilman KM, Day A, Watson RT. 1987. Retrosplenial amnesia. Brain. 110(6):1631–1646.

Vann SD, Aggleton JP, Maguire EA. 2009. What does the retrosplenial cortex do? Nat Rev Neurosci. 10(11):792–802.