

Severe calcification of a Shelhigh stentless valved conduit

Fabian Gisler^a, Christoph Huber^a, Peter Wenaweser^b and Thierry Carrel^{a,*}

^a Clinic for Cardiovascular Surgery, University Hospital Berne, Berne, Switzerland

^b Clinic for Cardiology, University Hospital Berne, Berne, Switzerland

* Corresponding author. Clinic for Cardiovascular Surgery, University Hospital Berne, 3010 Berne, Switzerland. Tel: +41-31-6322375; fax: +41-31-6324443; e-mail: thierry.carrel@insel.ch (T. Carrel).

Received 9 October 2013; received in revised form 30 October 2013; accepted 5 November 2013

Keywords: Aortic calcification • TAVI • Stentless conduit

A 74-year old patient developed severe aortic valve regurgitation 11 years following root replacement using a stentless Shelhigh tube-graft. Computed tomography scan showed a heavily calcified aortic conduit (Fig. 1), although the company

claims that detoxification process eliminates residual glutaraldehyde and ensures less calcification in the long term. The patient underwent successful transapical transcatheter aortic valve implantation.

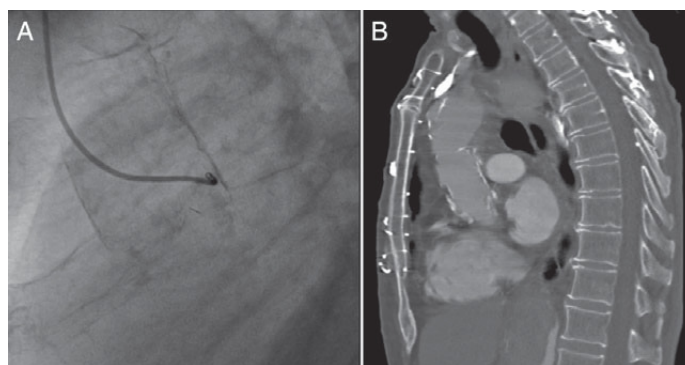


Figure 1: Severely calcified Shelhigh-conduit in (A) angiography and (B) computed tomography.