

# A Model of Ischemic Isolated Acute Liver Failure in Pigs: Standardizing Monitoring and Treatment

A. Al-Chalabi<sup>a</sup> E. Matevossian<sup>b</sup> A. Preißel<sup>c</sup> A. Perren<sup>d,g</sup> Z. Yang<sup>a</sup>  
T. Schuster<sup>e</sup> C. Schreiber<sup>a</sup> P. Schimmel<sup>a</sup> E. Nairz<sup>a</sup> H. Yan<sup>a</sup> A. Geiger<sup>a</sup>  
B. Kreymann<sup>f</sup>

Departments of <sup>a</sup>Medicine II and <sup>b</sup>Surgery, and <sup>c</sup>Institute of Preclinical Studies, Klinikum rechts der Isar, <sup>d</sup>Institute of Pathology, and <sup>e</sup>Institute of Medical Statistics and Epidemiology, Technical University Munich, and <sup>f</sup>Hepa Wash GmbH, Munich, Germany; <sup>g</sup>Institute of Pathology, University of Bern, Bern, Switzerland

## Key Words

Acute liver failure · Portacaval shunt · Standardization

## Abstract

**Background:** Acute liver failure (ALF) models in pigs have been widely used for evaluating newly developed liver support systems. But hardly any guidelines are available for the surgical methods and the clinical management. **Methods:** The study validated several standard operating procedures describing in detail the surgical method and intensive care monitoring and treatment (control of potassium, glucose and bicarbonate levels, cardiovascular and intracranial pressure monitoring, etc.). ALF was induced in animals with a mean of 56 kg. Two surgical methods were compared: ligation of hepatic arteries with either end-to-side portacaval shunt (ESPS) and bile duct ligation or side-to-side portacaval shunt (SSPS) without bile duct ligation. **Results:** During total portal vein clamping, the animals in the ESPS group developed severe hypotension, splanchnic congestion and metabolic acidosis. One animal died after approximately 1.5 h. This model therefore represents a multiorgan failure model rather than an isolated ALF model. In the SSPS group, none of these side effects were observed, while clinical, labora-

tory and histopathological signs of ALF were evident. **Conclusions:** A reproducible model in pigs representing ALF can be established with the help of the standardized monitoring and treatment procedures presented.

Copyright © 2010 S. Karger AG, Basel

## Introduction

In the last four decades there have been many different approaches to developing medical devices to support the failing liver. Artificial as well as bioartificial (cell-based) liver support systems have been introduced with the aim of substituting liver functions. The need for an appropriate animal model of acute liver failure (ALF) to test new liver support systems cannot be overemphasized. It is not only important to prove the safety and efficacy of such devices, but also to achieve a better understanding of the underlying pathophysiology of the clinical syndrome. However, appropriate large animal models which mimic the pathophysiological changes seen in humans and allow proper testing of new medical devices are still not convincing. Many investigators have tried to standardize models by setting criteria [1–5]. ALF in animals has been

## KARGER

Fax +41 61 306 12 34  
E-Mail [karger@karger.ch](mailto:karger@karger.ch)  
[www.karger.com](http://www.karger.com)

© 2010 S. Karger AG, Basel  
0014–312X/10/0452–0086\$26.00/0

Accessible online at:  
[www.karger.com/esr](http://www.karger.com/esr)

Ahmed Al-Chalabi  
II Medizinische Klinik und Poliklinik, Klinikum rechts der Isar  
Ismaningerstrasse 22  
DE–81675 Munich (Germany)  
Tel. +49 89 4140 7288, Fax +49 89 4140 7301, E-Mail [ahmed.al-chalabi@lrz.tum.de](mailto:ahmed.al-chalabi@lrz.tum.de)

induced by various methods. In the hepatectomy model, the liver is completely removed and a Y prosthesis used to connect the free ends of the portal vein and the caudal vena cava [6]. This model may correspond only to patients whose liver has been removed and who are awaiting transplantation. It has only little correlation with the clinical syndrome of ALF where the liver responds as an immunological organ and toxic substances are poured into the blood from the necrotic hepatocytes [7]. In the toxicity model, substances like carbon tetrachloride, thioacetamide, acetaminophen or galactosamine are administered to the animal at levels toxic to the liver. This model is only applicable if specific intoxication syndromes are to be investigated. Pigs with nonhomogenous genetic backgrounds show a wide variety of responses to these toxins, thus reproducibility is a great concern in such models [1].

Another method used since the early 1950s is the surgical obstruction of the blood supply (portal and arterial) to elicit an ischemic injury to the liver [8]. Surgery may be performed in one or two stages, while cutting the blood supply may be transient or permanent [9]. If transient, the ischemia should last for a sufficient time to cause a mortal injury [3]. Traditionally, the bile duct is transected to add the effects of cholestasis [9]. Occluding the portal vein necessitates the diversion of blood from the internal organs to avoid splanchnic congestion. Investigators have achieved this by establishing a portacaval shunt, which is mostly an end-to-side portacaval shunt (ESPS) [7, 10, 11] or rarely a side-to-side portacaval shunt (SSPS) [3, 12, 13].

In most published animal studies, ESPS was used. But the large increase in ammonia intracranial pressure (ICP), in addition to the possibility that the splanchnic congestion during clamping of the portal vein results in gut ischemia, raised our doubts about the appropriateness of this model. In our quest for an ALF model to test our new liver support device, we performed a pilot study in which we tried to elucidate the optimal method for diverting splanchnic blood and for clamping the arterial supply and to investigate the difference between ESPS and SSPS.

The clinical problems complicating liver failure are manifold. Nearly any organ can be involved. But currently, no standard for medical treatments in pigs exists regarding, for example, fluid management, treatment of hyperkalemia, acid-base disturbances, respiratory failure and cardiovascular failure, and for the treatment or prevention of kidney failure. From experience in humans, we know that fluid management can have a great impact on survival. Even for the measurement of ICP in pigs, no de-

tailed description is available. We therefore performed a series of pilot studies to establish appropriate medical management of pigs with ALF.

## Methods

### *Animals and Housing*

Seven German landrace female pigs (3–4 months old) were included in the study. To allow accommodation, the animals were kept at least 4 days in the stall of the Center for Preclinical Research, where the experiments were performed. The experiments were approved by the ethical committee for animal studies in Bavaria, Germany. Housing and all medical and surgical procedures were in accordance with the national animal protection act (*Tierschutzgesetz*). The animals were fasted the night before the experiment, but with free access to water.

### *Weight*

The study was conducted on large animals with a mean weight of 56 kg.

### *Anesthesia and Ventilation*

Premedication of the animals was performed intramuscularly with ketamine (15 mg/kg), azaperone (2 mg/kg) and atropine (0.5–1 mg/kg). Two venous cannulas were inserted into the lateral ear veins. Propofol (60–100 mg) was injected to facilitate intubation. The pigs were then transferred to the surgery room, where anesthesia was maintained intravenously with propofol (8.5 mg/kg/h), fentanyl (0.015 mg/kg/h), pentobarbitone (2 mg/kg/h) and atracurium (0.6–0.7 mg/kg/h).

The animals were ventilated (Servo Ventilator 900C; Siemens-Elema, Sweden) by intermittent positive pressure with a mixture of oxygen (30–60%) and air. The end-tidal CO<sub>2</sub> was kept between 35 and 45 mm Hg and the ventilation rate between 14 and 20 breaths per minute.

### *Euthanasia*

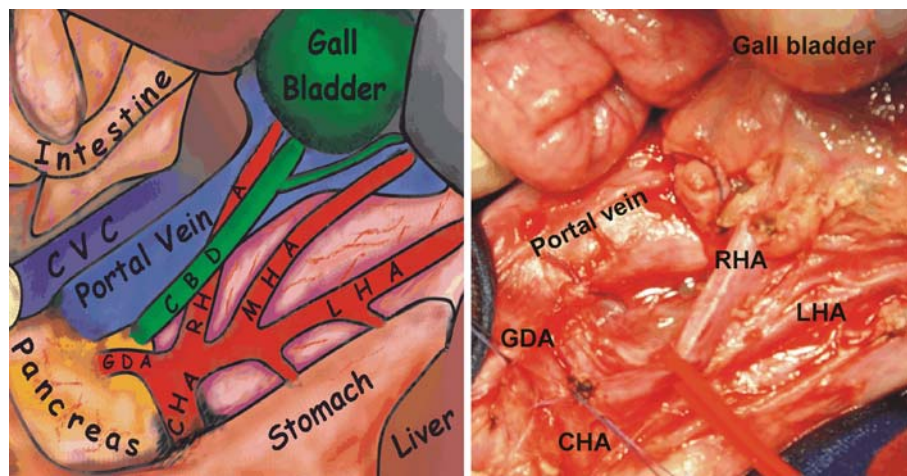
Surviving animals were sacrificed with a lethal dose of pentobarbitone and KCl intravenously injected 8 h after induction of ALF.

### *Cannulation*

The skin was incised anterior to the sternocleidomastoid muscle and the neck vessels were exposed. A 14-french double-lumen catheter was inserted in the external jugular vein. The internal jugular vein was cannulated with a 4-lumen catheter through which fluids like normal saline and glucose were infused. Another catheter was inserted to the carotid artery and connected to a pressure sensor. The femoral artery was catheterized with a 5-french thermistor-tipped catheter (PV 2015L20; Pulsion Medical Systems AG, Munich, Germany) using the Seldinger technique. The urine bladder was drained into a urine bag via a surgically inserted suprapubic catheter.

### *Surgical Anatomy*

The bile duct is the easiest structure to identify in the hepatoduodenal ligament, usually lying at its right free border anterior to the portal vein. The liver is supplied with 3 or 4 hepatic arteries



**Fig. 1.** Anatomy of the hepatoduodenal ligament in pigs. CVC = Caudal vena cava; CBD = common bile duct; RHA = right hepatic artery; MHA = middle hepatic artery; LHA = left hepatic artery; GDA = gastroduodenal artery; CHA = common hepatic artery.

supported by a rich anastomosis in the region (fig. 1). The left hepatic artery runs parallel to the lesser curvature of the stomach, supplying it with 1 or 2 branches (left gastric arteries). One or 2 middle hepatic arteries run between the bile duct and the left hepatic artery, while the right hepatic artery lies dorsal to the common bile duct in close approximation to the portal vein. The left hepatic artery can be followed proximally to the common hepatic artery. It might be necessary to remove a large lymph node before this artery can be found. The gastroduodenal artery branches caudolaterally off from the common hepatic artery and supplies the duodenum and half of the pancreas. One or more lymph nodes lie on the upper part of the portal vein and should be removed. The upper part of the caudal vena cava, which lies dorsolateral to the portal vein, is usually covered with thin liver tissue, and its lateral side by the caudate lobe before being completely hidden by liver. The caudate lobe drains directly into the caudal vena cava through multiple small hepatic veins. Before birth, the umbilical vein drains into the liver. If ligation of the arterial supply and the portal vein is performed, blood pressure within the liver is reduced to very low values. Consequently, blood supply to the liver may come from a reversed flow of an open umbilical vein. In addition, backflow from the caudal vena cava to the hepatic veins may occur. Therefore, the round ligament of the liver should be transected during the operation. The caudate lobe receives its blood supply from the surrounding structures.

*Surgical Procedure*

After laparotomy, the liver and the portal tract were exposed. The anterior layer of the hepatoduodenal ligament was incised and the hepatic arteries were identified (fig. 1). Vessel loops were put around the common hepatic artery and all its branches, but were kept lax until the portacaval shunt was established. In addition, the portal vein was exposed 5 cm above and below the junction with the splenic vein. The portacaval shunt can be established through the layer of liver tissue surrounding the caudal vena cava, as described by Huguet et al. [14].

In the ESPS group (n = 3), the portal vein was ligated near the hilus, transected and mobilized toward the caudal vena cava. The ESPS was established with a 5/0 Prolene® suture (nonresorbable). The bile duct was also transected between 2 ligatures.

In the SSPS group (n = 4), the portal vein and the caudal vena cava were partially clamped (occluding two thirds and one third of the lumen, respectively) and an SSPS was established with a 5/0 Prolene suture (nonresorbable). The bile duct was kept intact.

Afterwards, the common hepatic artery and branches – including gastroduodenal and left gastric arterie(s) – in both groups, as well as the portal vein superior to the shunt in the SSPS group, were simultaneously ligated (Vicryl, 2/0, resorbable). This heralded the start of ALF (T0).

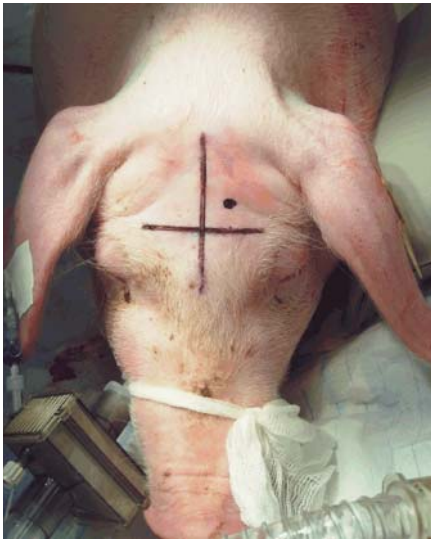To ensure the reproducibility of the severity of the ALF, the whole hepatoduodenal ligament was additionally ligated (except for the bile duct). Even with these measures, the caudate lobe might still survive, thus appearing in a color different from the other ischemic regions. Therefore, it was also gently ligated, avoiding liver injury (tears) or disturbing the shunt.

*Fluid Balance Monitoring and Management*

To optimize hemodynamic monitoring and fluid management, the PiCCO® plus system (Pulsion Medical Systems AG) was used. This monitoring system provides a number of hemodynamic parameters including the extravascular lung water index (ELWI) and global end-diastolic volume index (GEDVI). Fluid management was targeted at an ELWI of <12 ml/kg and a GEDVI of 550–750 ml/m<sup>2</sup>. Fluid substitution was performed with intravenous crystalloids. No colloids were administered. The choice of crystalloids depended on glucose and sodium levels in the blood. Generally, normal saline (0.9% NaCl) and glucose (5 or 20%) were given at a total rate of 100–600 ml/h.

*Cardiovascular Monitoring and Management*

A standard lead II electrocardiogram was used to monitor cardiac rhythm. Respiratory and hemodynamic parameters such as pulse rate, arterial blood pressure, O<sub>2</sub> saturation and end-tidal volume were monitored using the Compact Critical Care Monitor (Datex-Ohmeda, Helsinki, Finland). Dobutamine starting from 5 µg/kg/min was infused only in the ESPS group and only during surgery to support the failing circulation. No catecholamines were used to treat hypotension in the SSPS group.



Color version available online

**Fig. 2.** Important anatomical landmarks in pig for the measurement of ICP.

#### Measurement and Monitoring of ICP

ICP and temperature were monitored using an intraparenchymal transducer (Raumedic AG, Münchberg, Germany), and registered by the Raumedic Datalogger MPR2 logO. The transducer was inserted before starting the major surgery while the animal was in a prone position. The skin and underlying tissues up to the skull were incised. The incision should be done 1.5 cm lateral to the midsagittal line and 1.5 cm above the transverse line that lies on the level of the supraorbital ridge (fig. 2). The skull was then drilled and the bolt screwed in. The transducer was inserted 2–3 cm deep into the parenchyma after the dura mater had been punctured. Loss of liquor was avoided to ensure correct measurements. The increase in ICP was observed without therapeutic interventions. The position of the sensor was checked later by autopsy. No attempts were made to reduce intracranial hypertension.

#### Sampling

Blood gas analysis (including glucose measurement) was performed routinely every hour and repeated if necessary (Rapidpoint® 400; Siemens Health Care Diagnostics Inc., Bad Nauheim, Germany). Blood samples for biochemical analyses (liver enzymes, renal function and ammonia) were collected before laparotomy and after induction of liver failure (every 2 h) and were sent to the in-house laboratory.

#### Body Temperature

The body temperature was kept around 38°C with a heating pad and blankets.

#### Medications

No antibiotics or diuretics were administered during the experiments.

#### Glucose Infusions

Glucose was closely monitored with the aim of keeping it around 120 mg/dl; 5–50% glucose solutions were given to adjust the rates according to fluid status of the animals. Due to the short course of the experiments, no further parenteral nutrition was given.

#### Treatment of Hyperkalemia

Treatment was started as early as the potassium values were >4.8 mmol/l by adjusting glucose infusions and insulin injections (5–10 IU), repeated if necessary, with close monitoring of the glucose level to avoid hypoglycemia.

#### Treatment of Metabolic Acidosis

Sodium bicarbonate was given in boli of 1 ml/kg of an 8.4% solution to avoid acidosis and hyperkalemia.

#### Treatment of Respiratory Acidosis

If respiratory acidosis developed, improvement of the acid-base status by increasing tidal volume or respiratory rate was attempted. The aim was to keep the blood pH >7.2. Bicarbonate was only given in case the plasma values were reduced and the pH sank to <7.2 to avoid further decreases in intracellular pH.

#### Autopsy

An autopsy and postmortem collection of the liver was conducted.

#### Statistics

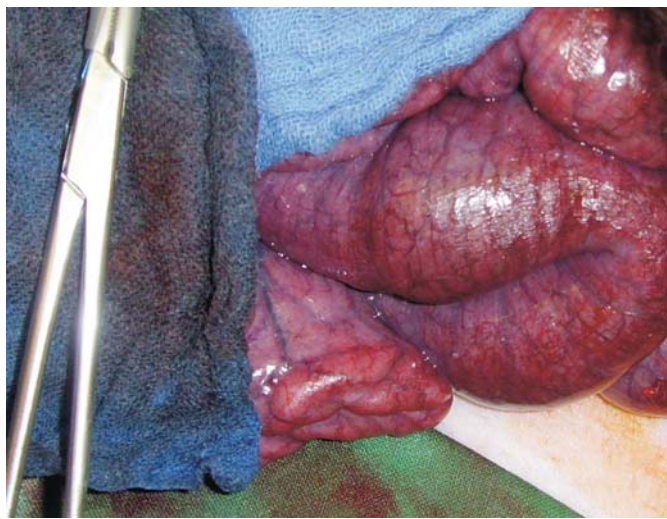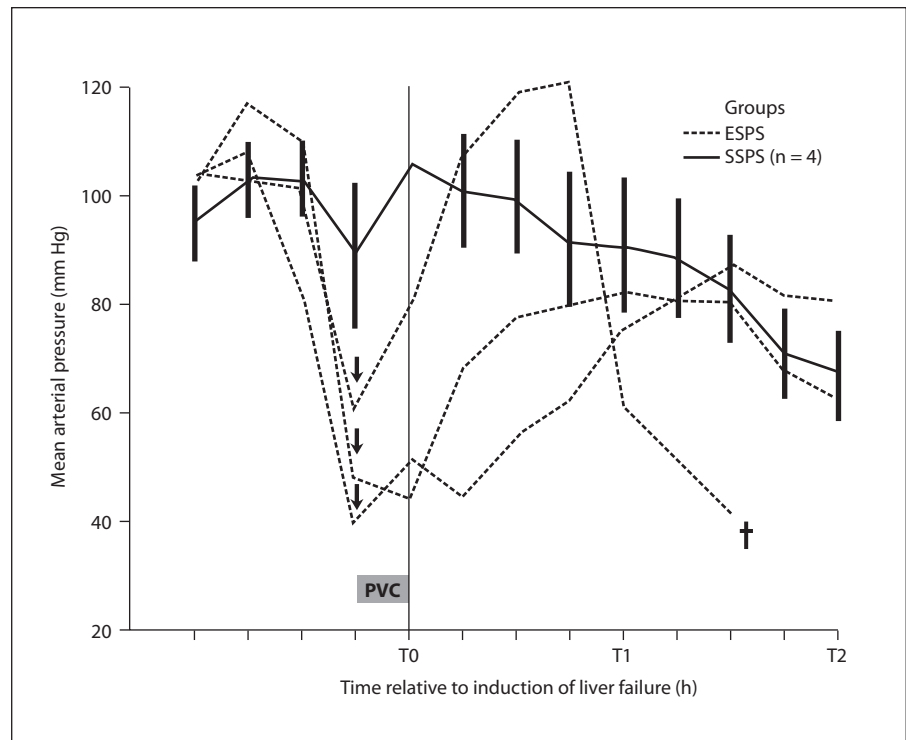
The graphics were depicted by PASW® for Windows version 17.0.2. Data are presented as means ± SEM for the SSPS group, and as individual values for the ESPS group. Student's paired t test was used to statistically assess changes in quantitative data between T0 and T8 in the SSPS group.  $p \leq 0.05$  was considered significant. To retain a maximum power in consideration of the limited sample sizes, no correction of p values for multiple testing was performed. However, an informal adjustment for multiple comparisons may be conducted by the reader based on the results (particularly the number of statistical tests) which are thoroughly provided in the text.

## Results

### ESPS Group

The total clamping time of the portal vein was 15–25 min. A serious complication that we encountered after total clamping of the portal vein in the ESPS group was severe hypotension (fig. 3) accompanied by dark blue discoloration (cyanosis) of intestinal loops (fig. 4). The mean arterial pressure was reduced to below 45 mm Hg despite the concomitant infusion of 2 liters of fluid. Severe metabolic acidosis developed, as was evident from blood gas analysis (pH <7.3;  $[\text{HCO}_3^-] < 22$  mmol/l), as well as hyperlactatemia at T0. After declamping, the blood pressure of 2 animals in the ESPS group gradually improved to pre-

**Fig. 3.** Mean arterial pressure during surgical procedure. Animals in the ESPS group had a severe drop in blood pressure (interrupted lines) after portal vein clamping (PVC), while in the SSPS group (uninterrupted lines; means  $\pm$  SEM), the blood pressure was preserved during the surgical procedure. Arrows: start of catecholamine administration. † = Death of 1 animal in the ESPS group.



**Fig. 4.** Venous congestion of intestinal loops during total clamping of the portal vein.

clamping levels. However, damage to vital organs during this period could not be excluded. One animal did not recover and died approximately 1.5 h after declamping the portal vein despite resuscitation measures. In this group, ammonia reached levels as high as 1,500  $\mu$ g/dl

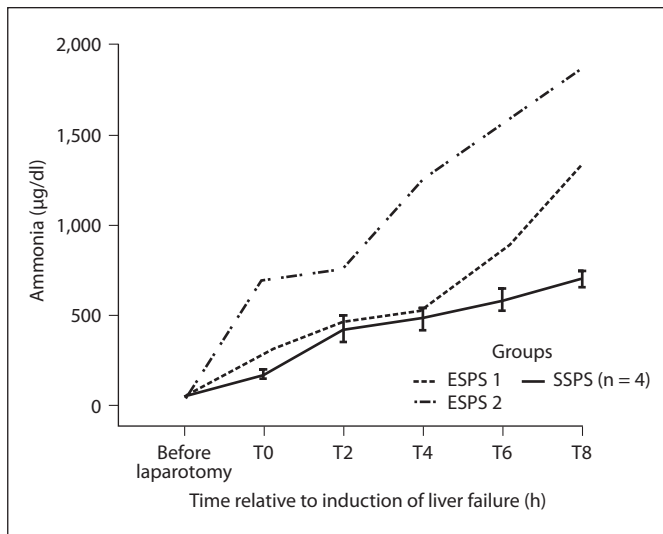
(fig. 5). The rise of ammonia was reflected in the increase in ICP (fig. 6). Other biochemical and hemodynamic abnormalities are shown in table 1.

After having performed the ESPS in 3 animals, we decided that this method did not achieve the desired goal of pure liver ischemia and therefore established the porta-caval shunt by SSPS in the remaining 4 animals.

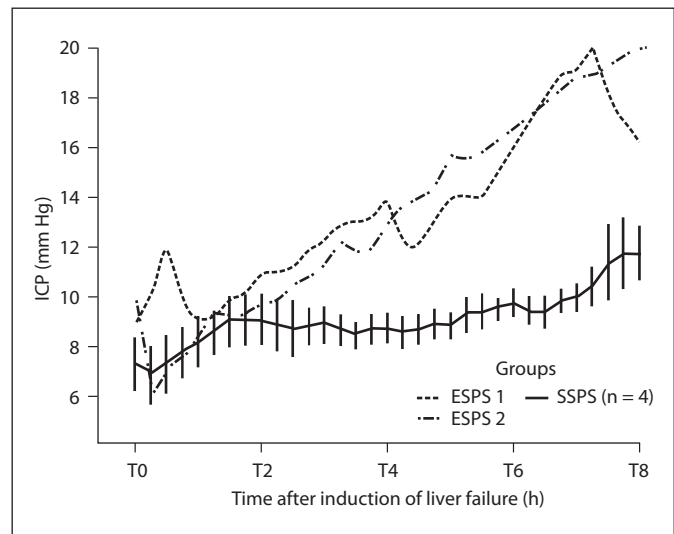
#### SSPS Group

**Surgery.** No severe drop in blood pressure was observed in the SSPS group despite a narrowing of the portal vein of up to 50% during partial portal clamping. In addition, no intestinal cyanosis or metabolic acidosis took place. The main biochemical and hemodynamic parameters of the SSPS group are shown in table 1.

**Hemodynamics.** The total infused fluids in the SSPS group was not constant during the experiments (fig. 7). Larger amounts were needed in the first 2 h according to PiCCO-directed therapy. Nevertheless, a fall in mean blood pressure ( $106 \pm 11$  mm Hg at T0 to  $43 \pm 6$  mm Hg at T8;  $p = 0.012$ ) could not be prevented as the fluid replacement had to be reduced due to increased lung water, i.e. elevation of the ELWI (from  $8 \pm 1$  ml/kg at T0 to  $10 \pm 1$  ml/kg at T8;  $p = 0.125$ ), despite the gradual reduction in GEDI (from  $619 \pm 41$  ml/m<sup>2</sup> at T0 to  $508 \pm 26$  ml/m<sup>2</sup>



**Fig. 5.** Ammonia metabolism seems to be more disturbed in animals with ESPS (interrupted lines) than in those with SSPS (uninterrupted line; means  $\pm$  SEM).



**Fig. 6.** Elevation of ICP in animals with ESPS (interrupted lines) and SSPS (uninterrupted line; means  $\pm$  SEM).

at T8;  $p = 0.054$ ). The fall in blood pressure was also accompanied by a significant fall in peripheral vascular resistance from  $1,559 \pm 321 \text{ dyn}\cdot\text{s}\cdot\text{m}^2\cdot\text{cm}^{-5}$  at T0 to  $762 \pm 65 \text{ dyn}\cdot\text{s}\cdot\text{m}^2\cdot\text{cm}^{-5}$  at T8;  $p = 0.036$ . Due to the fall in blood pressure there was hardly any elevation of ICP ( $7.6 \pm 1.1 \text{ mm Hg}$  at T0 to  $11.8 \pm 1.1 \text{ mm Hg}$  at T8;  $p = 0.019$ ), but the cerebral perfusion pressure (the difference between mean arterial pressure and ICP) fell from  $92 \pm 9$  to  $30 \pm 7 \text{ mm Hg}$  within 8 h ( $p = 0.009$ ). Compared to the other changes to the cardiovascular system, the changes in heart rate and cardiac index were only moderate and not significant.

**Biochemical Investigations.** Liver function tests confirmed the presence of liver failure. There was a significant elevation of glutamic oxaloacetic transaminase, alkaline phosphatase, bilirubin and ammonia (table 1). The quick value was reduced by  $>50\%$  within 8 h ( $117 \pm 1\%$  at T0 vs.  $50 \pm 5\%$  at T8;  $p < 0.001$ ). There was also a nonsignificant reduction in total serum proteins. The deterioration in urine production (from  $160 \pm 54 \text{ ml/h}$  to  $15 \pm 9 \text{ ml/h}$  within 8 h) was accompanied by an increase in serum creatinine ( $1.5 \pm 0.1 \text{ mg/dl}$  at T0 to  $2.3 \pm 0.1 \text{ mg/dl}$  at T8;  $p = 0.009$ ) and serum lactate ( $2.0 \pm 0.2 \text{ mmol/l}$  at T0 to  $2.8 \pm 0.9 \text{ mmol/l}$  at T8;  $p = 0.417$ ). Interestingly, vitamin B<sub>12</sub> concentrations had increased to  $>15$  times the initial values ( $78 \pm 5 \text{ pg/ml}$  at T0 vs.  $1,406 \pm 169 \text{ pg/ml}$  at T8;  $p = 0.004$ ), while vitamin A significantly decreased ( $17.3 \pm 2.6 \text{ µg/dl}$  at T0 vs.  $6.3 \pm 0.7 \text{ µg/dl}$  at T8;  $p = 0.031$ ).

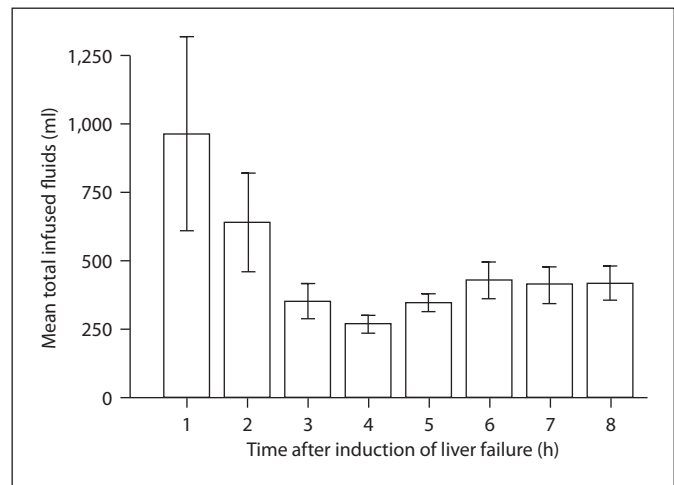
**Medical Management.** Hyperkalemia occurred in 2 distinct time periods:

- (1) 3–4 h after induction of liver ischemia, when large amounts of potassium were probably released from the necrotic hepatocytes; this was successfully treated with insulin injections;
- (2) later in the course of the experiments (after 6–7 h) as the conditions of the animals deteriorated and acidosis and renal failure developed; this type of hyperkalemia was rather resistant to even high doses of insulin.

In both cases, cardiac depression developed with a further decrease in hypotension, which necessitated therapy. The glucose infusion rates had to be constantly increased to keep the glucose levels on the desired level (fig. 8); 100–500 ml of sodium bicarbonate (1 mol/l) had to be administered to treat acidosis.

**Autopsy.** At autopsy, the liver showed massive centrilobular necrosis (fig. 9). Only a thin rim of surviving hepatocytes around the hepatic lobules could be seen. Whereas the extent of central necrosis was similar in the 2 groups, the animals in the ESPS group (where the bile duct was ligated) additionally showed bile duct infarcts in a subset of portal tracts, a feature never observed in the SSPS group (where no bile duct ligation was performed). The abdominal cavity was filled with large amounts of serosanguinous fluid. The portacaval shunts were patent.

**Fig. 7.** Total infused fluids during liver failure in the SSPS group. Whiskers: SEM.

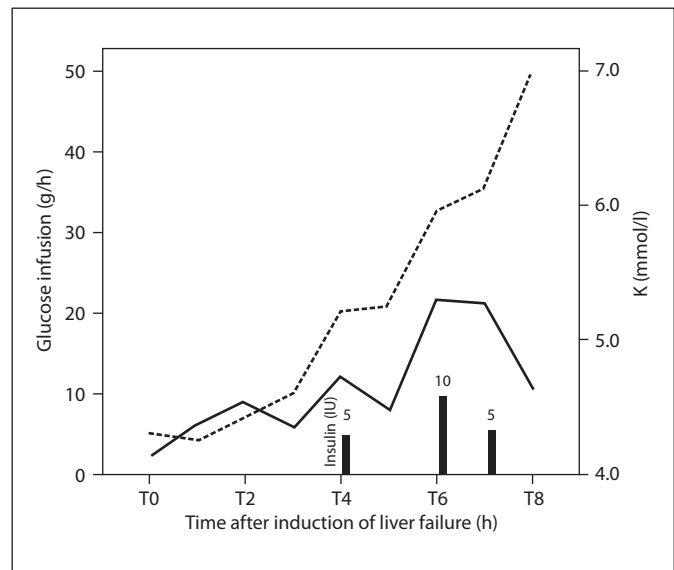


**Table 1.** Main biochemical and hemodynamic parameters in animals of ESPS group and in animals of SSPS group

	Before laparotomy		T0		T2	
	ESPS	SSPS	ESPS	SSPS	ESPS	SSPS
Heart rate, bpm	80, 68, 82	82 ± 7	193, 111, 185	78 ± 5	73, 85	88 ± 6
ICP, mm Hg	8.0, 7.5, 9.3	7.6 ± 1.1	9.0, 9.9, 11.2	7.3 ± 1.0	12.0, 9.7	9.1 ± 0.9
Mean arterial pressure, mm Hg	102, 103, 104	100 ± 8	43, 51, 60	106 ± 11	81, 63	67 ± 8
Cerebral perfusion pressure, mm Hg	94, 96, 95	92 ± 9	34, 41, 49	99 ± 12	69, 53	58 ± 9
CI, l/min/m <sup>2</sup>	4.25, 5.42, 5.70	5.05 ± 0.21	5.98, 3.35, 3.71	4.66 ± 0.24	6.14, 4.92	4.97 ± 0.16
ELWI, ml/kg	6, 9, 9	7 ± 0	13, 8, 6	8 ± 1	13, 9	9 ± 1
GEDI, ml/m <sup>2</sup>	598, 727, 706	573 ± 17	954, 462, 596	619 ± 41	863, 558	563 ± 35
SVRI, dyn·s·m <sup>2</sup> ·cm <sup>-5</sup>	1,550, 1,554, 1,448	1,358 ± 108	1,105, 1,268, 2,031	1,559 ± 321	878, 1,501	1,188 ± 91
pH	7.40, 7.42, 7.47	7.46 ± 0.02	7.32, 7.29, 7.32	7.42 ± 0.02	7.46, 7.37	7.41 ± 0.03
pCO <sub>2</sub> , mm Hg	47, 41, 41	40 ± 1	34, 47, 34	45 ± 2	45, 56	47 ± 4
HCO <sub>3</sub> <sup>-</sup> , mmol/l	29, 27, 29	28 ± 1	20, 23, 20	29 ± 1	32, 32	29 ± 0.4
Base excess, mmol/l	4, 2, 5	4 ± 1	-5, -3, -5	4 ± 1	8, 6	4 ± 0.3
Hematocrit, %	27, 29, 37	29 ± 1	28, 30, 24	29 ± 1	29, 27	30 ± 2
Na <sup>+</sup> , mmol/l	141, 137, 137	140 ± 1	148, 138, 137	136 ± 1	149, 137	135 ± 1
K <sup>+</sup> , mmol/l	4.2, 3.8, 3.9	3.8 ± 0.1	4.0, 4.3, 4.0	4.4 ± 0.1	4.3, 4.9	4.5 ± 0.2
Cl <sup>-</sup> , mmol/l	107, 106, 103	106 ± 1	107, 107, 108	103 ± 2	106, 103	103 ± 2
Anion gap, mmol/l	9, 8, 9	10 ± 0.4	25, 12, 13	9 ± 1	15, 7	9 ± 1
Glucose, mg/dl	108, 66, 97	76 ± 10	133, 105, 76	110 ± 5	140, 92	112 ± 12
Creatinine, mg/dl	1.7, 1.2, 1.4	1.5 ± 0.04	1.6, 1.4, 1.4	1.5 ± 0.1	1.6, 1.4	1.5 ± 0.1
Blood urea nitrogen, mg/dl	17, 15, 10	9 ± 1	13, 15, 11	9 ± 1	12, 14	9 ± 1
Alkaline phosphatase, U/l	149, 149, 149	134 ± 18	163, 173, 147	137 ± 17	189, 208	171 ± 14
Total bilirubin, mg/dl	0.1, 0.2, 0.2	0.2 ± 0.03	0.4, 0.3, 0.2	0.2 ± 0.03	0.3, 0.8	0.35 ± 0.1
GOT, U/l	23, 28, 20	23 ± 2	40, 67, 78	26 ± 2	186, 325	463 ± 352
Lactate, mmol/l	2.6, 2.1, 0.7	1.8 ± 0.8	5.6, 5.5, 3.2	2.0 ± 0.2	3.6, 3.9	2.3 ± 0.2
Ammonia, µg/dl	43, 37, 64	53 ± 4	292, 694, 177	166 ± 19	461, 756	417 ± 71
Total protein, g/dl	5.30, 5.00, 5.20	5.60 ± 0.20	4.50, 5.00, 4.10	5.55 ± 0.22	4.30, 5.00	5.55 ± 0.22
Quick value, %	104, 114, 104	110 ± 2	114, 120, 104	117 ± 1	105, 113	112 ± 3
Fibrinogen, mg/dl	386, 621, 341	540 ± 70	386, 595, 265	550 ± 77	335, 488	548 ± 81
INR	1.0, 0.9, 1.0	0.9 ± 0.02	0.9, 0.9, 1.0	0.9 ± 0.03	1.0, 0.9	0.9 ± 0.03
Vitamin A, µg/dl				17.3 ± 2.6		
Vitamin B <sub>12</sub> , pg/ml				78 ± 5		

In the ESPS columns, figures denote individual values for ESPS 1, ESPS 2 and ESPS 3, respectively. Animal ESPS 3 died approximately 1.5 h after portal vein declamping. Values for the SSPS group denote means ± SEM. CI = Cardiac index; SVRI = systemic vascular resistance index; GOT = glutamic oxaloacetic transaminase; INR = international normalized ratio.

**Fig. 8.** Treatment of hyperkalemia with insulin-glucose therapy in 1 experiment. Glucose infusion (interrupted line) and insulin injections (bars) successfully corrected the potassium level (uninterrupted line).



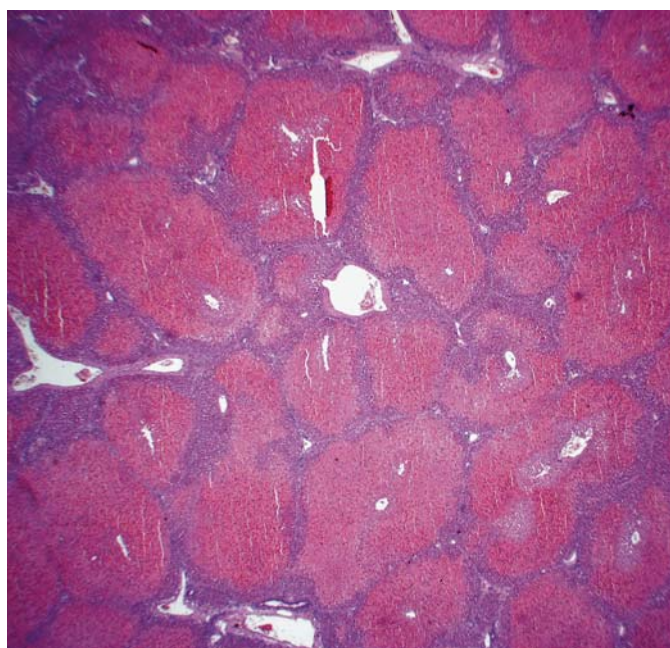
T4		T6		T8		p (T0 vs. T8 for SSPS group)
ESPS	SSPS	ESPS	SSPS	ESPS	SSPS	
99, 79	83 ± 4	161, 78	81 ± 5	205, 73	74 ± 6	0.716
14.0, 12.6	8.8 ± 0.6	19.0, 16.7	9.8 ± 0.5	17.0, 20.0	11.8 ± 1.1	0.019
73, 55	55 ± 2	68, 47	45 ± 2	51, 39	43 ± 6	0.012
59, 42	46 ± 3	49, 30	35 ± 2	34, 19	30 ± 7	0.009
7.22, 5.47	4.38 ± 0.37	7.06, 5.04	4.63 ± 0.26	2.92, 4.87	4.11 ± 0.19	0.255
15, 9	9 ± 1	12, 9	10 ± 1	12, 10	10 ± 1	0.058
766, 578	409 ± 120	619, 558	538 ± 24	451, 580	508 ± 26	0.054
731, 823	985 ± 55	632, 704	800 ± 36	589, 671	762 ± 65	0.036
7.47, 7.34	7.39 ± 0.04	7.52, 7.34	7.38 ± 0.03	7.47, 7.35	7.37 ± 0.04	0.069
44, 62	47 ± 3	38, 66	51 ± 2	42, 63	54 ± 3	0.002
33, 33	28 ± 1	32, 35	30 ± 2	31, 34	30 ± 1	0.388
9, 6	3 ± 2	9, 8	4 ± 2	7, 7	4 ± 1	0.927
30, 24	29 ± 1	31, 23	28 ± 2	31, 22	26 ± 1.2	0.151
147, 136	137 ± 2	148, 135	138 ± 2	155, 132	134 ± 1	0.004
4.1, 4.8	4.7 ± 0.5	4.1, 4.5	5 ± 0.7	4.9, 5.0	4.9 ± 0.4	0.285
106, 106	106 ± 2	108, 104	107 ± 2	100, 103	103 ± 2	0.391
12, 2	9 ± 1	12, 0	8 ± 1	29, 1	6 ± 1	0.011
76, 123	99 ± 14	62, 133	103 ± 18	74, 134	165 ± 61	0.392
1.7, 1.5	1.6 ± 0.1	1.8, 1.7	1.9 ± 0.1	2.2, 2.2	2.3 ± 0.1	0.009
12, 13	9 ± 1	11, 13	9 ± 1	18, 13	10 ± 1	0.339
208, 238	214 ± 9	266, 273	241 ± 10	360, 298	287 ± 15	<0.001
0.4, 1.1	0.7 ± 0.1	0.7, 1.0	0.7 ± 0.1	0.8, 1.2	0.8 ± 0.1	0.018
2,441, 666	1,543 ± 955	4,861, 808	1,964 ± 834	5,266, 893	2,417 ± 831	0.05
1.9, 2.1	2.0 ± 0.3	1.8, 2.2	2.0 ± 0.12	4.2, 2.3	2.8 ± 0.9	0.417
516, 1,249	477 ± 59	851, 1,544	583 ± 60	1,326, 1,864	698 ± 43	<0.001
4.60, 5.10	5.27 ± 0.09	4.90, 4.80	5.17 ± 0.19	4.60, 4.10	4.70 ± 0.54	0.245
61, 77	81 ± 11	53, 60	58 ± 3	37, 60	50 ± 5	<0.001
259, 440	466 ± 63	241, 391	409 ± 71	224, 348	404 ± 63	0.054
1.3, 1.2	1.1 ± 0.1	1.5, 1.4	1.4 ± 0.1	2.0, 1.4	1.6 ± 0.2	0.018
	10.5 ± 1.7				6.3 ± 0.7	0.031
	567 ± 125				1,406 ± 169	0.004



**Table 2.** Surgical large animal models used to test liver support systems

Investigators	Year	Animals	Weight, kg	Animal model	Liver support systems tested
Ash et al. [15]	1993	dogs	not mentioned by authors	two-stage total ischemic liver failure (ESPS)	Biologic-DT
Rozga et al. [16]	1994	dogs	15–20	two-stage total ischemic liver failure (ESPS)	BAL
Flendrig et al. [17]	1999	pigs	35	one-stage total ischemic liver failure (ESPS)	AMC-BAL
Kamohara et al. [18]	2000	pigs	20	total ischemic liver failure	BAL
Desille et al. [19]	2001	pigs	20–30	one-stage total ischemic liver failure (ESPS)	BAL
Khalili et al. [20]	2001	pigs	40–60	two-stage total ischemic liver failure (ESPS)	BAL
Gerlach et al. [21]	2001	pigs	70	hepatectomy	BAL
Desille et al. [22]	2002	pigs	20–30	one-stage total ischemic liver failure (ESPS)	BAL
Sosef et al. [23]	2002	pigs	37–57	hepatectomy	AMC-BAL
Abrahamse et al. [24]	2002	pigs	40–60	hepatectomy	BAL
Chen et al. [25]	2003	dogs	10–15	ESPS + bile duct ligation	BAL
Frühauf et al. [26]	2004	pigs	20–25	hepatectomy	BAL
Gao et al. [27]	2005	pigs	15–20	two-stage total ischemic liver failure (ESPS)	BAL
Sen et al. [28]	2006	pigs	23–30	one-stage total ischemic liver failure (ESPS)	MARS®
Rozga et al. [29]	2006	pigs	40–60	two-stage total ischemic liver failure (ESPS)	SEPET™
Ryska et al. [30]	2009	pigs	35–40	one-stage total ischemic liver failure (ESPS)	Prometheus®

BAL: bioartificial liver.



**Fig. 9.** Liver histopathology in an animal with ALF in the SSPS group. A thin rim of surviving hepatocytes around hepatic lobules can be identified.

**Table 3.** Total clamping time of the portal vein as reported by different investigators

Investigators	Year	Ischemia time, min
Huguet et al. [14]	1972	12 (range: 6–19)
Ytrebo et al. [10]	2002	11–15
Frühauf et al. [7]	2004	18 ± 4 <sup>1</sup>
Nieuwoudt et al. [5]	2006	18

<sup>1</sup> Mean ± SD.

**Table 4.** Advantages of SSPS over ESPS

Reproducibility
Avoidance of nonhepatic complications like
Injury to intestine
Severe hypotension during total clamping of portal vein
Multiorgan failure
Larger therapeutic window

## Discussion

The devascularization model of ALF is one of the most common animal models used to test new liver support systems (table 2). However, during total clamping of the portal vein to prepare for ESPS, the blood pressure sinks to levels which could damage other organs (the procedure deprives the heart of a large amount of venous return). In addition, the intestine becomes dark blue due to venous congestion, jeopardizing intestinal wall integrity. This may last for 10–25 min depending on the size of the animal (table 3). Severe metabolic acidosis also quickly develops. Therefore, establishing an ESPS in the model of ALF results in a mixture of liver failure, hypotensive shock and disturbance of the blood supply of the gut, which increases toxins like ammonia. All these factors, we assume, may explain the very high levels of ammonia accompanying ESPS compared to the less elevated levels in SSPS. As a result, the ICP – as would be expected from the role of ammonia in the development of cerebral edema – increased to higher levels. Despite the small sample size and the need for larger studies to support our conclusions, we decided after only three experiments to abandon the ESPS model as our results were in line with those in the literature [12, 13]. By avoiding ESPS-induced non-hepatic complications, the animal model with SSPS represents a far more pure liver ischemia (table 4) and has longer survival periods. A therapeutic window is created that enhances the testing of liver support systems or other treatments. In addition, no catecholamines should be used to support the circulation during portal vein clamping. Keeping the bile duct intact excludes the effects of cholestasis and allows some blood supply to the liver through the cystic artery, which probably results in the prolongation of survival [3].

The method of first establishing an SSPS followed by ligation of the portal vein and hepatic artery in one-stage surgery was described by other investigators [12, 13]. They performed SSPS with the explicit intention of avoiding splanchnic congestion and maintaining portal venous flow. However, in both studies, the bile duct was ligated and the animals regained consciousness after surgery.

For the definition of best medical management, we used the best applicable standards for the treatment of ALF in man [31] and wrote standard operating procedures, which was very important for the standardization of treatment. This is necessary to get a reproducible model.

The elevation of liver enzyme values and the accumulation of surrogate markers like bilirubin and ammonia accompanied by coagulation abnormalities (international normalized ratio >1.5) confirmed the ischemia-induced hepatic necrosis. Interestingly, in addition to the periportal area, the outmost layers of the hepatic lobules consisting of pericentral hepatocytes were spared from ischemic necrosis. These are probably supported by the backflow of blood from the caudal vena cava to the hepatic veins [32, 33], also allowing a washout of cellular components like vitamin B<sub>12</sub>. The very high concentrations of vitamin B<sub>12</sub> associated with hepatocyte necrosis have previously been described clinically and in animal models [34–36]. Low levels of plasma vitamin A, on the other hand, can be attributed to a diminished release of binding proteins, i.e. failure of mobilization from the liver by retinol-binding protein, which has a very short half-life (approx. 10 h) [37, 38]. Not only the impaired synthesis of proteins but also the disruption of capillary membranes (capillary leak) contributed to the reduction in serum levels of coagulation factors and fibrinogen, which may have ‘disappeared’ in the extracellular fluid compartment, therefore complicating the picture of coagulopathy. This allows two conclusions: (1) the capillary leak may greatly contribute to the imbalance in coagulation factors, and, as a consequence, (2) diminishing the capillary leak would also contribute to a better control of coagulation factors in patients with ALF.

It is therefore essential to use invasive monitoring methods (like the PiCCO system) as only by these methods, the shift of fluids from one compartment to the other can be evaluated. Infusion of large amounts of crystalloids supports the circulatory system and prevents renal failure for as long as possible. However, the animal may quickly develop pulmonary edema. A goal-directed fluid therapy with the PiCCO is therefore advantageous, and the administration of fixed amounts of fluids should not be an option in models of liver failure.

The maintenance of optimal blood glucose concentrations was only possible by frequent monitoring (every 0.5–1 h), especially as these animals needed increasing amounts of glucose in the course of the experiments to compensate for impaired glycogen catabolism. Glucose monitoring also enabled the correction of potassium levels when insulin had to be administered. Other alternative methods that can be used to treat hyperkalemia include alkalinization of blood with sodium bicarbonate or the intravenous injection of terbutaline (Bricanyl®). The latter can be complicated by cardiac arrhythmias and

myocardial depression. The values for blood pH, pCO<sub>2</sub> and base excess measured before induction of liver failure were higher than those considered normal in man. This is important when adjustment of ventilator settings and administration of bicarbonate to treat acidosis are considered.

In the animal model with SSPS, we noticed neither a hyperdynamic circulation nor any large elevations of ICP. The cardiac index was relatively constant and the heart rate did not show any significant changes. The systemic vascular resistance index, however, showed a continuous reduction, and this can be associated with the falls in blood pressure and cerebral perfusion pressure. It is therefore more likely that death would result from cardiac failure and deficient blood supply to the brain rather than from a cerebral herniation.

The complete devascularization model actually produces a hyper-ALF. A subacute model that lasts for 2–4 weeks would be a more suitable model as it would allow

the accumulation of protein-bound toxins. An opportunity is provided to predict the optimal detoxification doses of liver support systems, and to evaluate their efficacy in terms of improvement of survival and multiorgan system failure.

### Acknowledgments

The authors gratefully acknowledge the financial support from the Bavarian Research Foundation (Bayerische Forschungstiftung) for the project 'patal'. We are deeply thankful to the personnel at the Center for Preclinical Research, Klinikum rechts der Isar, for their support and cooperation. We also express our deep gratitude for the precious guidance by Prof. Pieter Evenepoel, Prof. Frederik Nevens and Prof. Xavier Rogiers.

### Disclosure Statement

The authors declare that they have no conflicts of interest.

### References

- 1 Terblanche J, Hickman R: Animal models of fulminant hepatic failure. *Dig Dis Sci* 1991; 36:770–774.
- 2 Newsome PN, Plevris JN, Nelson LJ, Hayes PC: Animal models of fulminant hepatic failure: a critical evaluation. *Liver Transpl* 2000;6:21–31.
- 3 Fourneau I, Pirenne J, Roskams T, Yap SH: An improved model of acute liver failure based on transient ischemia of the liver. *Arch Surg* 2000;135:1183–1189.
- 4 Filippini F, Mosca F: Animal models of fulminant hepatic failure: need to test liver support devices. *Dig Liver Dis* 2001;33:607–613.
- 5 Nieuwoudt M, Kunnike R, Smuts M, Becker J, Stegmann GF, van der Walt C, Nesor J, van der Merwe S: Standardization criteria for an ischemic surgical model of acute hepatic failure in pigs. *Biomaterials* 2006;27:3836–3845.
- 6 Filippini F, Boggi U, Meacci L, Burchielli S, Vistoli F, Bellini R, Protta C, Colizzi L, Kusmic C, Campani D, Gneri C, Trivella MG, Mosca F: A new technique for total hepatectomy in the pig for testing liver support devices. *Surgery* 1999;125:448–455.
- 7 Frühauf NR, Oldhafer KJ, Westermann S, Sotiropoulos GC, Kaiser GM: Acute hepatic failure in swine: hepatectomy versus vascular occlusion. *J Invest Surg* 2004;17:163–171.
- 8 Rappaport AM, MacDonald MH, Borowy ZJ: Hepatic coma following ischemia of the liver. *Surg Gynecol Obstet* 1953;97:748–762.
- 9 van de Kerkhove MP, Hoekstra R, van Gulik TM, Chamuleau RA: Large animal models of fulminant hepatic failure in artificial and bioartificial liver support research. *Biomaterials* 2004;25:1613–1625.
- 10 Ytrebo LM, Nedredal GI, Langbakk B, Revhaug A: An experimental large animal model for the assessment of bioartificial liver support systems in fulminant hepatic failure. *Scand J Gastroenterol* 2002;37:1077–1088.
- 11 Ryska M, Kieslichová E, Pantoflíček T, Ryska O, Zazula R, Skibová J, Hájek M: Devascularization surgical model of acute liver failure in minipigs. *Eur Surg Res* 2004;36:179–184.
- 12 Hanid MA, Mackenzie RL, Jenner RE, Chase RA, Mellon PJ, Trewby PN, Janota I, Davis M, Silk DB, Williams R: Intracranial pressure in pigs with surgically induced acute liver failure. *Gastroenterology* 1979;76:123–131.
- 13 Mazziotti A, Bernardi M, Antonini L, Dioguardi FS, Bellusci R, Papa V, Tacconi C, Gasbarrini G, Cavallari A, Possati L: Plasma amino acid patterns in experimental acute hepatic failure: comparison between hepatectomy and liver devascularization in pigs. *Surgery* 1981;90:527–534.
- 14 Huguet C, Opolon P, Bloch P, Gallot D, Morisot P, Hadchouel P: Experimental hepatic coma due to acute ischemic necrosis of the liver in swine (in French). *J Chir (Paris)* 1972; 103:63–76.
- 15 Ash SR, Carr DJ, Blake DE, Rainier JB, Demetriou AA, Rozga J: Effect of sorbent-based dialytic therapy with the BioLogic-DT on an experimental model of hepatic failure. *ASAIO J* 1993;39:M675–M680.
- 16 Rozga J, Podesta L, LePage E, Morsiani E, Moscioni AD, Hoffman A, Sher L, Villamil F, Woolf G, McGrath M, et al: A bioartificial liver to treat severe acute liver failure. *Ann Surg* 1994;219:538–544, discussion 544–546.
- 17 Flendrig LM, Calise F, di Florio E, Mancini A, Ceriello A, Santaniello W, Mezza E, Sicoli F, Belleza G, Bracco A, Cozzolino S, Scala D, Mazzone M, Fattore M, Gonzales E, Chamuleau RA: Significantly improved survival time in pigs with complete liver ischemia treated with a novel bioartificial liver. *Int J Artif Organs* 1999;22:701–709.
- 18 Kamohara Y, Tsutsumi R, Kawazoe Y, Miyamoto S, Moriuchi H, Tamura T, Eguchi S, Miyawashita Y, Azuma T, Fujioka H, Furui J, Kanematsu T: Effect of bioartificial liver in pigs with total ischemic liver failure. *Transplant Proc* 2000;32:2343–2344.
- 19 Desille M, Frémond B, Mahler S, Mallédant Y, Seguin P, Bouix A, Lebreton Y, Desbois J, Campion JP, Clément B: Improvement of the neurological status of pigs with acute liver failure by hepatocytes immobilized in alginate gel beads inoculated in an extracorporeal bioartificial liver. *Transplant Proc* 2001; 33:1932–1934.

- 20 Khalili TM, Navarro A, Ting P, Kamohara Y, Arkadopoulos N, Solomon BA, Demetriou AA, Rozga J: Bioartificial liver treatment prolongs survival and lowers intracranial pressure in pigs with fulminant hepatic failure. *Artif Organs* 2001;25:566–570.
- 21 Gerlach JC, Botsch M, Kardassis D, Lemmens P, Schön M, Janke J, Puhl G, Unger J, Kraemer M, Busse B, Böhmer C, Belal R, Ingenlath M, Kosan M, Kosan B, Sültmann J, Patzold A, Tietze S, Rossaint R, Müller C, Mönch E, Sauer IM, Neuhaus P: Experimental evaluation of a cell module for hybrid liver support. *Int J Artif Organs* 2001;24:793–798.
- 22 Desille M, Mahler S, Seguin P, Mallédant Y, Frémond B, Sébille V, Bouix A, Desjardins JF, Joly A, Desbois J, Lebreton Y, Campion JP, Clément B: Reduced encephalopathy in pigs with ischemia-induced acute hepatic failure treated with a bioartificial liver containing alginate-entrapped hepatocytes. *Crit Care Med* 2002;30:658–663.
- 23 Sosef MN, Abrahamse LS, van de Kerkhove MP, Hartman R, Chamuleau RA, van Gulik TM: Assessment of the AMC-bioartificial liver in the anhepatic pig. *Transplantation* 2002;73:204–209.
- 24 Abrahamse SL, van de Kerkhove MP, Sosef MN, Hartman R, Chamuleau RA, van Gulik TM: Treatment of acute liver failure in pigs reduces hepatocyte function in a bioartificial liver support system. *Int J Artif Organs* 2002;25:966–974.
- 25 Chen Z, Ding Y, Xu Q, Yu D: Bioartificial liver inoculated with porcine hepatocyte spheroids for treatment of canine acute liver failure model. *Artif Organs* 2003;27:613–622.
- 26 Frühauf NR, Oldhafer KJ, Höltje M, Kaiser GM, Frühauf JH, Stavrou GA, Bader A, Broelsch CE: A bioartificial liver support system using primary hepatocytes: a preclinical study in a new porcine hepatectomy model. *Surgery* 2004;136:47–56.
- 27 Gao Y, Mu N, Xu XP, Wang Y: Porcine acute liver failure model established by two-phase surgery and treated with hollow fiber bioartificial liver support system. *World J Gastroenterol* 2005;11:5468–5474.
- 28 Sen S, Rose C, Ytrebo LM, Davies NA, Nedredal GI, Drevland SS, Kjonno M, Prinzen FW, Hodges SJ, Deutz NE, Williams R, Butterworth RF, Revhaug A, Jalan R: Effect of albumin dialysis on intracranial pressure increase in pigs with acute liver failure: a randomized study. *Crit Care Med* 2006;34:158–164.
- 29 Rozga J, Umehara Y, Trofimenko A, Sadahiro T, Demetriou AA: A novel plasma filtration therapy for hepatic failure: preclinical studies. *Ther Apher Dial* 2006;10:138–144.
- 30 Ryska M, Laszliková E, Pantoflíček T, Ryska O, Prazak J, Koblihová E: Fractionated plasma separation and adsorption significantly decreases intracranial pressure in acute liver failure: experimental study. *Eur Surg Res* 2009;42:230–235.
- 31 Polson J, Lee WM, American Association for the Study of Liver Disease: AASLD position paper: the management of acute liver failure. *Hepatology* 2005;41:1179–1197.
- 32 Smyrniotis V, Kostopanagiotou G, Lolis E, Theodoraki K, Farantos C, Andreadou I, Polymeneas G, Genatas C, Contis J: Effects of hepatovenous back flow on ischemic-reperfusion injuries in liver resections with the Pringle maneuver. *J Am Coll Surg* 2003;197:949–954.
- 33 Tatsuma T, Kim YI, Kai T, Ishii T, Akizuki S, Takayama F, Egashira T, Kobayashi M: Importance of hepatovenous back-perfusion for maintenance of liver viability during the Pringle manoeuvre. *Br J Surg* 1995;82:1071–1075.
- 34 Auzepy P, Bourdon G, Fauvert R: Study of the hepatic release of vitamin B<sub>12</sub> labeled by cobalt 60 in the course of experimental necrosis due to carbon tetrachloride (in French). *Rev Fr Etud Clin Biol* 1959;4:1036–1038.
- 35 Mackay IR, Cowling DC, Gray A: Highly raised serum vitamin B<sub>12</sub> levels in obstructive hepatic necrosis. *BMJ* 1957;2:800–801.
- 36 Holdsworth CD, Atkinson M, Dossett JA, Hall R: An assessment of the diagnostic and prognostic value of serum vitamin B<sub>12</sub> levels in liver disease. *Gut* 1964;5:601–606.
- 37 Janczewska I, Ericzon BG, Eriksson LS: Influence of orthotopic liver transplantation on serum vitamin A levels in patients with chronic liver disease. *Scand J Gastroenterol* 1995;30:68–71.
- 38 Goode HF, Webster NR, Howdle PD, Leek JP, Lodge JP, Sadek SA, Walker BE: Reperfusion injury, antioxidants and hemodynamics during orthotopic liver transplantation. *Hepatology* 1994;19:354–359.