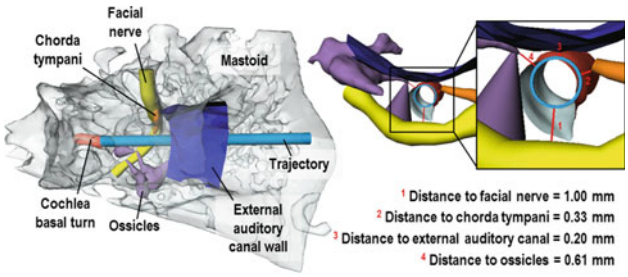

Fig. 1 Trajectory definition (*left*). Minimum distances to structures (*right*)

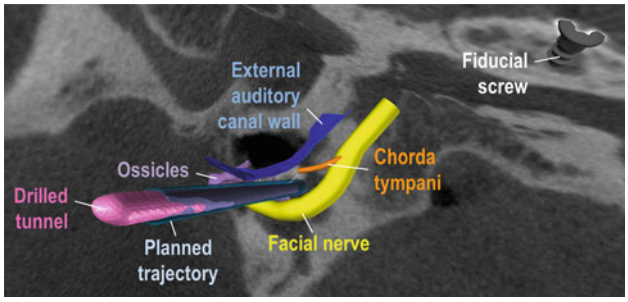

Fig. 2 DCA drilling result with drilled trajectory segmented with Amira and overlayed on the preoperative plan created with the proposed planning software tool

trajectory. Postoperative CBCT data was registered to preoperative planning data to determine the final accuracy of the drilled tunnel.

Results

The mean error at the entrance and target was found to be 0.06 ± 0.04 mm and 0.28 ± 0.09 mm ($N = 3$) respectively. Within the postoperative images, it was observed that all vital anatomy was preserved (refer to Fig. 2).

Conclusion

Within this work we proposed a surgical planning software tool for a robotically performed DCA that enables safe trajectory planning and sufficiently accurate patient-to-image registration. The proposed planning software tool enabled an effective DCA to be drilled with preservation of all structures during the initial cadaver evaluation, demonstrating that the 1 mm safety margin to the facial nerve inclusive of TRE was sufficient.

Feasibility of detection of the facial nerve using EMG during robotic direct cochlear access

J. Anso[1], B. Bell[1], N. Gerber[1], T. Williamson[1], K. Gavaghan[1], M. Caversaccio[2], S. Weber[1]
[1]ARTORG Center for Biomedical Engineering, University of Bern, Switzerland
[2]Department of ENT, Head and Neck Surgery, Inselspital, University of Bern, Switzerland

Keywords Facial nerve · EMG Direct cochlear access · Image guided therapy

Purpose

Direct cochlear access (DCA) is an image-guided minimally invasive surgical procedure which creates a small diameter tunnel to the middle ear cavity and thereby foregoes the necessity of the traditional mastoidectomy. High accuracy image and mechanical guidance are necessary to avoid several risk structures in the region of the DCA [1]. Several such navigation systems have been reported to date including stereotactic frames [2] and industrial [3] or use-specific robot systems [4]. Although several of these works have produced clinically acceptable levels of technical accuracy, errors which remain undetected at any of the various stages of the workflow can compromise the safety and efficacy of the intervention. Thus, a need exists for intraoperative error detection.

The facial nerve (FN) is the key structure at risk during the DCA process. Electroneurography (ENG) was targeted as a possible method of ensuring the safety of the FN during the drilling procedure. In short, electroneurography utilizes electromyography (EMG) to detect muscle contraction in response to a stimulation of a motor nerve by a current injected through a suitable probe in close proximity. As the stimulatory response is directly dependent on current density, the proximity of the probe to the nerve could potentially be estimated. Bernardeschi et al. tested the ability of a drill-integrated ENG system to give an early warning of impending contact with the FN [5]. Drilling was stopped immediately following a warning from the system, and the remaining thickness of the bony canal surrounding the nerve was evaluated in postoperative CT analysis. This analysis showed that the sensitivity of the system was to low (zero bone thickness in several instances) to be useful for DCA.

In this work we present the initial results of a live animal study where an ENG enabled drill was used in conjunction with a surgical robot system to accurately correlate the distance to the FN with the EMG stimulation intensity.

Materials and methods

The main components of the integrated system are a 5 DOF serial kinematic surgical robot, controlled by a surgical navigation system and which is connected to an ENG stimulation drill and monitor (Stimbur/NIM 3.0, Medtronic, USA). A data interface (DAQ-NI 6215, National Instruments, USA) between the stimulation monitor and the navigation system allows exchange of stimulation and EMG signals which are then correlated with the tool position in the navigation system.

EMG data was collected from live animal surgeries which closely mimic the image-guided and robot assisted DCA procedure in humans. This surgical workflow includes: High resolution imaging, computer assisted planning of the intervention, patient-image registration, and finally the robotic assisted intervention where a small diameter tunnel is drilled to the middle ear cavity. Four surgeries on sheep were conducted following the proposed image guided workflow under the approval of the local animal protection commission (approval number 56/10). An appropriate anaesthetic protocol was designed to minimize pain in the subjects yet maintain muscle activity (for premedication diazepam 0.1 mg/kg and Butorphanol 0.1 mg/kg IV; general anaesthesia with thiopental 2.5 % IV; maintenance of anaesthesia with Isoflurane in 100 % oxygen; ringers Lactate Solution at a rate of 10 ml/kg/h). After gaining surgical access to the mastoid region four 1.5×3 mm titanium screws (M-5220.03, Medartis, Switzerland) were inserted in the temporal bone for later image registration. The temporal bone was imaged at $0.75 \times 0.5 \times 0.5$ mm^3 using a 16-slice scanner (Brilliance, Philips AG). Using a purpose built software planning tool, up to 9 parallel trajectories were planned at varying distances (0, 0.5 and 1 mm) from the facial nerve and transferred to the robot system.

After imaging, the animal was placed on the OR table with the surgical robot mounted. After fixing a reference tracker and the EMG electrodes (Orbicularis Oris and Oculi or Auricularis) the head was registered by localizing the implanted fiducial screws. Finally, the planned trajectories were drilled using a standard surgical 1.6 mm twist drill while simultaneously stimulating at a rate of 4 Hz with the stimulation intensity ramping from 1.5 to 2.5 mA (0.5 mA steps) and back continually throughout the drilling.

Postoperatively, the recorded EMG signals were mapped in respect to distances from the drill bit to the facial nerve using the actual position of the drilled trajectory from postopterative cone beam

source: https://doi.org/10.48350/68421 | downloaded: 12.10.2024

CT scans (ProMax, Planmeca Oy, Finland) with a final isometric voxel size of $(0.15\ mm)^3$.

Results

Four different subjects were drilled in this pilot study. Three of them presented acceptable levels of EMG signal to noise ratio (subjects 1, 3, 4), whereas one was too noisy due to a technical malfunction (subject 2). A high registration error appeared in subject 3 (later determined to be an imaging artifact) affecting the accuracy of the tunnels. A total of 11 trajectories were pre-selected for further evaluation. Distances to first EMG response was evaluated for these trajectories (see Table 1). In Fig. 1, an example of an EMG mapping (subject 1) versus distance to FN is presented for the different stimulation intensities. An offset value representing the lateral distance from the center of the FN to the center of the trajectory is also represented.

Table 1 Summary of distances to FN at first EMG response for the three different evaluated intensities

Subject	Trajectory	Offset (mm)[a]	Distance at first EMG response (mm)[b]		
			1.5 mA	2.0 mA	2.5 mA
1	1	2.5	NR	1.4	1.9
	2	2.2	NR	1.0	1.0
	3	0.1	NR	NR	0.4
3	4	1.6	2.1	0.1	0.0[c]
	5	0.9	NR	0.0[c]	0.0[c]
	6	0.9	NR	0.0[c]	0.0[c]
4	7	1.7	0.0	0.0[c]	0.5
	8	1.5	NR	NR	NR
	9	0.4	NR	0.0[c]	0.0[c]
	10	0.3	0.0	0.0[c]	0.0[c]
	11	0.1	NR	NR	NR

NR no response

[a] Shortest distance from the axis of the drilled tunnel to the centre of FN

[b] Shortest distance from the drill bit surface to the FN surface at first EMG response

[c] Penetration of the FN at first EMG response

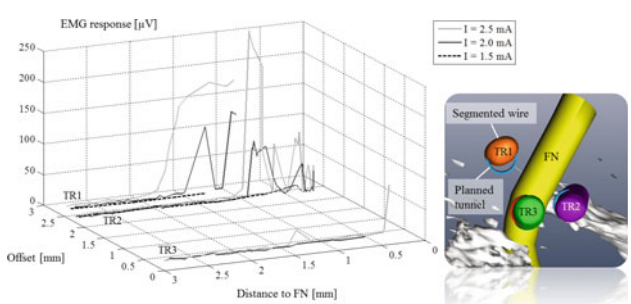

Fig. 1 3D representation of the EMG data recorded for Subject 1 for each of the 3 drilled trajectories. The postoperative calibrated distances from the drill bit to the facial nerve surface are labeled as distance to FN. The shortest distances from the drill bit axis to the center of the FN are labeled as offset. In the 3D scene, the planned tunnels, the postop segmented trajectories (*orange*, *green* and *purple*) and the FN are represented

Conclusions

Interestingly, trajectories intersecting the FN (shortest offsets) did not produce an early response in most cases. Additionally, stimulation currents at 1.5 were not sensitive enough to produce EMG response in most of the cases. Only the stimulations at 2.5 and 2.0 mA produced early responses in some more cases. These results showed that the level of sensitivity and specificity is not enough to ensure safety during robotic direct cochlear access with the current stimulation and drill bit tools. The future work will evaluate new drilling tools to increase stimulation sensitivity and specificity.

References

[1] Schipper J, Aschendorff A, Arapakis I, Klenzner T, Teszler CB, Ridder GJ, Laszig R (2004) Navigation as a quality management tool in cochlear implant surgery. J Laryngol Otol 118(10):764–770

[2] Labadie RF, Chodhury P, Cetinkaya E, Balachandran R, Haynes DS, Fenlon MR, Jusczyzck AS, Fitzpatrick JM (2005) Minimally invasive, image-guided, facial-recess approach to the middle ear: demonstration of the concept of percutaneous cochlear access in vitro. Otol Neurotol 26(4):557–562

[3] Majdani O, Bartling SH, Leinung M, Stöver T, Lenarz M, Dullin C, Lenarz T (2008) A true minimally invasive approach for cochlear implantation: high accuracy in cranial base navigation through flat-panel-based volume computed tomography. Otol Neurotol 29(2):120–123

[4] Bell B, Stieger C, Gerber N, Arnold A, Nauer C, Hamacher V, Kompis M, Nolte L, Caversaccio M, Weber S (2012) A self-developed and constructed robot for minimally invasive cochlear implantation. Acta Otolaryngol, pp 1–6

[5] Bernardeschi D, Meskine N, Al Otaibi N, Ablonczy R, Kalamarides M, Grayeli AB, Sterkers O (2011) Continuous facial nerve stimulating burr for otologic surgeries. Otol Neurotol 32(8):1347–1351

Newly developed endoscopic surgical navigator demonstrating the position of the center in an endoscopic view

S. Yamamoto[1], H. Mineta[2]

[1]Hamamatsu University School of Medicine, Medical Photonics Research Center, Hamamatsu, Japan

[2]Hamamatsu University School of Medicine, Department of Otorhinolaryngology, Hamamatsu, Japan

Keywords Frameless navigator · Markerless navigator · Endoscopic sinus surgery · White light Scanner

Purpose

While endoscopic sinus surgery (ESS) has been widely used for the patients with sinusitis, nasal polyps, and tumors, some complications including blindness, double vision, and massive bleeding remain serious. To avoid them, surgical navigation during surgery is very useful. However, the available navigators for ESS remain to be developed, because they require the spherical markers on the surgical instruments. These markers may disturb the surgical procedures, since the spaces for ESS are narrow and are crowded with surgeons' hands and instruments. To resolve this problem, we have developed a new surgical navigator that demonstrates the position not of the instruments but of the center in endoscopic view on the computed tomography (CT) images.

Methods

To acquire the 3D data for registering patients' images and tracking instruments, a white light surface scanner, Fscan (Pulstec Industrial Co., Ltd., Hamamatsu, Japan) was used. Projecting modulated striped pattern using a white light of xenon lamp, this scanner provides the surface 3D data within 0.6 s with high resolution (0.1 mm in the Z-axis and 0.6 mm in the X- and Y-axes) and with high accuracy