Hindawi Publishing Corporation
Cardiology Research and Practice
Volume 2014, Article ID 179632, 8 pages
http://dx.doi.org/10.1155/2014/179632

Clinical Study

Characterization of Pulmonary Vein Dimensions Using High-Definition 64-Slice Computed Tomography prior to Radiofrequency Catheter Ablation for Atrial Fibrillation

Catherine Gebhard,[1,2] Nazmi Krasniqi,[1] Barbara E. Stähli,[1] Bernd Klaeser,[2] Tobias A. Fuchs,[2] Jelena R. Ghadri,[1,2] Laurent Haegeli,[1] Thomas F. Lüscher,[1,3] Philipp A. Kaufmann,[2,3] and Firat Duru[1,3]

[1] *Department of Cardiology, Cardiovascular Center, University Hospital Zurich, Rämistrasse 100, 8091 Zurich, Switzerland*
[2] *Department of Radiology, Cardiac Imaging, University Hospital Zurich, Rämistrasse 100, 8091 Zurich, Switzerland*
[3] *Zurich Center for Integrative Human Physiology (ZIHP), University of Zurich, Winterthurerstrasse 190, 8057 Zurich, Switzerland*

Correspondence should be addressed to Firat Duru; firat.duru@usz.ch

Received 14 December 2013; Accepted 26 May 2014; Published 25 June 2014

Academic Editor: Jesús M. Almendral

Copyright © 2014 Catherine Gebhard et al. This is an open access article distributed under the Creative Commons Attribution License, which permits unrestricted use, distribution, and reproduction in any medium, provided the original work is properly cited.

Background. Contrast-enhanced computed tomography is commonly acquired before radiofrequency catheter ablation (RFCA) for atrial fibrillation (AFib) to guide the procedure. We analyzed pulmonary vein (PV) ostial diameter and volumes on a high-definition 64-slice CT (HDCT) scanner in patients with AFib prior to RFCA. *Methods and Results*. This retrospective study included 50 patients (mean age 60.2 ± 11.4 years, 30 males) undergoing cardiac HDCT scanning before RFCA for drug refractory AFib and 50 age-, BMI-, and sex-matched controls with normal sinus rhythm undergoing HDCT. PV ostial diameter and volume were measured and calculated using a semiautomatic calliper tool. Total ostial PV volume was significantly increased in patients with AFib as compared to controls ($P < 0.005$). Similarly, total ostial PV diameter was significantly increased in AFib compared to controls ($P < 0.001$). In AFib, the largest PV volume and diameters were measured in right superior PV ($P < 0.05$ versus controls). The difference in PV volume between patients and controls was most pronounced in right superior PVs ($P = 0.015$). Right middle PVs were found more often in patients with AFib (16/50; 32%) than in normal subjects (7/50; 14%). *Conclusion*. Enlargement of PV ostial area and enlargement of volume are frequent findings in patients with drug refractory AFib. These parameters may add to the risk stratification for AFib recurrence following RFCA.

1. Introduction

Atrial fibrillation (AFib) is one of the most common arrhythmias with an increased prevalence with advancing age [1]. Pulmonary veins (PVs), in particular sleeves of atrial myocardium extending into the PVs, have been recognized as a major source of ectopic arrhythmogenic foci initiating AFib [2]. Pulmonary vein isolation by radiofrequency catheter ablation (RFCA) has become an effective and safe treatment option for selected patients with AFib [3, 4]. Accurate assessment of the anatomy of the PVs and the dimension of PV ostia is essential to optimize guidance of the ablation procedure [5, 6]. Cardiac computed tomography (CT) is an established imaging modality to visualize the posterior left atrium and the PV anatomy before RFCA [7, 8]. Indeed, PV ostial dimensions obtained by CT have been shown to correlate with those assessed by intracardiac echocardiography and venography [7] and introduction of high-definition CT (HDCT) may further improve such assessment.

Pulmonary vein anatomy is considered to play an important role in the initiation of AFib. Previous studies have shown that left atrial and PV remodeling including geometric alterations towards a round shape in the ostia of superior PVs occurs in patients with successful RFCA compared to

source: https://doi.org/10.7892/boris.69080 | downloaded: 10.5.2024

those with recurrence of AFib [9]. These findings suggest that morphologic alterations of PV anatomy, in particular enlargement of PVs, may alter PV arrythmogenicity and facilitate the induction of AFib. Indeed, variations in PV anatomy are more common in patients with AFib, and diameters of PV ostia are known to be larger [10]. However, the assessment of PV diameters may be hampered by the elliptical shape of PV ostia, and assessment of PV ostial area and volume may overcome this geometric difficulty.

Hence, the aim of this study was to assess whether total PV ostial diameter and volume assessed by HDCT are larger in patients with AFib prior to RFCA compared to controls with sinus rhythm (SR), as those parameters may provide a noninvasive tool for risk stratification of AFib recurrence after RFCA.

2. Methods

2.1. Patients. This retrospective study enrolled 50 consecutive patients undergoing HDCT before RFCA for drug refractory AFib and 50 controls matched for gender, age, and body mass index with normal SR who underwent clinically indicated contrast-enhanced cardiac HDCT scanning between July 2011 and June 2012. The need to obtain written informed consent in this study was waived by the institutional review board (local ethics committee) since, according to Swiss law on clinical investigations, informed consent is not required if the nature of the study is purely observational and includes solely clinical data collection. Indications for CT in patients with SR were typical ($n = 23$) or atypical angina ($n = 9$), dyspnoea ($n = 3$), positive stress test ($n = 8$), or preoperative risk evaluation ($n = 7$). Exclusion criteria for cardiac CT examination were renal failure (glomerular filtration rate <30 mL/min), known allergy to iodine contrast material, severe claustrophobia, and pregnancy. Baseline characteristics are summarized in Table 1.

2.2. Cardiac CT Acquisition. All scans were performed on a 64-HDCT scanner (Discovery HD 750, GE Healthcare) with prospective electrocardiogram (ECG) triggering (75% of RR-interval), a body surface area- (BSA-) adapted contrast media bolus (Visipaque, GE Healthcare, 40–125 mL, 3.5–5 mL/s) [11–13], and i.v. β-blockers, if needed, to achieve a heart rate lower than 65 beats per minute and 0.4 mg sublingual nitroglycerine was administered to the control group immediately before the study. Radiation dose was calculated from the dose-length product using a conversion factor of 0.014 mSv/(mGy/cm) [14]. The scanning parameters included 64 × 0.625 mm collimation, a rotation time of 0.35 s, and body mass index- (BMI-) adjusted tube voltage (100–120 kV) and current (450–700 mA). The Discovery CT 750 HD scanner is a high-definition CT scanner equipped with a Gemstone detector. Images were acquired in high resolution mode (230 μm) and reconstructed in high-definition mode (in plane resolution 0.23 × 0.23 mm, 2,496 views per rotation, and cardiac spatial resolution 18.2 lp/cm). Images were reconstructed by applying a blending factor of 30% of adaptive statistical iterative reconstruction (ASiR; GE Healthcare) according to clinical standards established in our institution.

Table 1: Patient characteristics (patient baseline and CT acquisition characteristics).

	AFib $n = 50$	SR $n = 50$
Male sex, number of patients (of total)	30 (50)	30 (50)
Age (years)	60 ± 11	59 ± 10
BMI (kg/m^2)	27.9 ± 4.6	27.2 ± 4.3
mSv	2.1 ± 0.3	2.0 ± 0.4
Heart rate (bpm)	55.5 ± 2.1	69.2 ± 1.2
Tube voltage (kV)	113 ± 1.2	115 ± 1.3
Tube current (mA)	645.7 ± 4.8	632.9 ± 5.0
Contrast volume (mL)	102.3 ± 1.8	89.3 ± 2.4
Beta-blocker (mg)	7.5 ± 1.4	0

Values are given as mean ± standard deviation (SD). BMI: body mass index; SR: sinus rhythm; AFib: atrial fibrillation.

ASiR is a modified iterative reconstruction algorithm that models the photon statistics in X-ray attenuation, resulting in significant noise reduction, which improves image quality and allows reduction in radiation dose.

2.3. Cardiac CT Analysis. Images with a reconstruction interval of 0.6 mm were transferred to a workstation (Advantage AW 4.4 workstation, GE Healthcare) with 3D capabilities. Since it can be challenging to identify the ostium in 3D reconstructions, the PV ostial dimensions were first evaluated using a 2-dimensional viewing mode assisted by oblique and curved multiplanar reconstructions (Figure 4). When PV ostia had been viewed and clearly identified, measurement of minimal and maximal PV diameter and area at the level of the ostium was obtained by using an automatic tool. Then, 3D volume-rendered images were used for depiction of pulmonary vein anatomical variants and branching patterns. Normal anatomy was defined as presence of two septal or right and two lateral or left separate PV ostia. A left common ostium (LCO) was defined when the superior and inferior left PV joined >5 mm before entering the left atrium. A right common ostium (RCO) was defined when the superior and inferior right PV joined >5 mm before entering the left atrium. A right middle pulmonary vein (RMPV) was defined as accessory, separate ostium for the middle-lobe vein. Other anatomical variants were not observed in our population. The volume was then measured and automatically calculated in 3D reconstruction from the previously determined point of inflection between the PV and atrial wall along the course of the PV to the midpoint of the PV 1 cm distally of the ostium. To standardize the analysis, images were displayed with a fixed window level at 100 HU and a window width at 800 HU. Similarly, the LA area was traced by using 3D volume-rendered images and semiautomated circumference measurement by excluding PVs at their ostia and the LA appendage at its base. LA volume was calculated by using an automatic tool. Volumes were reported independently and also indexed to body surface area.

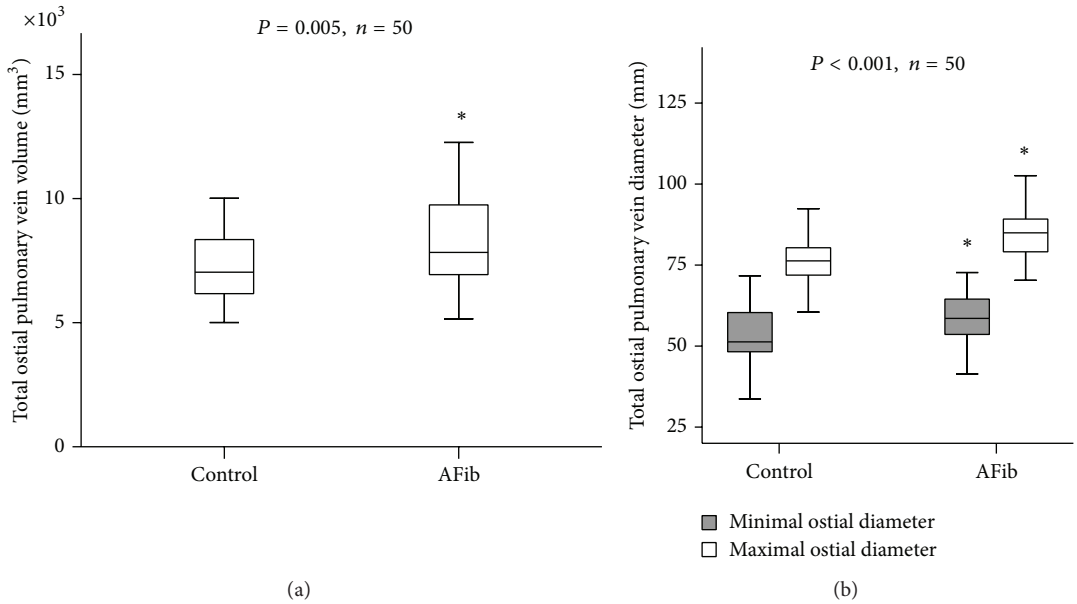

Figure 1: (a) Boxplots of total pulmonary vein (PV) volume (mm^3) in patients with atrial fibrillation (AFib) compared to controls with sinus rhythm (SR). (b) Total ostial pulmonary vein (PV) diameter (mm) in patients with atrial fibrillation (AFib) compared to healthy controls with sinus rhythm (SR). Data are presented as mean ± SD; $^*P < 0.05$.

2.4. Statistical Analysis. Quantitative variables were expressed as mean ± SD or mean ± SEM and categorical variables were expressed as frequencies or percentages. Normality was tested with the Kolmogorov-Smirnov test. Comparisons between the two groups were performed using Student's t-test for continuous variables with normal distributions and the Mann-Whitney U test for continuous variables with nonnormal distributions. All analyses were performed with statistics software (SPSS version 20.0 for Microsoft Windows). A two-tailed P value of <0.05 was deemed significant.

3. Results

3.1. Patient Characteristics. Cardiac HDCT scans from 50 consecutive patients (mean age 60.1 ± 11.4 years, mean BMI 27.3 ± 4.3 kg/m^2, 30 males) undergoing RFCA for drug refractory AFib and from 50 controls with normal sinus were analyzed. Controls were adequately matched for gender, age, and body mass index (P = NS). A total contrast amount of 102.3 ± 1.8 mL (AFib) and 89.3 ± 2.4 mL (controls) was administered (Table 1; P = NS). Eight (16%) patients in the AFib group were with AFib during image acquisition. The average effective radiation dose was 2.1 ± 0.3 mSv (AFib) and 2.0 ± 0.4 mSv (controls, P = NS), respectively (Table 1). Baseline characteristics are summarized in Table 1.

3.2. Total Pulmonary Vein Ostial Diameter and Volume Are Increased in Patients with AFib. Total PV ostial volume was significantly increased in patients with AFib as compared to controls: total PV ostial volume was 8356.7 ± 296.5 mm^3 in patients with AFib compared to 7309.02 ± 213.232 mm^3 in controls ($P < 0.005$, Figure 1(a)). Similarly, total minimal and maximal ostial PV diameters were significantly increased in AFib compared to controls (59.2 ± 1.4 mm and 85.2 ± 1.3 mm versus 53.3 ± 1.2 mm and 76.9 ± 1.1 mm, resp.; $P < 0.001$, Figure 1(b)).

3.3. The Largest Differences in Volumes between AFib and Controls Are Found in Superior PVs. In patients with AFib, the largest PV ostial volume and maximal diameter were measured in right superior PV (2465.9 ± 860.4 mm^3 and 22.6 ± 0.6 mm, resp., versus 2112.7 ± 544.5 mm^3 and 21.0 ± 0.6 mm in controls, Figures 2(a) and 2(c); $P < 0.05$). In left superior PV, volume and diameter were 1989.02 ± 621.5 mm^3 and 20.2 ± 0.5 mm in AFib versus 1720.5 ± 515.6 mm^3 and 18.9 ± 0.4 mm in controls ($P < 0.05$, Figures 2(a) and 2(c)). Accordingly, the difference in PV volume between AFib patients and controls was most pronounced in right superior PV (Δvolume = 14.4%; P = 0.015, Figure 2(a)) and left superior PV (Δvolume = 14.5%; $P < 0.01$). In right inferior PV, volume was 2117.9 ± 883.9 mm^3 in AFib versus 1924.4 ± 578.2 mm^3 in controls (Δvolume = 9.2%; P = NS, Figure 2(a)). In right middle PV, volume was 525.0 ± 354.8 mm^3 in AFib versus 433.6 ± 123.4 mm^3 in controls (Δvolume = 17.5%; n = 22; P = NS, Figure 2(a)). In left inferior PV, volume was 1626.4 ± 544.5 mm^3 in AFib versus 1522.0 ± 433.7 mm^3 in controls (Δvolume = 7%; P = NS, Figure 2(a)). Ostial volume and maximal diameter of right middle PVs were slightly increased in AFib as compared to controls: right middle PV volume was 525.0 ± 354.8 mm^3 in AFib versus 433.6±123.4 mm^3 in controls, while ostial right middle PV (maximal) diameter was 8.2 ± 0.8 mm in AFib versus 6.3 ± 0.5 mm^2 in controls. However, this difference was not significant. No difference was observed in minimal PV ostial diameters between groups (P = NS, Figure 2(b)).

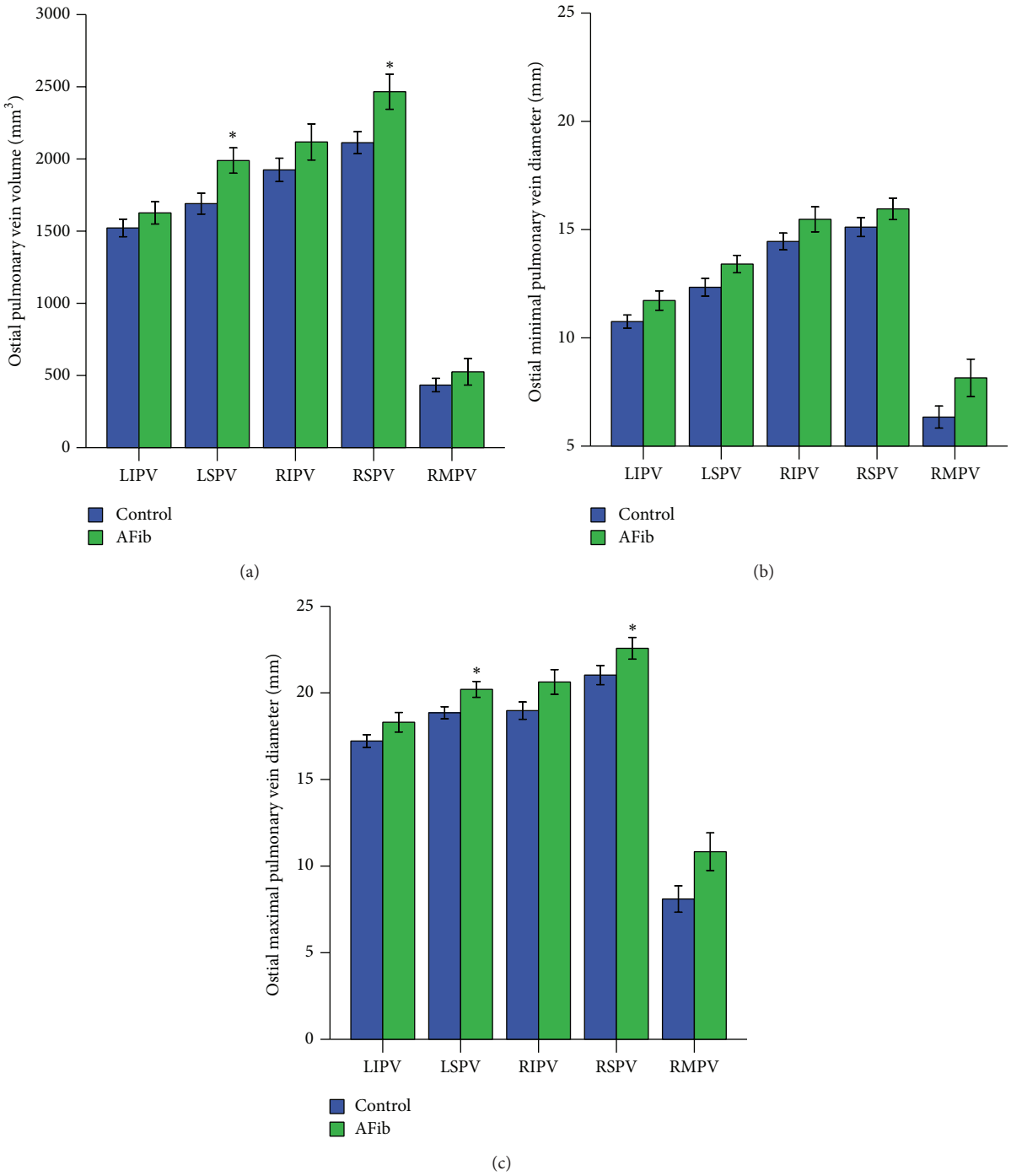

Figure 2: (a) Distribution of pulmonary vein (PV) volume (mm^3) in patients with atrial fibrillation (AFib) compared to controls with sinus rhythm (SR). (b) Distribution of minimal pulmonary vein (PV) diameter (mm) in patients with atrial fibrillation (AFib) compared to healthy controls with sinus rhythm (SR). (c) Distribution of maximal pulmonary vein (PV) diameter (mm) in patients with atrial fibrillation (AFib) compared to healthy controls with sinus rhythm (SR). LIPV, left inferior pulmonary vein; LSPV, left superior pulmonary vein; RIPV, right inferior pulmonary vein; RSPV, right superior pulmonary vein; RMPV, right middle pulmonary vein. Data are presented as mean ± SEM; $^*P < 0.05$.

Conventional PV anatomy, with 4 separate PVs, was present in 73% of patients (Figure 3). Anatomical variants were observed more often in patients with AFib (42%) compared to controls (14%, $P < 0.05$). The most common observed PV variation was a right-sided middle accessory PV in 16 patients (32%) with AFib and 7 controls (14%, $P < 0.05$); the second most frequent PV variation was a common left ostium (LCO) which was present in 4 patients with AFib

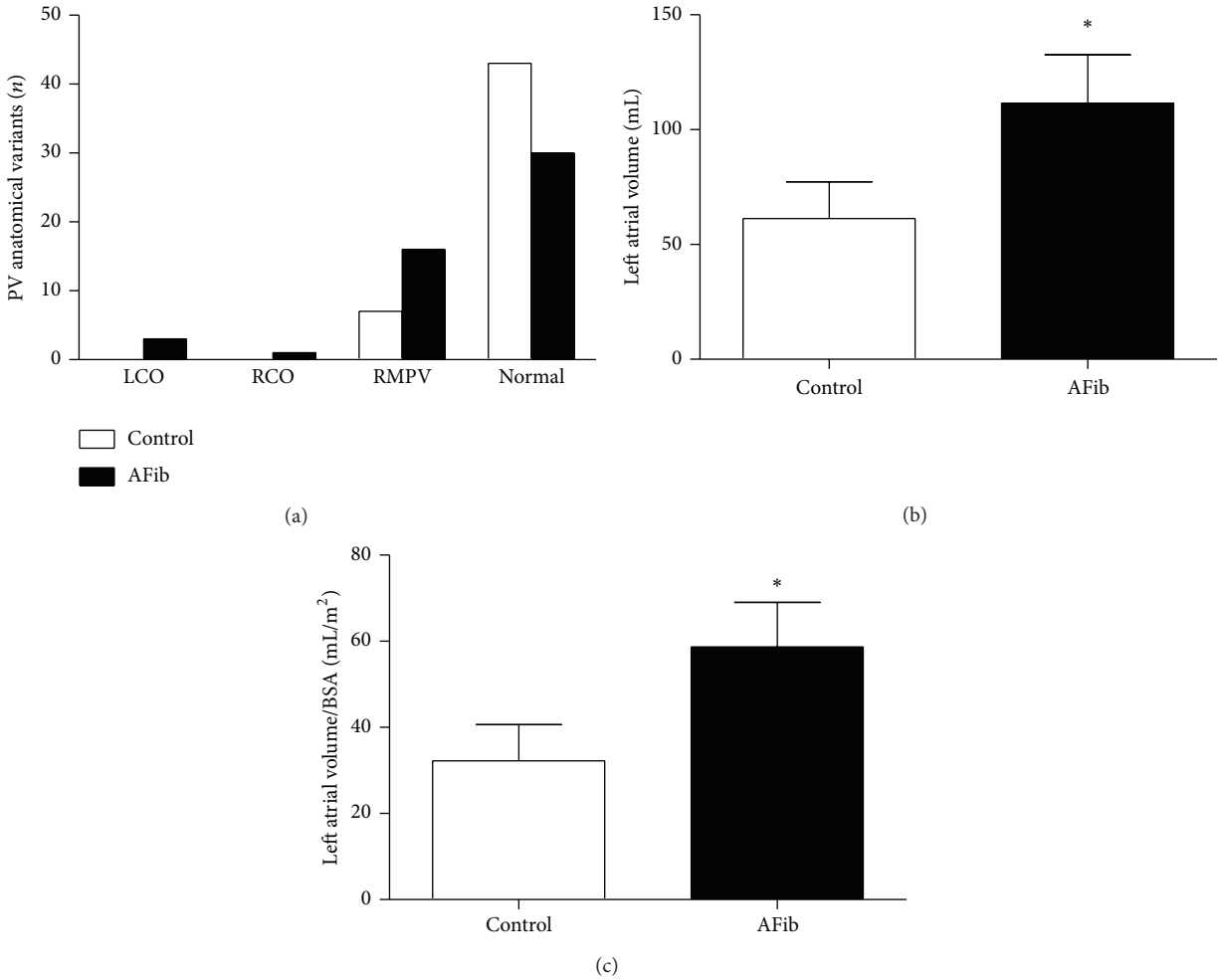

Figure 3: (a) Number of patients with a right middle pulmonary vein (RMPV), common left ostium (LCO), and common right ostium (RCO). Patients with AFib (atrial fibrillation) versus controls with SR (sinus rhythm). N = number of patients; total number of patients in each group = 50. (b) Volume of left atrium after exclusion of the pulmonary veins and left atrial appendage. (b) Left atrial volume in controls and patients with AFib. (c) Left atrial volume indexed to body surface area (BSA) in controls and patients with AFib; $^{*}P < 0.05$.

(8%). No patients had a left accessory PV, and only one patient with AFib (2%) had a common right ostium (RCO).

3.4. Left Atrial Volume Is Increased in Patients with AFib. Left atrial (LA) volume was assessed from prospectively ECG-gated (75% of RR-interval), contrast-enhanced cardiac volumes by using 3D volume-rendered images with semiautomated circumference measurement. The mean LA volume in the total study population was 85.7 ± 18 mL with a range of 37–172 mL. LA volume was significantly smaller in control patients (62.3 ± 161 mL) than that in patients with AFib (111.6 ± 21.3 mL, $P = 0.01$). Similarly, LA volume indexed to body surface area (BSA) was smaller in control patients (32.26 ± 8.4 mL/m^2) than in patients with AFib (58.7 ± 10.3 mL/m^2, $P = 0.03$).

4. Discussion

In this study, we demonstrate that total PV ostial volume and diameter are significantly increased in patients with drug refractory AFib compared to controls. This increase in PV ostial volume and diameter is most pronounced in superior PVs with the largest difference measured in right superior PVs. Further, we confirm that PV anatomy is different in patients with AFib with a higher frequency of right middle PVs and left common ostium.

Usually, four PVs drain into the left atrium. The superior PVs enter the left atrium from a superior, anterior, and lateral direction and the inferior ones from the posterior direction [15]. It is well known that there is considerable variation in PV anatomy and anatomical alterations of PVs, including common ostia, and additional veins have been detected in 18–45% of patients with AFib. However, the reported frequency of such anatomical variations has wide dispersion, which can in part be explained by variability in definitions of normality, and methodological differences. We observed an increased incidence of RMPV and LCO in patients with AFib. This distribution of anatomical variants in our study is very consistent with prior studies that have reported an additional RMPV or a LCO more frequently in patients with

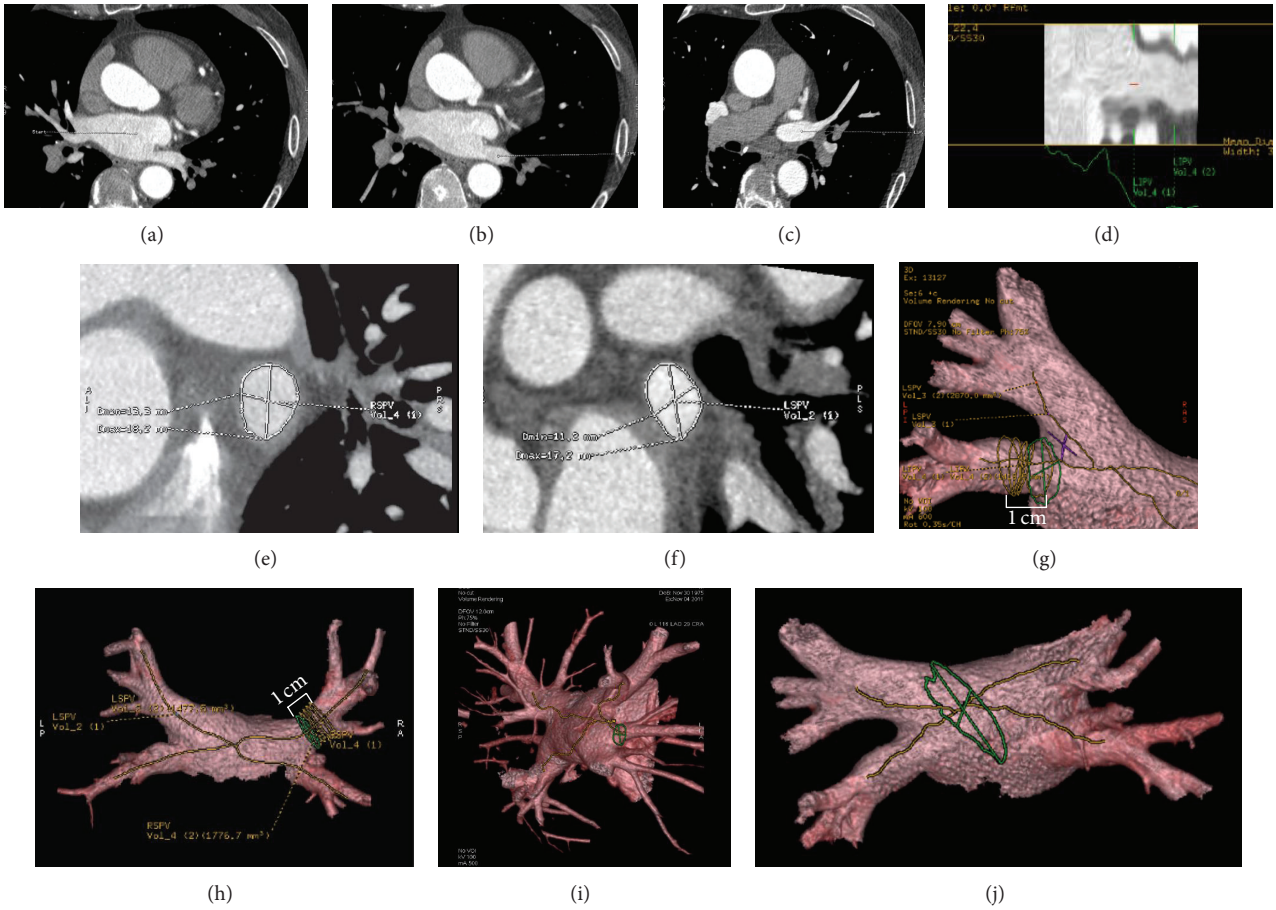

Figure 4: (a–c) Identification and labelling of left atrium and pulmonary vein ostia in 2-dimensional (axial) viewing. (d) Confirmation of point of inflection between pulmonary vein and left atrial wall in curved multiplanar reconstructions. (e-f) Following clear identification of ostia, measurement of minimal and maximal ostial pulmonary vein diameter in oblique view. (g-h) Three-dimensional volume-rendered reconstruction: the previously identified ostium was used as a starting point for volume measurements along the course of the PV to the midpoint of the PV 1 cm distal of the ostium. (i) Depiction of pulmonary vein anatomy and branching pattern by using 3D volume-rendered images. (j) Tracing and labelling of left atrium for left atrium volume measurements by using 3D rendered images. LIPV, left inferior pulmonary vein; LSPV, left superior pulmonary vein; RIPV, right inferior pulmonary vein; RSPV, right superior pulmonary vein; RMPV, right middle pulmonary vein.

AFib compared to controls [16–18]. However, controversies exist regarding whether right-sided anatomical variants are associated with a higher risk of AFib recurrence following radiofrequency catheter ablation. While some studies did not find a relation between PV anatomy and AFib recurrence, others reported an increased incidence of AFib recurrence in normal PV anatomy compared to variant anatomy, or a higher AFib recurrence rate in anatomical variants [6, 17, 19–24]. Thus, larger clinical studies will be required to establish whether anatomical variants are a risk factor for AFib recurrence.

There is clear evidence that enlarged LA dimensions are more frequently observed in patients with AFib and that larger LA dimensions are associated with a higher risk of AFib recurrence following ablation [6, 25]. However, while LA dimensions have been well described in patients with AFib, less information is available if such morphological changes also occur in the PVs. To the best of our knowledge, to date, no study has measured ostial PV volumes in patients with AFib and only few studies have directly compared PV characteristics in patients with and without AFib. Consistent with our results, these authors report larger PV ostial diameters in patients with AFib compared to controls [10, 16, 20, 26]. Further, superior PVs seem to have a larger ostial diameter than inferior PVs, a phenomenon that was also observed in the present study [27]. Remarkably, enlargement of superior PVs has been described to be an independent risk factor for AFib recurrence following radiofrequency catheter ablation [28].

Previous investigators have measured PV diameters by using CT only in one specified plane, usually at the ostium in anterior-posterior and inferior-superior directions [10]. It is often difficult to define the border between left atrium and pulmonary veins by 2D analysis; thus, we used 3D reconstructed models and performed volume measurements in all PVs starting from the point of inflection between the PV and atrial wall along the course of the PV to the midpoint of the

PV 1 cm distally of the ostium. In addition, we used oblique and curved multiplanar reconstructions to confirm the borders of both left atrium and PVs. Since PV ostia are considered to have an elliptical shape with the long axis in vertical orientation [29], 3D measurement and calculation of PV areas and volumes may cope more precisely with the elliptical shape of the ostia and may be a more suitable diagnostic tool to detect anatomical differences in AFib compared with diameter measurements and may improve diagnostic accuracy.

Limitations of this study are its retrospective design limited to a single center experience. Further, the study population size is limited, which is in part counterbalanced by optimal matching of the control group. In addition, the prognostic value of our findings remains to be elucidated, and further studies are needed to assess whether the observed alterations in PV anatomy contribute to the complex pathophysiology of AFib or whether larger PV ostia are a cause, a consequence, or just an epiphenomenon of atrial structural remodelling in AFib.

In conclusion, we found that PV ostial diameter and PV volume were significantly larger in patients with drug refractory AFib than in controls and that this difference was most pronounced in right superior PVs. This finding suggests that an assessment of PV ostial volume may add to the risk stratification for AFib recurrence following RFCA and may be incorporated into the preprocedural evaluation of patients being considered for AFib ablation.

Conflict of Interests

The authors declare that there is no conflict of interests regarding the publication of this paper.

Authors' Contribution

Catherine Gebhard and Nazmi Krasniqi contributed equally to this paper. Catherine Gebhard, Nazmi Krasniqi, Firat Duru, and Philipp A. Kaufmann were substantially involved in the conceptual design of the study, statistical analysis of the data, and drafting of the paper. Barbara E. Stähli, Thomas F. Lüscher, and Firat Duru were involved in critical review of data integrity and gave their intellectual input concerning paper drafting. Catherine Gebhard, Jelena R. Ghadri, and Bernd Klaeser were substantially involved in acquisition of imaging data in daily clinical routine. Further, Jelena R. Ghadri and Philipp A. Kaufmann gave substantial technical input regarding cardiac computed tomography imaging. Laurent Haegeli, Nazmi Krasniqi, Thomas F. Lüscher, Philipp A. Kaufmann, and Tobias A. Fuchs critically reviewed the paper and gave important intellectual input. All authors have critically reviewed and approved the final version of the paper.

Acknowledgment

This study was supported by grants from the Swiss National Science Foundation (SNSF) to Philipp A. Kaufmann.

References

[1] A. D. Krahn, J. Manfreda, R. B. Tate, F. A. L. Mathewson, and T. E. Cuddy, "The natural history of atrial fibrillation: incidence, risk factors, and prognosis in the Manitoba Follow-Up Study," *American Journal of Medicine*, vol. 98, no. 5, pp. 476–484, 1995.

[2] M. Haïssaguerre, P. Jaïs, D. C. Shah et al., "Spontaneous initiation of atrial fibrillation by ectopic beats originating in the pulmonary veins," *New England Journal of Medicine*, vol. 339, no. 10, pp. 659–666, 1998.

[3] H. Oral, B. P. Knight, H. Tada et al., "Pulmonary vein isolation for paroxysmal and persistent atrial fibrillation," *Circulation*, vol. 105, no. 9, pp. 1077–1081, 2002.

[4] D. C. Shah, M. Haïssaguerre, P. Jaïs et al., "Curative catheter ablation of paroxysmal atrial fibrillation in 200 patients: strategy for presentations ranging from sustained atrial fibrillation to no arrhythmias," *Pacing and Clinical Electrophysiology*, vol. 24, no. 10, pp. 1541–1558, 2001.

[5] J. M. Lacomis, O. Goitein, C. Deible, and D. Schwartzman, "CT of the pulmonary veins," *Journal of Thoracic Imaging*, vol. 22, no. 1, pp. 63–76, 2007.

[6] D. W. den Uijl, L. F. Tops, V. Delgado et al., "Effect of pulmonary vein anatomy and left atrial dimensions on outcome of circumferential radiofrequency catheter ablation for atrial fibrillation," *American Journal of Cardiology*, vol. 107, no. 2, pp. 243–249, 2011.

[7] M. A. Wood, M. Wittkamp, D. Henry et al., "A comparison of pulmonary vein ostial anatomy by computerized tomography, echocardiography, and venography in patients with atrial fibrillation having radiofrequency catheter ablation," *American Journal of Cardiology*, vol. 93, no. 1, pp. 49–53, 2004.

[8] P. Blanke, T. Baumann, M. Langer, and G. Pache, "Imaging of pulmonary vein anatomy using low-dose prospective ECG-triggered dual-source computed tomography," *European Radiology*, vol. 20, no. 8, pp. 1851–1855, 2010.

[9] H.-M. Tsao, M.-H. Wu, B.-H. Huang et al., "Morphologic remodeling of pulmonary veins and left atrium after catheter ablation of atrial fibrillation: insight from long-term follow-up of three-dimensional magnetic resonance imaging," *Journal of Cardiovascular Electrophysiology*, vol. 16, no. 1, pp. 7–12, 2005.

[10] I. Woźniak-Skowerska, M. Skowerski, A. Wnuk-Wojnar et al., "Comparison of pulmonary veins anatomy in patients with and without atrial fibrillation: analysis by multislice tomography," *International Journal of Cardiology*, vol. 146, no. 2, pp. 181–185, 2011.

[11] J. R. Ghadri, S. M. Küest, R. Goetti et al., "Image quality and radiation dose comparison of prospectively triggered low-dose CCTA: 128-slice dual-source high-pitch spiral versus 64-slice single-source sequential acquisition," *International Journal of Cardiovascular Imaging*, vol. 28, no. 5, pp. 1217–1225, 2012.

[12] R. R. Buechel, L. Husmann, B. A. Herzog et al., "Low-dose computed tomography coronary angiography with prospective electrocardiogram triggering: feasibility in a large population," *Journal of the American College of Cardiology*, vol. 57, no. 3, pp. 332–336, 2011.

[13] L. Husmann, B. A. Herzog, O. Gaemperli et al., "Diagnostic accuracy of computed tomography coronary angiography and evaluation of stress-only single-photon emission computed tomography/computed tomography hybrid imaging: comparison of prospective electrocardiogram- triggering versus retrospective gating," *European Heart Journal*, vol. 30, no. 5, pp. 600–607, 2009.

[14] B. A. Herzog, C. A. Wyss, L. Husmann et al., "First head-to-head comparison of effective radiation dose from low-dose 64-slice CT with prospective ECG-triggering versus invasive coronary angiography," *Heart*, vol. 95, no. 20, pp. 1656–1661, 2009.

[15] B. Schmidt, S. Ernst, F. Ouyang et al., "External and endoluminal analysis of left atrial anatomy and the pulmonary veins in three-dimensional reconstructions of magnetic resonance angiography: the full insight from inside," *Journal of Cardiovascular Electrophysiology*, vol. 17, no. 9, pp. 957–964, 2006.

[16] C. Scharf, M. Sneider, I. Case et al., "Anatomy of the pulmonary veins in patients with atrial fibrillation and effects of segmental ostial ablation analyzed by computed tomography," *Journal of Cardiovascular Electrophysiology*, vol. 14, no. 2, pp. 150–155, 2003.

[17] E. M. Marom, J. E. Herndon, Y. H. Kim, and H. P. McAdams, "Variations in pulmonary venous drainage to the left atrium: implications for radiofrequency ablation," *Radiology*, vol. 230, no. 3, pp. 824–829, 2004.

[18] A. Bittner, G. Mnnig, A. J. Vagt et al., "Pulmonary vein variants predispose to atrial fibrillation: a case-control study using multislice contrast-enhanced computed tomography," *Europace*, vol. 13, no. 10, pp. 1394–1400, 2011.

[19] W.-S. Lin, V. S. Prakash, C.-T. Tai et al., "Pulmonary vein morphology in patients with paroxysmal atrial fibrillation initiated by ectopic beats originating from the pulmonary veins: implications for catheter ablation," *Circulation*, vol. 101, no. 11, pp. 1274–1281, 2000.

[20] R. Kato, L. Lickfett, G. Meininger et al., "Pulmonary vein anatomy in patients undergoing catheter ablation of atrial fibrillation: lessons learned by use of magnetic resonance imaging," *Circulation*, vol. 107, no. 15, pp. 2004–2010, 2003.

[21] C. Sohns, J. M. Sohns, D. Vollmann et al., "Left atrial volumetry from routine diagnostic work up prior to pulmonary vein ablation is a good predictor of freedom from atrial fibrillation," *European Heart Journal Cardiovascular Imaging*, vol. 14, no. 7, pp. 684–691, 2013.

[22] A. J. McLellan, L. H. Ling, D. Ruggiero et al., "Pulmonary vein isolation: the impact of pulmonary venous anatomy on long-term outcome of catheter ablation for paroxysmal atrial fibrillation," *Heart Rhythm*, vol. 11, pp. 549–556, 2014.

[23] S. Schroeder, A. F. Kopp, A. Kuettner et al., "Influence of heart rate on vessel visibility in noninvasive coronary angiography using new multislice computed tomography. Experience in 94 patients," *Clinical Imaging*, vol. 26, no. 2, pp. 106–111, 2002.

[24] I. Hof, K. Chilukuri, A. Arbab-Zadeh et al., "Does left atrial volume and pulmonary venous anatomy predict the outcome of catheter ablation of atrial fibrillation?" *Journal of Cardiovascular Electrophysiology*, vol. 20, no. 9, pp. 1005–1010, 2009.

[25] C. von Bary, C. Dornia, C. Eissnert et al., "Predictive value of left atrial volume measured by non-invasive cardiac imaging in the treatment of paroxysmal atrial fibrillation," *Journal of Interventional Cardiac Electrophysiology*, vol. 34, no. 2, pp. 181–188, 2012.

[26] M. R. M. Jongbloed, M. S. Dirksen, J. J. Bax et al., "Atrial fibrillation: multi-detector row CT of pulmonary vein anatomy prior to radio-frequency catheter ablation - Initial experience," *Radiology*, vol. 234, no. 3, pp. 702–709, 2005.

[27] M. R. M. Jongbloed, J. J. Bax, H. J. Lamb et al., "Multislice computed tomography versus intracardiac echocardiography to evaluate the pulmonary veins before radiofrequency catheter ablation of atrial fibrillation: a head-to-head comparison," *Journal of the American College of Cardiology*, vol. 45, no. 3, pp. 343–350, 2005.

[28] W. Wei, J. B. Ge, Y. Zou, L. Lin, Y. Cai, and X. B. Liu, "Anatomical characteristics of pulmonary veins for the prediction of post-operative recurrence after radiofrequency catheter ablation of atrial fibrillation," *PLoS ONE*, vol. 9, Article ID e93817, 2014.

[29] F. H. M. Wittkampf, E.-J. Vonken, R. Derksen et al., "Pulmonary vein ostium geometry: analysis by magnetic resonance angiography," *Circulation*, vol. 107, no. 1, pp. 21–23, 2003.



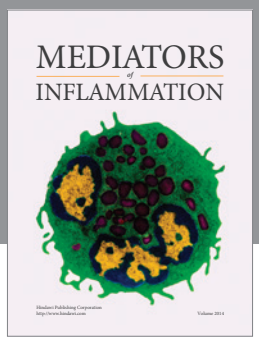



Hindawi
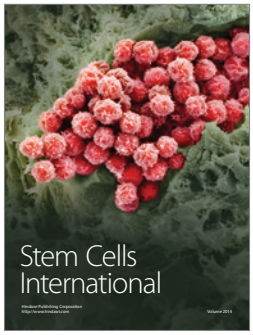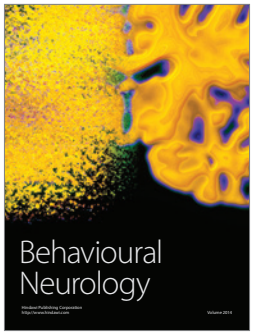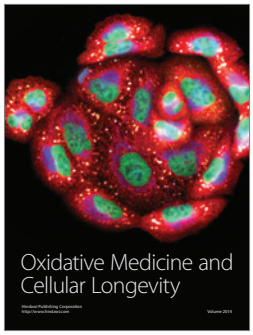
Submit your manuscripts at
http://www.hindawi.com