

CARDIOVASCULAR FLASHLIGHT

doi:10.1093/eurheartj/ehp500

Online publish-ahead-of-print 19 November 2009

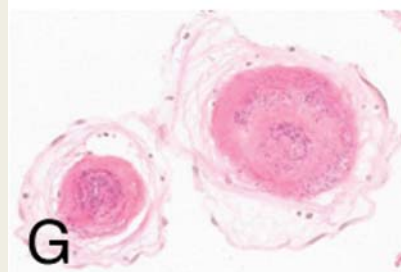
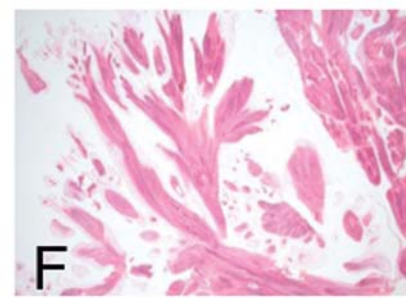
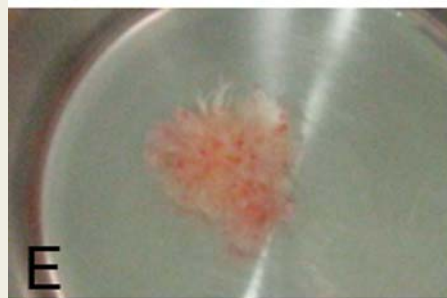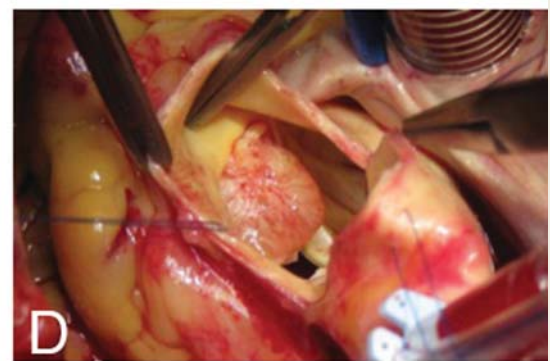
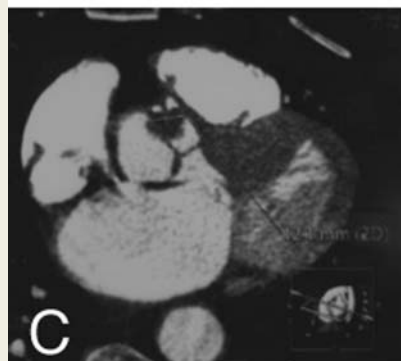
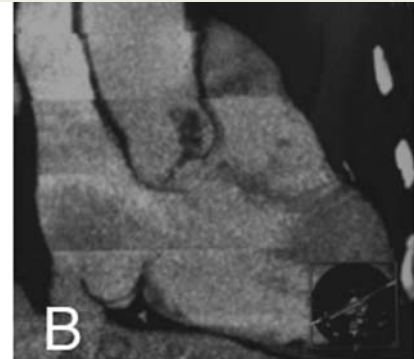
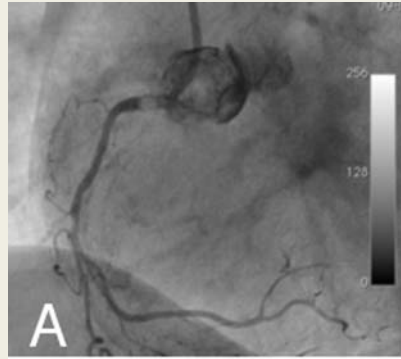
Cardiac fibroelastoma causing angina

Isabelle Frésard¹, Mario Stalder², Mathias Gugger³, and Jean-Jacques Goy^{1*}

¹Cardiology Division, Hôpital Cantonal, Fribourg 1700, Switzerland; ²Service of Cardiothoracic Surgery, Inselspital, Bern, Switzerland; and ³Anatomopathology Department, Inselspital, Bern, Switzerland

*Corresponding author. Tel: +41 792 136 465, Fax: +41 244 260 731, Email: jjgoy@goyman.com

An 80-year-old woman was referred to our hospital for coronary angiogram because of unstable angina pectoris in spite of optimal medical treatment. Stent placement (drug eluting stent, DES) on the LAD was performed 3 years before. Physical examination and ECG were normal without cardiac murmur. Cardiac catheterization showed a patent DES on the LAD and an ostial occlusion of the right coronary artery (RCA). Non-selective injection typically showed an intra-aortic mass attached to the right Valsalva sinus (Panel A). Transthoracic echocardiography and cardiac CT scan (Panels B and C) confirm the presence of a tumour. The patient was referred for surgery. A 1 cm spherical mass attached to the aortic valve (not a leaflet) by a short pedicle with small hair-like projections was found (Panels D and E). This mass was removed and saphenous coronary artery bypass grafting was performed on the RCA. Outcome was uneventful. The histopathology examination found a papillary fibroelastoma (Panels F and G). It is a rare benign cardiac tumour accounting for 10% of all



primary cardiac neoplasms. More than 80% are symptomatic and located on the left side of the heart. Stroke, sudden death, ischaemia, and rhythm disturbances are common symptoms. Surgical excision is recommended, even in asymptomatic patients, because of the potential of thromboembolism and a low operative risk of ~2%. Our case is remarkable by the location of the mass not on a leaflet but at the origin of the RCA in the Valsalva sinus and its presentation as an acute coronary syndrome.