Int Urogynecol J (2011) 22:443–445
DOI 10.1007/s00192-010-1355-2

CASE REPORT

# Injury of the corona mortis during vaginal tape insertion (TVT-Secur™ using the U-Approach)

**Ursula Gobrecht · Annette Kuhn · Bernhard Fellman**

Received: 28 October 2010 / Accepted: 16 December 2010 / Published online: 18 January 2011


**Abstract**
*Introduction and hypothesis* We report a serious bleeding complication due to injury of the corona mortis following insertion of a transvaginal tape, TVT-Secur™ (Ethicon Women's Health, Sommerville, NJ, USA).
*Methods* The TVT-Secur™ was inserted using the U-Approach: the tape was pushed along the periost behind the arc of the pubic bone at an angle of 45°.
*Results* Surgery was unproblematic. Four hours after surgery, the patient showed shock signs; a CT scan revealed a 13.5×9.5-cm-sized retrosymphysic haematoma. Instant laparotomy with removal of the large haematoma, ligation of the bleeding corona mortis and administration of erythrocyte concentrates were necessary.
*Conclusion* The corona mortis is an anastomosis between the arteria obturatoria and the external iliac vessels or its branches that passes over the superior pubic ramus. Its prevalence and anatomical relation to the pubic bone are important to bear in mind when applying new surgical techniques.

**Keywords** Corona mortis · Intraabdominal bleeding · Vaginal tape · Vaginal tape insertion

## Introduction

For the surgical treatment of stress urinary incontinence, different types of vaginal tapes have been established. New short-tape methods pledge minimal invasive access and more security. The aim is to avoid complications such as bladder perforation, haematoma and groin abscesses while achieving the same effectiveness as established slings. One of these short tapes is the TVT-Secur™. Its stability in the tissue is meant to be ensured by fleece pads on the tips.

For its insertion, a sharp, blade-shaped instrument is used. The producer suggests two possibilities for inserting the TVT-Secur™: the U-Approach and the Hammock-Approach. In the U-Approach, the tape is pushed along the periost behind the arc of the pubic bone at an angle of 45°. In the Hammock-Approach, the tape is pushed towards the obturator foramen, where the tips are anchored inside the obturator muscle. The name U-Approach misleadingly suggests a course similar to the classic retrosymphysic TVT. Whereas the classic retropubic TVT runs almost vertically upwards, the TVT-Secur™ using the U-approach in the recommended 45° angle is more like a V-Approach (Fig. 1).

Recently, Larsson et al. reported a case of bleeding from the corona mortis during tension-free vaginal tape (TVT-Secur™) procedure using the Hammock-Approach [1]. We would like to report a similar complication during TVT-Secur™ insertion using the U-Approach. The difference has to be seen in the original attempt for the tape insertion, but Larsson et al. very likely ended in the same area as we did.

## Case

We performed an unproblematic insertion of a TVT-Secur™ under general anaesthesia in a 68-year-old patient suffering from urodynamic stress incontinence. The U-Approach was used, placing the ends of the inserters in a 45° angle in contact with the periost of the pubic ramus. The procedure was performed according to the manufacturer's guidelines. Four hours after the intervention, the

U. Gobrecht (✉) · B. Fellman
Bürgerspital Solothurn,
4500, Solothurn, Switzerland
e-mail: ursula_gobrecht@hotmail.com

A. Kuhn
Universitätsklinik für Frauenheilkunde, Inselspital,
CH-3010, Bern, Switzerland

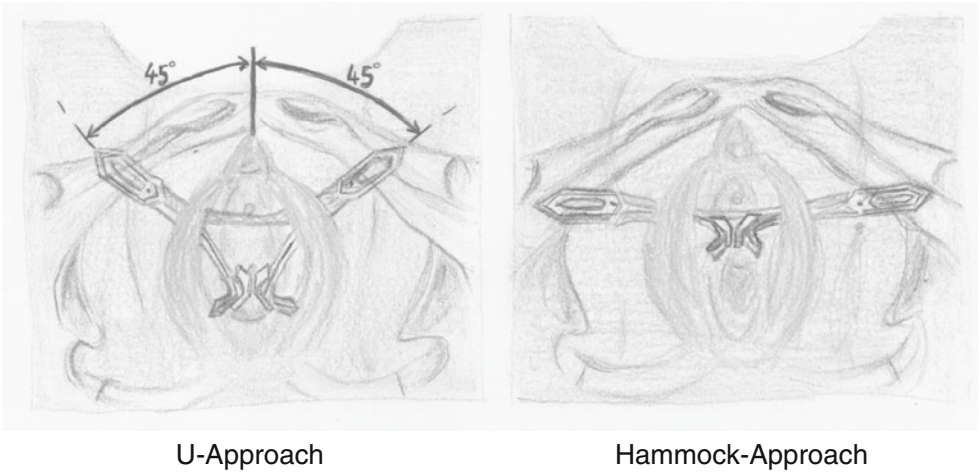


**Fig. 1** U-Approach and Hammock-Approach

patient reported sudden lower abdominal pain followed by hypotension and tachycardia. A computed tomography showed a 13.5×9.5-cm-sized retrosymphysic haematoma with an active source of bleeding on the right side, at a 26-mm distance from the symphysis (Fig. 2). Immediate laparotomy confirmed a bleeding vessel next to the arc of the pubic bone and its corresponding stub inside the fossa obturatoria. The bleeding was stopped by ligation of the bleeding vessels. Haemoglobin levels dropped from 129 g/l to 63 g/l, and three erythrocyte concentrates had to be administered. Postoperatively, the patient remained incontinent. After 4 months, a TVT™ retropubic system was safely placed in the area where the revision had been performed, whereupon the patient regained her continence and is now satisfied.

## Discussion

Various studies evaluated by Rusu et al. showed an incidence of the corona mortis of 28.5–84%; the distance between the corona mortis and the pubic symphysis was ranging from 21.4 to 96 mm [2].

The length of the branch of the TVT-Secur™ is 40 mm. If inserted in the proposed 45° angle (U-Approach), a rectangular, equal-sided triangle is formed. Assuming that there is no considerable kink of the branches, we hypothesise that the distance between the symphysis and tape amounts to approximately 25–30 mm. This implies that there is an overlap of the range where the tip of the TVT-Secur™ is placed and the range where the corona mortis is found (Fig. 2).

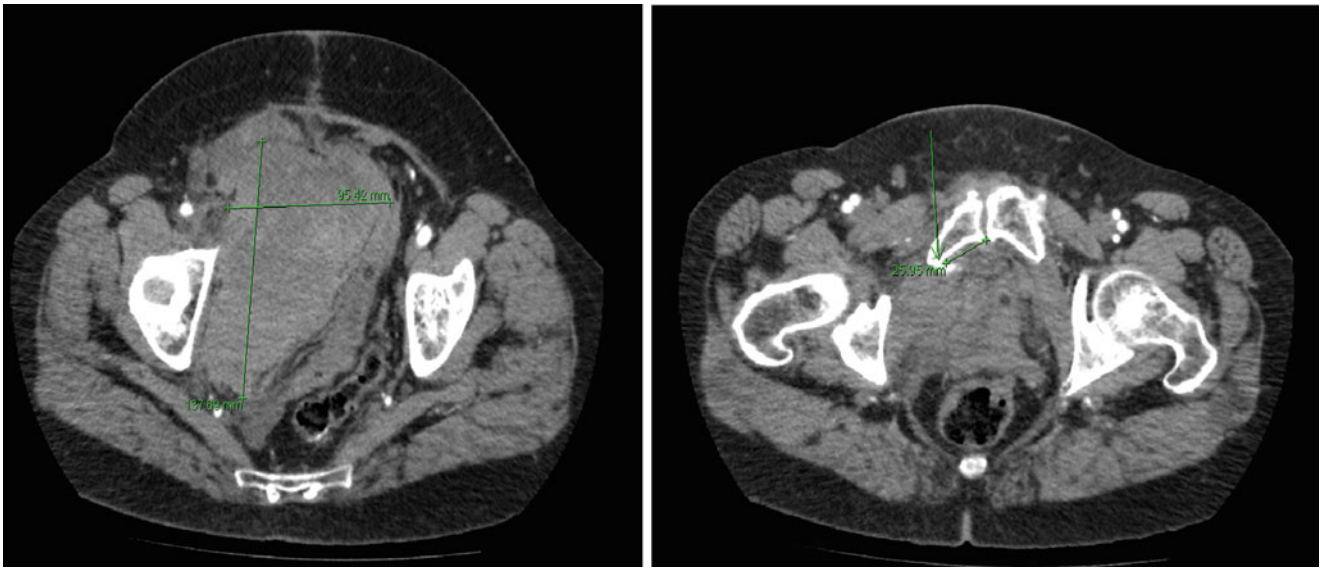


CT-Scan: Retrosymphysic haematoma of 95x137mm (left), active bleeding 26 mm distance from symphysis = corona mortis (right)

**Fig. 2** CT scan of retrosymphysic haematoma of 95×137 mm (left), active bleeding at 26-mm distance from the symphysis = corona mortis (right)

Hubka et al. performed several cadaver studies in order to describe possible complications that might occur during new methods for treatment of stress urinary incontinence [3]. One of the methods evaluated was the TVT-Secur™ in the U position. In 19 formalin-embalmed bodies and a group of six fresh, frozen bodies with TVT-Secur™ inserted in the U position, they found two injuries of the corona mortis. They stated that it is a matter of chance if those vessels will start bleeding after touching them with a scalpel-shaped inserter.

Hubka's comments on the case report of Larsson using the hammock position are that the injury of the corona mortis happened in the attempt to place the TVT-Secur™ more upwardly, similar to the tape applied in the U position. We strongly agree. In our opinion, the 45°-angle insertion is the problem. Injuring the corona mortis could be avoided by inserting a tape in either a 0° angle (classic retropubic TVT) or a 90° angle (TVT-O, obturator). There is a paucity of data evaluating complications of these new short slings; the current case documents the severity of postoperative complications despite the plea for an increased security of the so-called mini slings. Existing data show inferior results for short tapes than for classical retropubic tapes [4]. In our case, the short tape turned out to be neither effective nor safe. Our intention is to stress caution when adopting new technologies since some devices eventually prove to be ineffective or even harmful. New techniques should only be tested in direct comparison with the gold standard in the context of adequate studies and not be used as 'routine procedures' without quality control. Additionally, when applying new surgical approaches in stress urinary incontinence, the corona mortis and its anatomical relation to the pubic bone are important to bear in mind.

**Conflicts of interest** None.

## References

1. Larsson PG, Teleman P, Persson J (2010) A serious bleeding complication with injury of the corona mortis with the TVT-Secur procedure. Int Urogynecol J Pelvic Floor Dysfunct 21:1175–1177
2. Rusu MC, Cergan R, Motoc AG, Folescu R, Pop E (2010) Anatomical considerations on the corona mortis. Surg Radiol Anat 32:17–24
3. Hubka P, Svabik K, Martan A, Masata J (2010) A serious bleeding complication with injury of the corona mortis with the TVT-Secur procedure: two cases of contact of TVT-S with the corona mortis during cadaver study. Int Urogynecol J Pelvic Floor Dysfunct 21:1179–1180
4. Martan A, Svabik K, Masata J, Koleska T, El-Haddad R, Pavlikova M (2009) Correlation between changes in ultrasound measurements and clinical curative effect of tension-free vaginal tape-SECUR* procedure. Int Urogynecol J Pelvic Floor Dysfunct (in press)