International Journal of Paleopathology 11 (2015) 56–65

Contents lists available at ScienceDirect

International Journal of Paleopathology

journal homepage: www.elsevier.com/locate/ijpp

Case study

Survival after trepanation—Early cranial surgery from Late Iron Age Switzerland

Negahnaz Moghaddam[a], Simone Mailler-Burch[a], Levent Kara[b,c], Fabian Kanz[d], Christian Jackowski[b], Sandra Lösch[a,*]

[a] Department of Physical Anthropology, Institute of Forensic Medicine, University of Bern, Switzerland
[b] Department of Forensic Medicine and Imaging, Institute of Forensic Medicine, University of Bern, Switzerland
[c] Department of Diagnostic, Interventional and Pediatric Radiology, Inselspital, University of Bern, Switzerland
[d] Department of Forensic Medicine, Unit of Forensic Anthropology, Medical University of Vienna, Austria

ARTICLE INFO

Article history:
Received 10 March 2015
Received in revised form 10 July 2015
Accepted 24 August 2015

Keywords:
Trepanation
Survival rate
Late Iron Age
Münsingen-Rain
Switzerland

ABSTRACT

Trepanation is defined as the intentional perforation of the cranial vault with removal of a piece of skull bone. In Europe, trepanation is known to have been practiced at least since the Neolithic, and it can still be found today in East African native tribes. Two skulls with lesions from the Late Iron Age site Münsingen-Rain (420–240 BC) were investigated. The aim of this study was to analyse the lesions and to determine whether they were caused by surgical interventions. Both individuals were analysed by current morphologic-anthropological methods and radiological examinations were performed with a multislice CT-scanner. Additionally, this work surveys trepanations reported in Switzerland and calculates survival rates. In Switzerland, 34 individuals with trepanations have been published. As a tendency, the survival rate appears to be relatively high from the Neolithic to Late Antiquity but then decreases until Pre-Modern times. The 78% survival rate in Late Iron Age Switzerland indicates that the surgery was often performed successfully. Skull injuries sustained in conflicts could have been a reason for trepanation during the Iron Age.

1. Introduction

Ancient skulls with premortem evidence of surgical interventions are of interest to anthropologists, archaeologists, physicians, pathologists and radiologists. When definitively not caused by taphonomic changes or trauma, such "trepanations" are important in the history of neurosurgery (Gomez, 1973; Stevens and Wakely, 1993). Trepanation is defined as the intentional perforation of the cranial vault with removal of a part of skull bone. Underlying soft tissues such as blood-vessels, meninges and the brain are usually not damaged during trepanation (Aufderheide and Rodríguez-Martín, 1998; Lisowski, 1967; Ortner, 2003; Pahl, 1993). There are four main trepanation techniques: scraping, grooving, drilling with cutting, and sawing (Campillo, 1984; Fabbri et al., 2012; Gross, 2003; Kaufman et al., 1997; Lisowski, 1967; Pahl, 1993; Rose, 2003).

Trepanations have been carried out to treat head injuries such as wounds and fractures (Verano, 2003; Zimmerman et al., 1981). Another purpose for the surgery might have been healing symptoms of diseases such as epilepsy and headaches. Campillo (1984) suggested that most trepanations may have been performed for ritual reasons. Ullrich (1997) specified a trepanation also as a treatment of the intact skull, excluding a surgery due to pathological alterations or trauma. Some conditions such as cranial dysraphism and infections, e.g. syphilis and tuberculosis, might simulate a trepanation. Anatomical variations such as enlarged parietal foramina, and ordinary trauma should also be considered as differential diagnosis (Aufderheide and Rodríguez-Martín, 1998; Steinbock, 1976).

Another phenomenon that is assigned to the topic "trepanations" are cranial amulets from different prehistoric periods found mostly in Europe (Oeftinger and Wahl, 2000). From Switzerland, a few amulets are known from Neolithic times (Cordier, 2005). However, for obtaining "magic-ritual" amulets trepanations were most commonly performed postmortem (Murphy, 2003; Wahl, 2012).

Trepanations in their original sense are still practiced today by the Kisii in Kenya with a very high survival rate of 95% (Margetts, 1967; Qureshi and Oluoch-Olunya, 2010). Prehistoric skulls with healed trepanations, some even with multiple healed lesions, also indicate a high survival rate (Andrushko and Verano, 2008; Ramseier et al., 2005), thus hinting at a skilful early form of cranial

* Corresponding author at: Department Physical Anthropology, Institute of Forensic Medicine, University of Bern, Sulgenauweg 40, 3007 Bern, Switzerland.
E-mail address: Sandra.Loesch@irm.unibe.ch (S. Lösch).

http://dx.doi.org/10.1016/j.ijpp.2015.08.002
1879-9817/

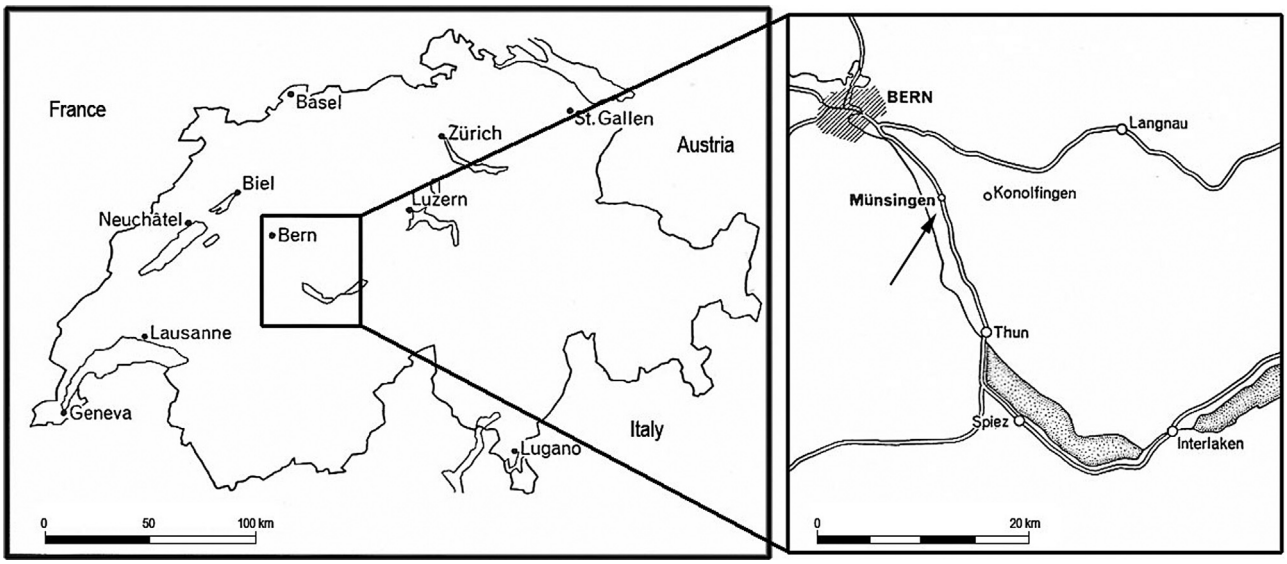

Fig. 1. Location of the Late Iron Age burial site of Münsingen-Rain, Switzerland (modified after Hodson (1968)).

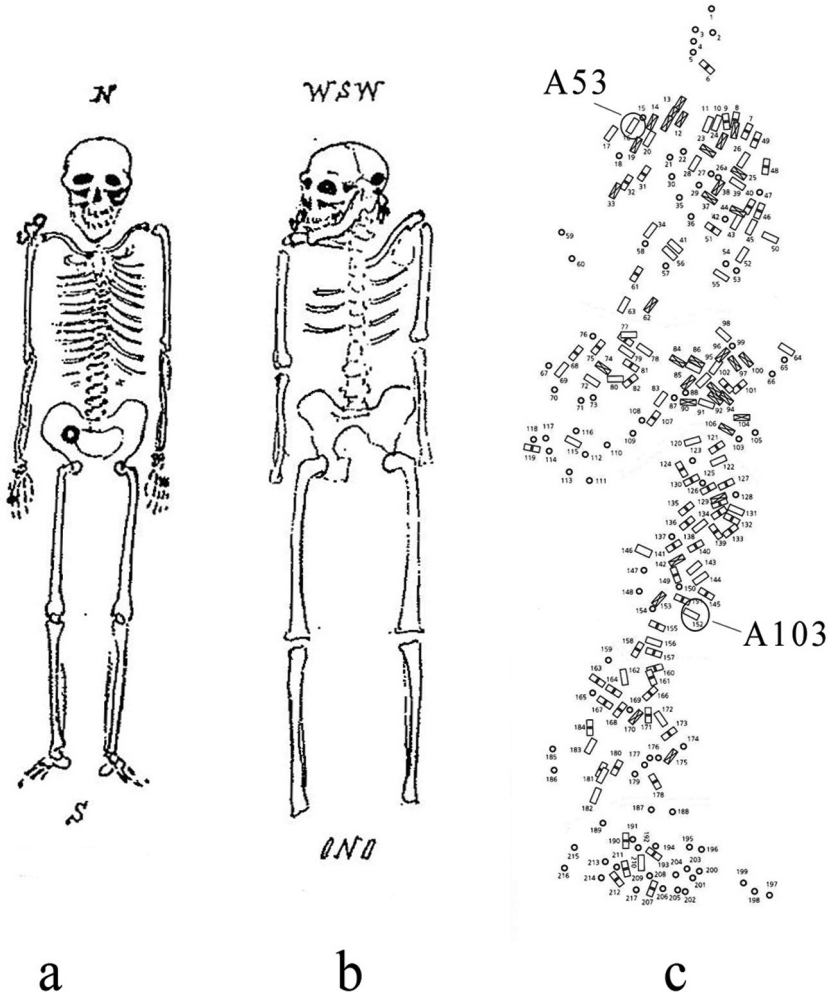

Fig. 2. Original drawing from the excavation diary in 1906. Individual A53 (a) and Individual A103 (b). Excavation plan modified after Jud (1998). Individual A53 was found in the Latène A part (450–400BC) and individual A103 was found close to the centre which dates to the Latène B (400–260BC) period (c).

surgery in times without antibiotics. Temporal and geographical comparison of survival rates might provide information about the reasons for trepanning, such as medical or ritual purposes.

About two thousand trephined skulls dating from 500 BC to 1500 AD have been reported from Peru (Andrushko and Verano, 2008; Jørgensen, 1988; Kurin, 2013; Marino and Gonzales-Portillo, 2000;

Rose, 2003; Verano, 2003; Verano and Andrushko, 2010). Trepanations are also recorded from other South American countries, such as Bolivia (Juengst and Chávez, 2015), Colombia (Gomez, 1973) and Mexico (Christensen and Winter, 1997; Velascosuarez et al., 1992; Wilkinson, 1975). Some trephined skulls have also been found in North or North-eastern Africa (Martin, 2013; Nikita et al., 2013; Pahl, 1993), Anatolia (Erdal and Erdal, 2011), Russia (Krivoshapkin et al., 2014) and East Asia (Han and Chen, 2007).

Trepanation in Europe is known to have been practiced since the Neolithic (Roberts and Manchester, 1995; Verano and Andrushko, 2010; Weber and Wahl, 2006) including several recent reports, e.g. from Italy (Novak and Knüsel, 1997), Germany (Piek et al., 1999; Weber and Wahl, 2006), Poland (Lorkiewicz et al., 2005) and Portugal (Gama and Cunha, 2003; Silva, 2003). There are older cases of possible trepanations from Mesolithic times summarized by Crubézy et al., (2001). However, these are isolated cases that might lead to different interpretations.

The Late Iron Age in Switzerland spans the time from 450 to 15 BC (Müller et al., 1999). Little is known about the population, also known as the Celtic culture (Birkhan, 2007) as written sources are scarce and often unclear. By contrast, investigations of archaeological remains are a direct scientific source. Research on pathologies (Moghaddam et al., 2013; Ubelaker and Pap, 1998), pre- and perimortem trauma (Armit et al., 2013), as well as nutrition and migration (Le Huray and Schutkowski, 2005; Moghaddam et al., 2014; Oelze et al., 2012) has shed light on life, disease and society of these populations.

This study presents two skulls with lesions from the Late Iron Age cemetery of Münsingen-Rain in Switzerland. The aim was to determine whether the lesions were caused by surgical intervention while the individuals were alive, or if they were caused either by postmortem manipulation or damage.

Furthermore, this work surveys trepanations found in Switzerland, discusses the survival rates and considers sex and age of the affected individuals and localization of the trepanations. Changes in survival rates over time and in different geographical areas might provide explanations for the surgical implementation.

2. Material and methods

The Late Iron Age burial site of Münsingen-Rain (420–240 BC) is situated in the Aare valley near Bern (Fig. 1). It was excavated in 1906 and first published by Wiedmer-Stern (1908). Due to its large size and the abundance of grave goods Münsingen-Rain is an indispensable reference for the Late Iron Age (Müller et al., 1999). In total, 220 burials were found. The skulls of 77 individuals and few long bones were collected; most of the bones were thrown away after the excavation. The burial site presented a horizontal stratigraphy where the individuals were buried in chronological succession from north to south. The northern part dates to the Latène A (450–400 BC) and the southern part to the Latène C period (260–150BC) (Müller, 1998). Two individuals with lesions on the skull were found (Fig. 2a–c). Like most other individuals at the site they were interred with grave goods (Hodson, 1968). Individual A53 was found with a bronze ring, while individual A103 was found with two fibulae and glass fragments. They did not contain weapons even though many other graves at the site did (Jud, 1998; Moghaddam et al., 2014).

2.1. Morphologic-anthropological investigation

All curated bones from Münsingen-Rain have been described in a catalogue (Hug, 1956). Sex and age were re-estimated for both skulls using current anthropological methods (Ferembach et al., 1979; Rösing et al., 2007; Sjøvold, 1988; Szilvássy, 1988). The age at death estimation was based upon cranial suture closure (Acsádi and Nemeskéri, 1970) and dental wear (Brothwell, 1981) as only the skulls were available. The individuals were assigned to different age classes (infants I = 0–6 years; infants II = 7–12 years; juvenile = 13–20 years; adult = 20–40 years; mature = 40–60 years; senile = 60+ years).

Fig. 3. Skull A53 with lesion on the left os parietale.

2.2. Computed tomography

Radiological examinations were performed with a multislice CT scanner (Somatom 6, Siemens Medical Solutions, Germany) with the acquisition parameter set to 110 kV tube voltage and 250 mA tube current. Gantry rotation time was 1.5 s and slice thickness was set to 1.25 mm with 0.60 increment. Images were displayed in a 512 × 512 matrix. For image reconstruction B30 and U90 kernels were used.

2.3. Survival rate

All reported trepanations from different time periods found in Switzerland were compiled (Meyer et al., 2014; Ramseier et al., 2005). To calculate the survival rate by means of the following formula every single trepanation rather than the individuals were taken into consideration (iv = intra vitam, perim = perimortem):

$$\left[\frac{\text{iv}}{\text{perim} + \text{iv}}\right] \times 100$$

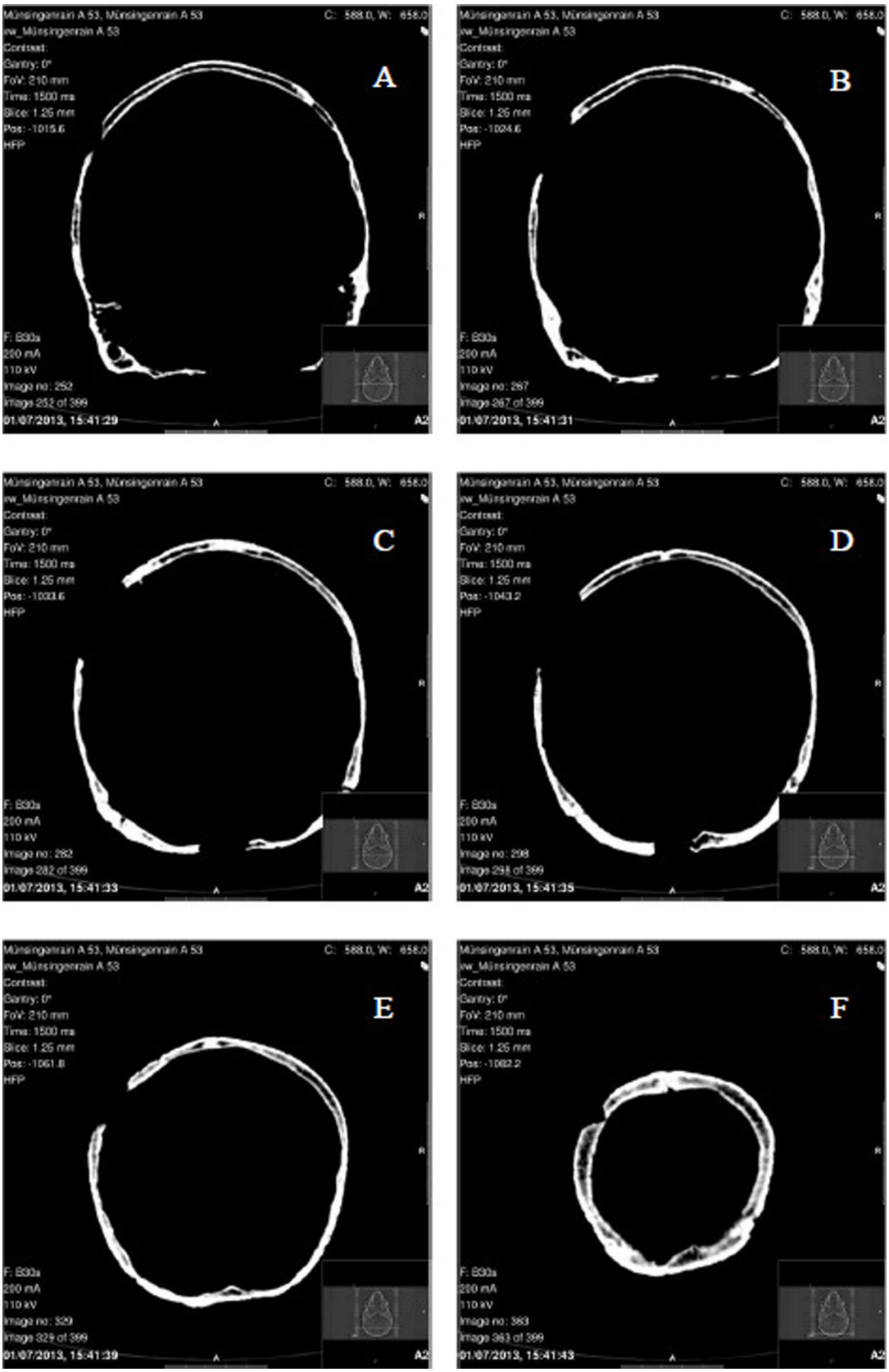

Fig. 4. Coronal computed tomography cross-sections of skull A53. Selected representative slices (A–F).

Fig. 5. Skull A103 with lesions on the left and right ossa parietalia.

3. Results

3.1. Skull A53

The individual has a prominent glabella and large mastoid processes, based on which it was identified as male. The cranial sutures and dental wear placed the age at death in the adult range. No pathological alterations such as cribra orbitalia, cribra cranii, porotic lesions or caries were observed. There is an elliptically shaped lesion on the left os parietale with partly irregular margins and a funnel shape at the anterior and posterior area (Fig. 3). The lesion's maximal length is 50 mm and its maximal width 37 mm. No signs of healing are visible on its margins. CT imaging shows a rounded shape with outward bevelling at the anterior part of the lesion (Fig. 4A–F). The posterior part appears mostly irregular, and CT imaging recorded rather sharp edges (Fig. 4A–F) with no signs of healing.

3.2. Skull A103

The individual is identified as male based on the robust skull with a prominent glabella and a distinctive mandibula. The cranial sutures and dental wear indicate an adult to mature age at death. This skull shows no pathological alteration other than two funnel-shaped openings on both ossa parietalia (Fig. 5). The lesion on the left side is maximally 25 mm long and 22 mm wide on the tabula interna and broadens towards the outside due to bevelled edges. The bevelling is less pronounced in the lesion on the right side. Its maximal length on the tabula interna is 44 mm and its maximal width 37 mm. Due to bad preservation the exact measurement on the outer table is not possible but is thought to be 1–2 mm bigger in size for both trepanations.

Both lesions show characteristic outward bevelling in CT imaging (Fig. 6). While some signs of healing on the right lesion are visible macroscopically, no such signs can be detected on the CT images.

3.3. Trepanations in ancient Switzerland

Table 1 shows a review of 34 cases with 43 alleged trepanations in more detail modified after Ramseier et al., (2005). Three cases for which no detailed information is available (Table 1, marked with stars) are excluded from further evaluation. Most of the reported 31 crania are adults between 20 and 50 years (Table 1). The number of trepanations per cranium varied from one to four, and 32% of the trephined skulls in Switzerland are from the Neolithic, 29% from the Iron Age (including the cases presented here), and 26% from the Early Middle Ages.

3.4. Survival rate

In Switzerland, a total of 57% (23/40) of the surgical interventions were described as intra vitam due to presence of bone reaction. Therefore, the survival rate during the Iron Age is 78%. For the Neolithic it is 72%, for both the Bronze Age and the Late Antiquity it is 100%, whereas a survival rates of 50% was found for the Early Middle Ages. In the Middle Ages it was 0%. One case with four trepanations from Pre-Modern times was described recently for which the survival rate was 75% (Meyer et al., 2014).

4. Discussion

4.1. Skull A53

The lesion appears to be a complete trepanation with both tables perforated. There is no bone reaction, which would have been a sign of vitality, and the individual probably died during or shortly after the surgery. The visibility of details is limited due to the bad preservation of the bone surfaces. However, a postmortem trepanation, later damage or even pathological alterations are unlikely due to the lesion's small size and elongated shape. The funnel shape is indicative of the scraping technique; therefore, no intact bone piece could have been obtained and used as an amulet (Murphy, 2003; Novak et al., 2013). Such amulets from human skull bone are known from the Iron Age, e.g. from France. But until now, no evidence for the Swiss Iron Age exists (Cordier, 2005).

The most likely conclusion is that multiple trepanations were carried out, maybe with a combination of techniques. The funnel shaped areas at the anterior and the posterior part (Fig. 7, marked yellow) suggest that scraping was performed. The lateral and medial areas of the margins are more irregular. The middle part was probably drilled and then removed (Fig. 7, marked red). A second and third surgical intervention may have taken place, because no improvement of symptoms was obtained after the first. The smaller elongated lesion might lead to the suggestion that the trepanation had a therapeutic background and was performed to treat an earlier trauma (Kanz and Grossschmidt, 2006; Müller and Lüscher, 2004).

4.2. Skull A103

Both lesions are nearly symmetric (Fig. 6). The margins indicate that the scraping technique was used, and they seem to have been carried out carefully. The left lesion shows no signs of bone reaction

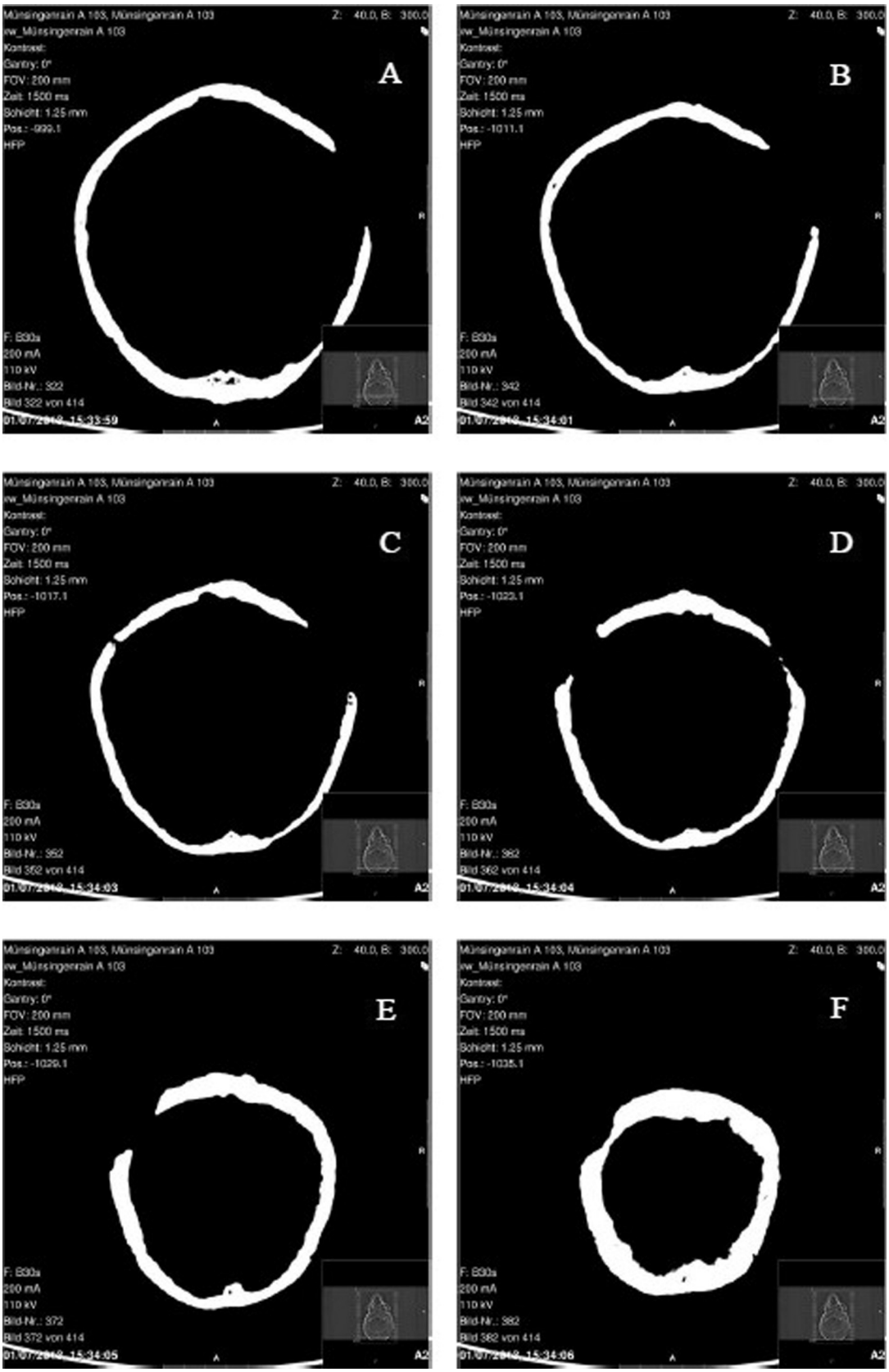

Fig. 6. Coronal computed tomography cross-sections of skull A103. Selected representative slices (A–F).

while the right site shows slight evidence of healing (Fig. 8, marked red) even though this was not detected on the CT images, possibly because of the resolution of 1.25. Analysis with X-ray microtomography in the future could provide more detailed images of the margins (Flohr et al., 2015). The results so far indicate that the right trepanation was done first, followed by the second after some time.

Table 1
Trepanations found in Switzerland. f = female; m = male; l = left; r = right; pm = post mortem; perim = perimortem; iv = intra vitam; nd = not determined; * = uncertain trepanation (modified after Ramseier et al. (2005))

Dating	Site	Grave	Sex	Age	Location of trepanation	Time of surgery	Survival rate
Neolithic	Locras/Lüscherz	nd	nd	n.d.	Occipitale	nd	
	Auvernier	nd	f	35–40	r frontoparietal	perim	
	Saint-Aubin	nd	nd	adult+	r occipital	nd	
	Collombey-Muraz	14	f	37–41	r orbital	perim	
	Sion, Petit-Chasseur	nd	m?	adult+	frontal and parietal	iv/iv	
	Sion, Petit-Chasseur III (H15–204)	nd	m	20–44	l parietal	iv	
	Sion, Petit-Chasseur III (H15–209)	nd	m	25–35	Sutura sagittalis	iv	
	Sion, Petit-Chasseur III (H15–1158)	nd	f	25–35	l frontal, l and r parietal	iv/iv/iv	
	Corseaux-sur-Vevey	1965–3	f?	35	r frontoparietal	iv	
	Zurich, Grosser Hafner	nd	f?	20–30	r parietal	perim	
							72%
Bronze Age	Cressier *	nd	m	adult+	r frontoparietal	pm	
	Gland	nd	f?	adult+	l frontal	iv	
							100%
Iron Age	Basel, Gasfabrik (1)	80	nd	17	r parietal	iv	
	Basel, Gasfabrik *(2)	nd	m	29	l parietal	pm	
	Stettlen-Deisswil	33	m	20–25	l parietal	nd	
	Münsingen-Rain, (A53)	16	m	adult	l parietal	perim	
	Münsingen-Rain, (A103)	152	m	adult+	l and r parietal	perim/iv	
	Sion, Bramois	10	m	40–60	l and r parietal	iv/iv	
	Sion, Sous-le-Scex	430	f	23–45	l parietal	iv	
	Sion, Sous-le-Scex	436	nd	>40	l frontal	iv	
	Sion, Sous-le-Scex	439	m	50–70	l frontoparietal	nd	
	Sion, Sous-le-Scex	546	m	40–50	l parietal	iv	
							78%
Late Antiquity	Windisch	7	m	45	r parietal	iv	100%
Early Middle Ages	Villigen	10	f?	>60	l parietal	nd	
	Villigen *	25	nd	6–7	Frontale	nd	
	Arlesheim	nd	nd	2	Frontale	iv	
	Basel, Aeschenvorstadt	nd	m	30–39	l parietal	iv	
	Basel, Kleinhüningen	108	m	50	l parietal	pm	
	Riaz	184	f?	20–30	r frontal	nd	
	Bonaduz	40	m	20-29	r parietal	iv	
	Bonfol	nd	m	70	occipitale	perim	
	Mels	B1	m	adult+	l and r parietal	perim/perim	
							50%
Middle Age	Basel, Münster	nd	nd	adult+	l parietal	nd	0%
Pre-Moderm Times	Steinhausen	nd	f	>35	l frontal, l parietal	iv/iv/iv/perim	75%

The individual probably died during or short time after the second surgical intervention. Due to their symmetry, it is unlikely that a previous head injury was the reason for the surgery. Recurring headaches or other neurological symptoms are suggested to be an indication for multiple trepanations (Verano and Finger, 2010). This could have been the reason here as well.

4.3. Trepanation in ancient times

In all time periods, the lesions are mostly located in the ossa parietalia (Bennike, 2003; Bereczki et al., 2015; Roberts and Manchester, 1995; Silva, 2003; Weber and Czarnetzki, 2001). Throughout Europe, most cases are Neolithic (Roberts and Manchester, 1995; Verano and Finger, 2010). In Austria, however, most reported trepanations date to the Late Iron Age (54%), and only 7% are Neolithic (Breitwieser, 2003). A distribution similar to that of Switzerland is found in Denmark, where one third of the cases also date to the Iron Age (Bennike, 2003). However, in Britain the majority of trepanations were from the post-Roman Anglo-Saxon period with only 13% dating to the Iron Age (Roberts and McKinley, 2003). Roberts and McKinley (2003) suggest that the practice of trepanation in Britain might have been influenced from continental Europe and became more popular during the Anglo-Saxon period. The Swiss data correspond to the published distributions of continental Europe very well. It should be kept in mind though that not all cases might have been identified or reported.

The trepanation frequency in the total number of preserved skulls from Münsingen-Rain is relatively high with 2.6% compared to an overall frequency of trepanned skulls of 1% for the Iron Age in central Europe (Piek and Terberger, 2008). The high frequency in Münsingen could be due to the fact that the Münsingen population was of high social status (Müller et al., 2008). Additionally, males had a "special" role in the population as stated by stable isotope analysis (Moghaddam et al., 2014). In total, only one trepanned individual from Iron Age Switzerland was female (11%), two were not determined, and six (67%) were male (Table 1). This unbalanced distribution assists the hypothesis that trepanations may have been carried out as a surgical treatment of injuries sustained through interpersonal violence. Similar sex distributions can also be found in other parts of Europe: Roberts and McKinley (2003) found that 65% of the trepanned individuals were males and 13% females during the British Antiquity. Silva (2003) reported 22 trepanations in Neolithic individuals, none of which was female. The abundance of weapons found in male graves in Münsingen-Rain should be kept in mind in this context since it is likely that "warriors" were buried there (Jud, 1998; Müller and Lüscher, 2004). However, items of weaponry could have also been a mandatory attribute of individuals who were not involved in battles.

Most individuals from Iron Age Switzerland show trepanations on the left os parietale (Mariéthoz and Curdy, 2005; Ramseier et al., 2005). This pattern is frequently seen in research of trepanations and trauma (Andrushko and Verano, 2008; Jørgensen, 1988; Verano, 2003). Previous combat with a right-handed adversary is often suggested as an explanation for this observation (Tung, 2007) and should also be considered for Late Iron Age Switzerland.

The drilling technique is indicated for individual A53 in combination with scraping. Drilling technique trepanations in Iron Age skulls are known from Austria suggesting that the technique was

Fig. 7. Skull A53, detail of the lesion on the left os parietale. Yellow: first trepanations by scraping. Red: following trepanation probably by drilling. (For interpretation of the references to color in this figure legend and as well as in the text, the reader is referred to the web version of this article.)



Fig. 8. Skull A103, detail of the lesion on the right os parietale. Red: possible signs of bone healing. (For interpretation of the references to color in this figure legend and as well as in the text, the reader is referred to the web version of this article.)

brought into the Celtic culture via cultural exchange with the Mediterranean world around 400BC. Celtic drills were probably made of organic material, while in Greek and Roman times they were mostly made of iron (Breitwieser, 2003). Whether a trepan made from iron or another drilling tool was used for A53 remains unclear. This individual dates to LTA period (450–400BC) and thus to that time period of cultural exchange.

4.4. Survival rates

The survival rate for Münsingen-Rain is 33% since none of the two individuals survived the surgical intervention, even though individual A103 probably lived for some time after the first trepanation. The scraping technique was used for both individuals. Verano (2003) showed in ancient skulls from South America that those with scraping technique had the highest survival rates. During Swiss Iron Age the skills or medical knowledge may have varied between the different tribes or periods. All individuals from Sion and Basel-Gasfabrik, which date to LTC–LTD period (260–15BC) show bone healing. An explanation for this high rate, compared to Münsingen-Rain, could be that an improvement might have taken place over time.

The total survival rate in Iron Age Switzerland of 78% seems to be relatively high. In contrast to that, only 25% of the trepanations from Iron Age Britain are healed, and the highest survival rate is found in the post-Roman Anglo–Saxon period (Roberts and McKinley, 2003). Even though the sample size is too small for such calculations, as a tendency the survival rate for all cases from Switzerland appears to be relatively high from the Neolithic to the Late Antiquity, but decreases after the Late Antiquity until the Pre-Modern time. Multiple trepanations with high survival rates are also reported from prehistoric Switzerland, some from the Neolithic and also the Iron Age, which one of them is presented in this study. One skull with two trepanations was found from the Early Middle Ages while this individual didn't survive the surgeries. The comparisons of survival rates leads to the assumption that there might have been a higher limitation of infections through natural antiseptics such as herbs and also a certain knowledge of the human body in prehistoric times (Andrushko and Verano, 2008). One case with four trepanations dating to the Pre-Modern times was recently published, three of them with signs of healing (Meyer et al., 2014). This indicates that surgeries were improved again after the Middle Ages.

5. Conclusion

Three trepanations on two skulls from Iron Age Switzerland were investigated. The first case shows one trepanation most likely performed with multiple trepanation techniques. The trepanation was apparently not survived. The second individual shows two trepanations and probably died during or short time after the second surgical intervention.

The high survival rate indicates that neurosurgeries were often performed successfully in prehistoric times. Neurosurgery appears

to be one of the world's oldest specialised professions. The study of ancient surgery sheds light on the culture of prehistoric populations and their understanding of the human body.

Acknowledgements

We would like to thank Felix Müller, Albert Hafner, Viera Trancik and Marc Nussbaumer for support, Christine Cooper for English editing and Domenic Rüttimann for images. We are grateful to both reviewers and editors for their helpful comments. This project was funded by the Swiss National Science Foundation CRI3I3_149583.

References

Acsádi, G., Nemeskéri, J., 1970. History of Human Lifespan and Mortality. Akadémiai Kiadó, Budapest, Hungary.
Andrushko, V.A., Verano, J.W., 2008. Prehistoric trepanation in the Cuzco region of Peru: a view into an ancient Andean practice. Am. J. Phys. Anthropol. 137 (1), 4–13.
Armit, I., Neale, N., Shapland, F., Bosworth, H., Hamilton, D., Mckenzie, J., 2013. The ins and outs of death in the Iron Age: complex funerary treatments at Broxmouth Hillfort, East Lothian. J. Archaeol. (Oxf.) 32 (1), 73–100.
Aufderheide, A.C., Rodríguez-Martín, C., 1998. The Cambridge Encyclopedia of Human Paleopathology. Cambridge University Press, Cambridge.
Bennike, P., 2003. Ancient trepanations and differential diagnosis: a re-evaluation of skeletal remains from denmark. In: Arnott, R., Finger, S., Smith, C.U.M. (Eds.), Trepanation: History, Discovery, Theory. Swets & Zeitlinger, Lisse, pp. 96–115.
Bereczki, Z., Molnár, E., Marcsik, A., Pálfi, G., 2015. Rare types of trephination from Hungary shed new light on possible cross-cultural Connections in the Carpathian Basin. Int. J. Osteoarchaeol. 25, 322–333.
Birkhan, H., 2007. Kelten-Einfälle an der Donau. Akten des vierten Symposiums deutschsprachiger Keltologinnen und Keltologen. Linz/Donau, 17.-21.Juli 2005. Wien: VÖAW.
Breitwieser, 2003. Celtic trepanation in Austria. In: Arnott, R., Finger, S., Smith, C.U.M. (Eds.), Trepanation: History, Discovery, Theory. Swets & Zeitlinger, Lisse, The Netherlands, pp. 147–153.
Brothwell, D.R., 1981. Digging up Bones; The Excavation, Treatment and Study of Human Skeletal Remains. Oxford University Press, Oxford.
Campillo, D., 1984. Neurosurgical pathology in prehistory. Acta Neurochirurgica 70 (3–4), 275–290.
Christensen, A.F., Winter, M., 1997. Culturally modified skeletal remains from the site of Huamelulpan, Oaxaca, Mexico. Int. J. Osteoarchaeol. 7 (5), 467–480.
Cordier, G., 2005. Rondelles crâniennes. Une enquête bibliographique. Bulletin de la Société préhistorique française 102 (2), 361–369.
Crubézy, É., Bruzek, J., Guilaine, J., Cunha, É., Rougé, D., Jelinek, J., 2001. The antiquity of cranial surgery in Europe and in the Mediterranean basin. Cr. Acad. Sci. Ii. A 332 (6), 417–423.
Erdal, Y.S., Erdal, O.D., 2011. A review of trepanations in Anatolia with new cases. Int. J. Osteoarchaeol. 21 (5), 505–534.
Fabbri, P.F., Lonoce, N., Masieri, M., Caramella, D., Valentino, M., Vassallo, S., 2012. Partial cranial trephination by means of Hippocrates' trypanon from 5th century BC Himera (Sicily, Italy). Int. J. Osteoarchaeol. 22 (2), 194–200.
Ferembach, D., Schwidetzky, I., Stloukal, M., 1979. Recommendations for age and sex diagnoses of skeletons. Bulletins et Memoires de la Société d'Anthropologie de Paris [Bulletins and memoirs of the Society of Anthropology of Paris] 6 (1), 7–45.
Flohr, S., Brinker, U., Schramm, A., Kierdorf, U., Staude, A., Piek, J., Jantzen, D., Hauenstein, K., Orschiedt, J., 2015. Flint arrowhead embedded in a human humerus from the Bronze Age site in the Tollense valley, Germany – a high-resolution micro-CT study to distinguish antemortem from perimortem projectile trauma to bone. Int. J. Paleopathol. 9, 76–81.
Gama, R.P., Cunha, E., 2003. A neolithic case of cranial trepanation (Eira Pedrinha, Portugal). In: Arnott, R., Finger, S., Smith, C.U.M. (Eds.), Trepanation: History, Discovery, Theory. Swets & Zeitlinger B.V., Lisse, pp. 131–136.
Gomez, J.G., 1973. Paleoneurosurgery in Colombia. J. Neurosurg. 39 (5), 585–588.
Gross, C.G., 2003. Trepanation from the palaeolithic to the internet. In: Arnott, R., Finger, S., Smith, C.U.M. (Eds.), Trepanation: History, Discovery, Theory. Swet & Zeitlinger B.V., Lisse, pp. 307–322.
Han, K.X., Chen, X.C., 2007. The archaeological evidence of trepanation in early China. Bull. Indo. Pac. Pre. Hi. 27, 22–27.
Hodson, F.R., 1968. The la Tène Cemetery at Münsingen-Rain. Acta Bernensia V. Verlag Stämpfli & CIE AG Bern, Bern.
Hug, E., 1956. Die Anthropologische Sammlung im Naturhistorischen Museum Bern. In: Bern, N.M. (Ed.). Naturhistorisches Museum Bern, Bern.
Jørgensen, J.B., 1988. Trepanation as a therapeutic measure in ancient (Pre-Inca) Peru? Acta neurochirurgica 93 (1–2), 3–5.
Jud, P., 1998. Untersuchungen zur Struktur des Gräberfeldes von Münsingen-Rain. In: Müller, F. (Ed.), Münsingen-Rain, ein Markstein der keltischen Archäologie Funde, Befunde und Methoden im Vergleich Akten des Internationalen Kolloquiums «Das keltische Gräberfeld von Münsingen-Rain 1906-1996». Verlag Bernisches Historisches Museum, Bern.
Juengst, S.L., Chávez, S.J., 2015. Three trepanned skulls from the Copacabana Peninsula in the Titicaca Basin, Bolivia (800 BC–AD 1000). Int. J. Paleopathol. 9, 20–27.
Kanz, F., Grossschmidt, K., 2006. Head injuries of Roman gladiators. Forensic. Sci. Int. 160 (2–3), 207–216.
Kaufman, M.H., Whitaker, D., McTavish, J., 1997. Differential diagnosis of holes in the calvarium: application of modern clinical data to palaeopathology. J. Archaeol. Sci. 24 (3), 193–218.
Krivoshapkin, A.L., Chikisheva, T.A., Zubova, A.V., Kurbatov, V.P., Titov, A.T., Volkov, P.V., 2014. Scythian trepanations in the gorny altai in hippocratic times: modern expert appraisal of ancient surgical technologies. World Neurosurg. 82 (5), e649–e655.
Kurin, D.S., 2013. Trepanation in South-Central Peru during the early Late Intermediate Period (ca. AD 1000–1250). Am. J. Phys. Anthropol. 152 (4), 484–494.
Le Huray, J.D., Schutkowski, H., 2005. Diet and social status during the La Tene period in Bohemia: carbon and nitrogen stable isotope analysis of bone collagen from Kutna Hora–Karlov and Radovesice. J. Anthropol. Archaeol. 24 (2), 135–147.
Lisowski, F.P., 1967. Prehistoric and early historic trepanation. In: Brothwell, D.R., Sandison, A.T. (Eds.), Diseases in Antiquity. Charles C Thomas, Springfield, pp. 372–651.
Lorkiewicz, W., Stolarczyk, H., Smiszkiewicz-Skwarska, A., Zadzinska, E., 2005. An interesting case of prehistoric trepanation from Poland: re-evaluation of the skull from the Franki Suchodolskie site. Int. J. Osteoarchaeol. 15 (2), 115–123.
Margetts, E.L., 1967. Trepanation of the skull by the medicine-men of primitive cultures, with particular reference to present-day native East African practice. In: Brothwell, D.R., Sandison, A.T. (Eds.), Diseases in Antiquity. Charles C Thomas, Springfield, pp. 673–701.
Mariéthoz, F., Curdy, P., 2005. Trepanations from graves from the Late Iron Age (Sion, Valais, Switzerland). Bulletin der Schweizerischen Gesellschaft fér Anthropologie, 59–66.
Marino, R., Gonzales-Portillo, M., 2000. Preconquest Peruvian neurosurgeons: A study of inca and pre-Columbian trephination and the art of medicine in ancient Peru. Neurosurgery 47 (4), 940–950.
Martin, D.C., 2013. Like you need a hole in the head: tool innovation a possible cause of trephination. A case from Kerma, Nubia. Int. J. Osteoarchaeol. 23, 545–556.
Meyer, S., Boschetti, A., Hauri, R., Rühli, F., Böni, T., 2014. A trepanned skull from the 19th century AD found in Steinhausen, Switzerland. Bulletin der Schweizerischen Gesellschaft für Anthropologie 20 (1), 27–33.
Moghaddam, N., Langer, R., Ross, S., Nielsen, E., Lösch, S., 2013. Multiple osteosclerotic lesions in an Iron Age skull from Switzerland (320–250 BC) – an unusual case. Swiss Med. Wkly., 143.
Moghaddam, N., Müller, F., Hafner, A., Lösch, S., 2014. Social Stratigraphy in Late Iron Age Switzerland: Stable Carbon, Nitrogen and Sulphur Isotope Analysis of Human Remains from Münsingen. Archaeological and Anthropological Sciences.
Müller, F., 1998. Münsingen-Rain, ein Markstein der keltischen Archäologie. Funde, Befunde und Methoden im Vergleich. Akten des Internationalen Kolloquiums «Das keltische Gräberfeld von Münsingen-Rain 1906-1996». Verlag Bernisches Historisches Museum, Bern.
Müller, F., Jud, P., Alt, K.W., 2008. Artefacts, skulls and written sources: the social ranking of a Celtic family buried at Munsingen-rain. Antiquity 82 (316), 462–469.
Müller, F., Kaenel, G., Lüscher, G., 1999. Die Schweiz vom Paläolithikum bis zum frühen Mittelalter. SPM IV. Eisenzeit. Verlag Schweizerische Gesellschaft für Ur- und Frühgeschichte, Basel.
Müller, F., Lüscher, G., 2004. Die Kelten in der Schweiz. Konrad Theiss Verlag GmbH, Stuttgart.
Murphy, E.M., 2003. Trepanations and perforated crania from Iron Age south Siberia: An exercise in differential diagnosis. In: Arnott, R., Finger, S., Smith, C.U.M. (Eds.), Trepanation: History, Discovery, Theory. Swets & Zeitlinger B.V., Lisse, pp. 209–221.
Nikita, E., Lahr, M.M., Mattingly, D., 2013. Evidence of Trephinations among the Garamantes, a Late Holocene Saharan Population. Int. J. Osteoarchaeol. 23 (3), 370–377.
Novak, M., Nad, M., Plese, T., Cavka, M., 2013. Skeletal evidence of trepanning on a 5th century skull from Ludbreg, Croatia. AMHA 11 (2), 197–212.
Novak, S.A., Knüsel, C.J., 1997. Comment on Mallegni and Valassina's secondary bone changes to a cranium trepanation in a neolithic man discovered at Trasano, South Italy. Int. J. Osteoarchaeol. 7 (5), 555–557.
Oeftinger, C., Wahl, J., 2000. Eine schnurkeramische Ziercscheibe aus menschlichem Schädelknochen –Versuch einer Interpretation. Fundberichte aus Baden-Württemberg 24, 177–190.
Oelze, V.M., Koch, J.K., Kupke, K., Nehlich, O., Zäuner, S., Wahl, J., Weise, S.M., Rieckhoff, S., Richards, M.P., 2012. Multi-Isotopic analysis reveals individual mobility and diet at the Early Iron Age monumental tumulus of Magdalenenberg, Germany. Am. J. Phys. Anthropol. 148 (3), 406–421.
Ortner, D.J., 2003. Identific Ation of Pathological Conditions in Human Skeletal Remains. Routledge, London.
Pahl, W.M., 1993. Altägyptische Schädelchirurgie. Gustav Fischer Verlag, Stuttgard, Jena, New York.

Piek, J., Lidke, G., Terberger, T., von, S., mekal, U., Gaab, M.R., 1999. Stone age skull surgery in Mecklenburg-Vorpommern: a systematic study. Neurosurgery 45 (1), 147–151, discussion 151.
Piek, J., Terberger, T., 2008. Traumatologische und pathologische Veränderungen an prähistorischen und historischen Skelettresten - Diagnose, Ursachen und Kontext. Marie Leidorf GmbH., Rahden/Westf.
Qureshi, M.M., Oluoch-Olunya, D., 2010. History of neurosurgery in Kenya, East Africa. World Neurosurg. 73 (4), 261–263.
Ramseier, F., Hotz, G., Meyer, L., 2005. Prehistoric Trepanations of Switzerland-From the Neolithic to the Middle Ages. Bulletin der Schweizerischen Gesellschaft für Anthropologie., 1–58.
Roberts, C., Manchester, K., 1995. The Archaeology of Disease. Ian Sutton Publishing Limited, Cornell University Press, Ithaca, New York.
Roberts, C., McKinley, J., 2003. Trepanation in the Portuguese Late Neolithic, Chalcolithic and Early Bronze Age periods. In: Arnott, R., Finger, S., Smith, C.U.M. (Eds.). Swets & Zeitlinger B.V., Lisse, pp. 55–78.
Rose, F.C., 2003. An overview from Neolithic times to Broca. In: Arnott, R., Finger, S., Smith, C.U.M. (Eds.), Trepanation: History, Discovery, Theory. Swet & Zeitlinger B.V., Lisse, pp. 347–363.
Rösing, F.W., Graw, M., Marre, B., Ritz-Timme, S., Rothschild, M.A., Rotzscher, K., Schmeling, A., Schröder, I., Geserick, G., 2007. Recommendations for the forensic diagnosis of sex and age from skeletons. HOMO-J. Comp. Hum. Biol. 58 (1), 75–89.
Silva, A.M., 2003. Trepanation in the Portuguese Late Neolithic, Chalcolithic and Early Bronze Age periods. In: Arnott, R., Finger, S., Smith, C.U.M. (Eds.), Trepanation: History, Discovery, Theory. Swets & Zeitlinger B.V., Lisse, pp. 117–130.
Sjøvold, T., 1988. Geschlechtsdiagnose am Skelett [Sex estimation of the skeleton]. In: Knussmann, R. (Ed.), Anthropologie: Handbuch der vergleichenden Biologie des Menschen [Anthropology: Handbook of Comparative Human Biology]. Gustav Fischer Verlag., Stuttgart, New York, pp. 444–480.
Steinbock, R.T., 1976. Paleopathological Diagnosis and Interpretation: Bone Diseases in Ancient Human Populations. IL: C.C. Thomas, Springfield.
Stevens, G.C., Wakely, J., 1993. Diagnostic Criteria for Identification of Seashell as a Trephination Implement. In.t J. Osteoarchaeol. 3, 167–176.
Szilvássy, J., 1988. Altersdiagnose am Skelett [Age estimation of the skeleton]. In: Knussmann, R. (Ed.), Anthropologie: Handbuch der vergleichenden Biologie des Menschen [Anthropology: Handbook of Comparative Human Biology]. Gustav Fischer Verlag, Stuttgart, New York, pp. 421–435.
Tung, T.A., 2007. Trauma and violence in the Wari empire of the Peruvian Andes: warfare, raids, and ritual fights. Am. J. Phys. Anthropol. 133 (3), 941–956.
Ubelaker, D.H., Pap, I., 1998. Skeletal evidence for health and disease in the Iron Age of northeastern Hungary. Int. J. Osteoarchaeol. 8 (4), 231–251.
Ullrich, H., 1997. Schädeloperationen in der Steinzeit. Mitteilungen der Berliner Gesellschaft für Anthropologie. Ethnologie Urgeschichte 18, 17–32.
Velascosuarez, M., Martinez, J.B., Oliveros, R.G., Weinstein, P.R., 1992. Archaeological origins of cranial surgery – trephination in Mexico. Neurosurgery 31 (2), 313–319.
Verano, J.W., 2003. Trepanation in prehistoric South America: Geographic and temporal trends over 2000 years. In: Arnott, R., Finger, S., Smith, C.U.M. (Eds.), Trepanation: History, Discovery, Theory. Swets & Zeitlinger B.V., Lisse, pp. 223–236.
Verano, J.W., Andrushko, V.A., 2010. Cranioplasty in ancient Peru: a critical review of the evidence, and a unique case from the Cuzco area. Int. J. Osteoarchaeol. 20, 269–279.
Verano, J.W., Finger, S., 2010. Chapter 1: ancient trepanation. Handb. Clin. Neurol. 95, 3–14.
Wahl, J., 2012. Erfolgreiche Steinzeitchirurgen im Taubertal. Verschiedene Operationstechniken und eine hohe Überlebenrate. Denkmalpflege in Baden-Württemberg, 2:83–88.
Weber, J., Czarnetzki, A., 2001. Trepanations from the early medieval period of southwestern Germany – indications, complications and outcome. Zbl. Neurochir. 62 (1), 10–14.
Weber, J., Wahl, J., 2006. Neurosurgical aspects of trepanations from Neolithic times. Int. J. Osteoarchaeol. 16 (6), 536–545.
Wiedmer-Stern, J., 1908. Das Latène-Gräberfeld bei Münsingen (Kt. Bern). Archiv des Historischen Vereins des Kantons Bern 18, 269–361.
Wilkinson, R.G., 1975. Trephination by drilling in ancient Mexico. B NY Acad. Med. 51 (7), 838–850.
Zimmerman, M.R., Trinkaus, E., Lemay, M., Aufderheide, A.C., Reyman, T.A., Marrocco, G.R., Shultes, R.E., Coughlin, E.A., 1981. Trauma and Trephination in a Peruvian Mummy. Am. J. Phys. Anthropol. 55 (4), 497–501.