European Journal of Cardio-Thoracic Surgery Advance Access published December 30, 2015

European Journal of Cardio-Thoracic Surgery (2015) 1–7
doi:10.1093/ejcts/ezv452

ORIGINAL ARTICLE

Cite this article as: Reineke DC, Kaya A, Heinisch PP, Oezdemir B, Winkler B, Huber C *et al*. Long-term follow-up after implantation of the Shelhigh® No-React® complete biological aortic valved conduit. Eur J Cardiothorac Surg 2015; doi:10.1093/ejcts/ezv452.

ADULT CARDIAC

Long-term follow-up after implantation of the Shelhigh® No-React® complete biological aortic valved conduit†

David C. Reineke[a,†,*], Abdullah Kaya[b,†], Paul P. Heinisch[a], Berna Oezdemir[a], Bernhard Winkler[a], Christoph Huber[a], Robin H. Heijmen[b], Wim Morshuis[b], Thierry P. Carrel[a] and Lars Englberger[a]

[a] Department of Cardiovascular Surgery, Inselspital, University of Berne, Bern, Switzerland
[b] Department of Cardiothoracic Surgery, St Antonius Hospital, Nieuwegein, Netherlands

* Corresponding author. Department of Cardiovascular Surgery, Freiburgstrasse 18, 3010 Berne, Switzerland. Tel: +41-31-6322329; fax: +41-31-6329448; e-mail: david.reineke@insel.ch; dr.d.reineke@gmail.com (D.C. Reineke).

Received 17 September 2015; received in revised form 13 November 2015; accepted 26 November 2015

Abstract

OBJECTIVES: Long-term follow-up reports after implantation of the Shelhigh® (Shelhigh, Inc., NJ, USA) No-React® aortic valved conduit used for aortic root replacement do not exist.

METHODS: Between November 1998 and December 2007, the Shelhigh® No-React® aortic valved conduit was implanted in 291 consecutive patients with a mean age of 69.6 ± 9.1 years, and 33.7% were female ($n = 98$). Indications were annulo-aortic ectasia ($n = 202$), aortic valve stenosis combined with ascending aortic aneurysm ($n = 67$), acute type A aortic dissection ($n = 29$), endocarditis ($n = 26$) and other related pathologies ($n = 48$) including 62 patients with previous cardiac surgery. Data from two cardiac institutions were analysed retrospectively using SPSS (SPSS Software IBM, Inc., 2014, NY, USA).

RESULTS: Operative mortality was 10% ($n = 29$). Main cause of death was cardiac failure in 15 patients (51.8%), neurological events in 6 patients (20.7%), respiratory failure in 4 patients (13.8%), bleeding complications in 2 patients (6.9%) and gastrointestinal ischaemia in 2 cases (6.9%). There were 262 hospital survivors and all were entered in the follow-up study (100% complete). During the long-term follow-up (mean 70.3 ± 53.1 in months), a total of 126/262 patients (44.3%) died. Main causes of death in patients after discharge were cardiac ($n = 37$, 14.1%), neurological ($n = 15$, 5.7%) respiratory ($n = 12$, 4.6%), endocarditis ($n = 12$, 4.6%) and peripheral vascular disease ($n = 5$, 1.9%). In 29 (11.1%) patients, the cause of death could not be determined. Reoperation was required in 25 (8.6%) patients due to infection of the conduit ($n = 9$), aortoventricular disconnection ($n = 4$), pseudoaneurysm formation ($n = 4$) and structural valve degeneration ($n = 8$). Reoperations were performed 5.0 ± 3.8 (range 0.1–11.7) years after index surgery.

CONCLUSIONS: The Shelhigh® No-React® aortic valved conduit showed satisfactory short-term operative results. However, the long-term follow-up revealed a relatively high rate of deaths, which may be explained by the epidemiology of the patient group, but a substantial proportion of deaths could not be clarified. The overall rate of reoperation (8.6%) during the mid-term follow-up is worrisome and the failures due to aortoventricular disconnection, endocarditis and pseudoaneurysm formation remain unexplained. The redo-procedures were technically demanding. We recommend close follow-up of patients with the Shelhigh® No-React® aortic valved conduit, because besides classical structural valve degeneration, unexpected findings may be observed.

Keywords: Aortic valve • Root replacement • Complete biological conduit • Long-term outcome

INTRODUCTION

Beside aortic valve sparing techniques and homograft implantation, mechanical and self-assembled composite-grafts using a tissue valve are the most common choices for aortic root replacement in adults. In the past, Shelhigh®, Inc., NJ, USA, provided an alternative biological implant, the Shelhigh® No-React® valved bioconduit, which consisted of a bovine pericardial straight graft with an incorporated porcine stentless valve. No long-term clinical data with this material exist so far. The technical ease to implant such a conduit and promising short-term results favoured the dissemination of the Shelhigh® No-React® valved conduit that was routinely implanted in patients with an indication for a biological aortic root replacement [1–5]. However, conflicting clinical results were observed in some institutions during the further follow-up period and some dramatic cases of patients presenting with sudden disintegration of the graft requiring urgent and extensive reoperation were reported [6–9]. In this paper, clinical experience and long-term results of patients who received a Shelhigh® No-React® aortic valve conduit at two institutions are reported.

†Presented at the 29th Annual Meeting of the European Association for Cardio-Thoracic Surgery, Amsterdam, Netherlands, 3–7 October 2015.
†The first two author contributed equally to this work.

METHODS

Patient population

Between November 1998 and December 2007, the Shelhigh® No-React® aortic valved conduit was consecutively implanted in 291 patients with a mean age of 69.6 ± 9.1 years. Of them, 33.7% were female ($n = 98$). Other demographic variables are presented in Table 1. The patient cohort underwent aortic root replacement when (i) the valve could not be preserved to perform a David procedure, (ii) the patient was not a suitable candidate for a pulmonary autograft procedure and (iii) a mechanical valve was not indicated.

The conduit was used in patients with various pathologies, including 62 patients (21.3%) with previous cardiac or aortic surgery (Table 2). Only 38 (13.1%) patients underwent isolated implantation of the Shelhigh® No-React® conduit. The majority underwent combined interventions. In 45 patients (15.5%), the operation was performed in an emergency situation. Statistical analyses showed no significant difference between the age of emergency and elective cases ($P = 0.2117$). Marfan syndrome was diagnosed in only 5 patients of the study group (1.7%).

Cardiopulmonary bypass (CPB) time, the type of combined procedures and deep hypothermic circulatory arrest (DHCA) times are presented in Table 2.

The Shelhigh® No-React® valved conduit

The Shelhigh® No-React® aortic valve conduit consists of a bovine straight graft (length 150 mm) with an incorporated porcine stentless valve, manufactured in sizes from 21 to 31 mm. The valve is constructed using three non-coronary aortic porcine cusps, which are thereafter fitted on a scallop-shaped tubular bovine pericardium. The conduit and the valve are glutaraldehyde cross-linked, detoxified and heparin treated with the No-React® protocol. This proprietary detoxification process is described as it would eliminate residual glutaraldehyde and ensure stable tissue cross-linking with less calcification and tissue deterioration in the long term [10, 11]. Rinsing before implantation is not required. The pericardial cuff can be trimmed appropriately for each individual case.

Procedure

All patients were operated through full midline sternotomy. Aortic root replacement was performed under standard CPB using the modified button technique for re-attachment of the coronary artery ostia [12]. DHCA combined with selective antegrade cerebral perfusion was used in 128 cases (44%) when the repair extended into the aortic arch. During the removal of the diseased aortic root and ascending aorta, the coronary ostia were excised with a small rim of surrounding aortic tissue. After assessment of the aortic annulus with sizers provided by the company, a

Table 1: Preoperative patient characteristics

Patient characteristics	*n*	%
Number of patients	291	
Age (years)		
Mean (SD; range)	69.6 (±9.1; 14–85)	
Gender		
Male	193	(66.3)
Female	98	(33.7)
NYHA		
I	56	(19.2)
II	108	(37.1)
III	84	(28.9)
IV	43	(14.8)
Comorbid medical conditions		
Hypertension	205	(70.4)
Diabetes	23	(7.9)
CAD	24	(8.2)
COPD	30	(10.3)
Renal dysfunction	32	(11.0)

Values are *n* (%) or mean ± SD (range).
SD: standard deviation; CAD: coronary artery disease; COPD: chronic obstructive pulmonary disease; NYHA: New York Heart Association.

Table 2: Main pathology and operative procedures

	n	%
Aneurysmatic disease	217	(74.6)
Degenerative	206	
False	7	
Post-dissection	4	
Acute type A aortic dissection	29	(10.0)
Calcified aortic root	9	(3.1)
Other complex pathologies (e.g. other valve disease)	48	(16.5)
Aortic valve endocarditis	26	(8.9)
Prosthetic	17	
Native	9	
Valvular disease		
Aortic valve regurgitation		
Grade I	101	(34.7)
Grade II	51	(17.5)
Grade III	88	(30.2)
Grade IV	50	(17.2)
Aortic valve stenosis	81	(27.8)
Mean gradient (mmHg) (SD; range)	37.1 (±14.9; 17–78)	
Combined aortic valve lesion	50	(17.2)
Marfan syndrome	5	(1.7)
Bicuspid aortic valve	41	(14.1)
Reoperations	63	(21.6)
Previous aortic valve surgery	45	
Intraoperative data		
Emergency	45	(15.5)
Elective	246	(84.5)
Cardiopulmonary bypass (min)		
CPB time (mean; SD; range)	148.5 (±58.6; 64–354)	
Aortic cross-clamp (mean; SD; range)	102.3 (±34.9; 39–262)	
DHCA (mean; SD; range)	20.2 (±9.3; 6–50)	
Procedures		
Isolated Shelhigh conduit	38	(13.1)
Combined procedures	253	(86.9)
+ hemiarch/arch-replacements	221	(75.9)
+ CABG	91	(31.3)
Others (e.g. mitral valve surgery, tricuspid valve surgery)	48	(16.5)

Values are *n* (%) or mean ± SD (range).
CABG: coronary artery bypass grafting; CPB: cardiopulmonary bypass; DHCA: deep hypothermic circulatory arrest; SD: standard deviation.

one-size oversized valved conduit was usually implanted. The proximal suture technique between the conduit and the aortic annulus was performed according to the most usual technique in the institution and consisted of either three separate, continuous 4-0 polypropylene sutures ($n = 129$, 44.3%) or interrupted pledget-supported sutures ($n = 162$, 55.7%), placed outside of the aortic root. The coronary ostia were re-inserted into the conduit with 5-0 or 6-0 running monofilament sutures. Finally, the distal anastomosis was performed with 4-0 running polypropylene sutures. Sutures at the coronary ostia or the aorta were supported with xenopericardium if necessary, depending on the weakness or not of the aortic tissue.

Data collection and follow-up modalities

Perioperative data were retrieved from our prospectively managed institutional database (Dendrite Clinical Systems Ltd, Henley-on-Thames, UK). Closing date for all follow-up investigations was 1 September 2014. Follow-up was 100% complete with an average follow-up time of 5.8 ± 4.08 years (range 0.1–14.8 years). Dates of death were confirmed with data from local public authorities. For this study, the time span for early mortality was defined as the period within 12 months after surgery and for late mortality the time period was defined over 12 months after surgery. The end-points were defined according to the guidelines reported by Akins *et al.* [13].

Statistical methods

Kaplan–Meier estimates were calculated separately for the end-points death and reoperation and combined (death or reoperation), followed by corresponding life table analyses. Reoperation needs to be analysed taking into account mortality, as death and reoperation are not independent end-points. For example, patients may die too early to be reoperated. With respect to the aim of the study, we are interested in the specific reoperation rate as a feature of Shelhigh® No-React®, 'adjusted' for the risk of death. So we used competing risks regression models to produce a cumulated incidence function via maximum likelihood, according to the method of Fine and Gray (1999). On the other hand, patients with severe valve deterioration may not be reoperated because they are too frail and may die shortly after severe valve deterioration is diagnosed. Such cases are better represented in the combined end-point analysis, which we consider the most appropriate way of analysing these data.

All confidence intervals (CIs) are two sided and analyses have been done using Stata 12.

RESULTS

Early results

The overall early mortality was 10.0% ($n = 29$). Sixteen (6.5%) patients died following elective surgery and 13 patients (28%) after emergency procedure. There were 4 patients who died intraoperatively (1.4%). Patients who died intraoperatively had either poor left ventricular function (ejection fraction ≤25%) or underwent emergency operations ($n = 3$). The causes of death were cardiac failure, myocardial infarction and electromechanical dissociation after ventricular fibrillation. In the postoperative in-hospital phase were 25 cases (8.6%) of mortality. The reasons for death in elective cases ($n = 15$) were ischaemic cardiac ($n = 7$), cerebrovascular ($n = 43$), respiratory failure ($n = 3$) and bleeding in 2 cases. The overall in-hospital mortality or emergency cases was 4.4% ($n = 13$). No independent association could be found between age at index surgery and hospital mortality ($P = 0.5778$). The hospital mortality for patients with an aortic aneurysm (non-dissection and non-endocarditis) having elective surgery was 3.7% ($n = 8$). Causes of in-hospital death are summarized in Table 3.

Late results

There were 262 hospital survivors and all were entered in the follow-up study (100% complete). Long-term follow-up was at mean 70.3 ± 53.1 months and median 71.5 months. Total follow-up was 1703 patient-years. During the follow-up, a total of 126 patients (48.1%) died. Causes of death are summarized in Table 3. In the first year after the operation, 22 patients died (17.5%). Of those, 4 patients died due to endocarditis of the conduit. Main causes of death during follow-up are summarized in Table 3. After the first postoperative year, there were 8 cases of prosthesis-related deaths due to endocarditis or infectious complication of the tube-graft. Out of the remaining 114 patients with non-prosthesis-related

Table 3: Causes of early and late death

n = 155	*n*	%
Early: in hospital	29	(10.0)
Operative	4	(1.4)
Elective: arrhythmia	1	(0.3)
Emergency	3	(1.0)
Heart failure	2	
Ischaemic	1	
Postoperative, hospital	25	(8.6)
Elective	15	(57.7)
Cardiac	7	
Cerebrovascular accident	3	
Respiratory failure	3	
Bleeding (proximal anastomosis)	2	
Emergency	10	(34.5)
Cardiac	4	
Cerebrovascular accident	3	
Respiratory failure	1	
Gastrointestinal ischaemia	2	
Late: follow-up	126	(48.1)
Early (<1 year)	22	
Late (>1 year)	104	
Prosthesis related	12	
Endocarditis	12	(4.6)
Early (<1 year)	4	
Late (>1 year)	8	
Cardiac	37	(14.1)
Neurological	15	(5.7)
Respiratory	12	(4.6)
Cancer	14	(5.3)
Vascular (peripheral)	5	(1.9)
Dissection	1	(0.4)
Ruptured aneurysm	1	(0.4)
Sudden, unexplained	29	(11.1)

Values are *n* (%) or mean ± SD (range).
SD: standard deviation.

late deaths, 37 patients died of cardiac causes (14.1%). One patient suffered from recurrent endocarditis of the biological mitral valve prosthesis (Shelhigh®), with vegetations in echocardiography. The overall survivals at 1, 5, 10 and 12 years were 83 (95% CI 78–87), 65 (95% CI 59–71), 44 (95% CI 37–50) and 29% (95% CI 20–37), respectively. This information is presented in Fig. 1 for the total group and selectively for the patients having elective and emergency operations. For the complete follow-up period, a significant difference between the elective and emergency groups could be detected ($P = 0.012$).

Reoperations

During the follow-up observation interval, a total of 25 patients (8.6%) required reoperation. The mean age of these patients was 62.8 ± 14.3 years at initial aortic root replacement with the Shelhigh® No-React® conduit. The mean length of time between the first aortic root replacement and reoperation was 5.0 ± 3.8 years (Table 4).

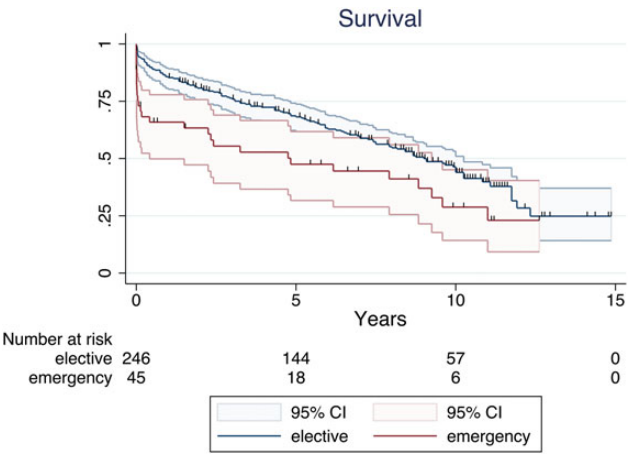

Figure 1: Kaplan–Meier survival of elective and emergency cases. CI: 95% confidence interval.

Table 4: Reoperations

	n	%
Number of patients	25	(8.6)
Age at index surgery (mean ± SD; range)	62.8	(±14.3; 14–78)
Years to reoperation (mean ± SD; range)	5.2	(±3.4; 0.1–11.7)
Mode of failure		
Aortoventricular disconnection	4	(16.0)
Coronary pseudoaneurysm	4	(16.0)
Endocarditis	9	(38.0)
SVD	8	(32.0)
New prosthesis		
Transcatheter aortic valve	5	(20.0)
Conventional surgical	19	(76.0)
No replacement	1	(4.0)
Mortality	6	(28.0)
In-hospital	2	(8.0)
Intraoperative	1	(4.0)
Postoperative	1	(4.0)
Out-of-hospital	4	(16.0)

Values are *n* (%) or mean ± SD (range).
SD: standard deviation; SVD: structural valve degeneration.

The main reasons for reoperation (Table 5) were endocarditis of the conduit ($n = 9$), aortoventricular disconnection ($n = 4$), coronary pseudoaneurysm ($n = 4$) and structural valve deterioration ($n = 8$). In 6 cases, the reoperation was within 1 year after index surgery and the main indications were endocarditis ($n = 4$), structural valve deterioration ($n = 1$) and aortoventricular disconnection ($n = 1$). In 1 case, early structural valve deterioration was diagnosed after <1 year postoperatively with a mean gradient of 40 mmHg and an opening area of 0.5 cm^2. At reoperation, the Shelhigh® valve showed massive deterioration of all three leaflets.

One patient had previously undergone an isolated aortic valve replacement with a Shelhigh® No-React® stentless valve because of aortic valve stenosis. One year after implantation, the patient was diagnosed with a high trans-valvular gradient but normal leaflet motion. The necessity for a redo surgical procedure was given and surprisingly showed a partial destruction of the aortic root. Prosthetic valve endocarditis was suspected and the aortic root was replaced with implantation of a Shelhigh® No-React® valved conduit. Eleven months later, the patient's echocardiography showed moderate aortic regurgitation, severe mitral regurgitation and aortic root rupture at the level of the right coronary sinus. Reoperation showed a huge false aneurysm with destruction of the aortomitral continuity, whereas the right coronary artery ostium and the distal graft to the native aortic anastomosis were completely dehiscent. The second attempt to replace the destroyed aortic root with a Shelhigh® No-React® conduit in combination with hemiarch replacement and CABG was not successful. The patient could not be weaned from CPB and died intraoperatively after complex surgery due to biventricular failure.

In addition to these complex structural problems, there were 8 patients (32%) with more classical structural valve deterioration with a clinical presentation as a recurrent aortic stenosis or aortic regurgitation. Of these 8 cases, 5 patients received a transcatheter aortic valve implantation (TAVI) in more recent years. Overall in-hospital mortality following reoperations ($n = 25$) was at 8% ($n = 2$).

Of the patients who survived a redo procedure ($n = 23$), 19 patients were alive at follow-up (Table 5). The overall freedom of reoperation at 1, 5, 10 and 12 years was 98% (95% CI 96–99), 96% (95% CI 92–98), 88% (95% CI 81–92) and 71% (95% CI 53–83), respectively (Fig. 2). The freedom of competing risks for the combined end-points death and reoperation at 1, 5, 10 and 12 years was 82% (95% CI 77–86), 63% (95% CI 57–68), 39% (95% CI 32–45) and 20% (95% CI 13–28), respectively. The results are summarized in Figs 2 and 3 for the combined end-points.

DISCUSSION

This paper analysed the long-term follow-up of patients who received a Shelhigh® No-React® aortic valved bioconduit at two institutions. One of the most important observations is a relatively high overall rate of reoperation and mortality. Patients who required a redo-procedure were demanding due to mechanism of graft failure. Following quite promising short-term results and due to the technical ease of implantation, several institutions have adopted a liberal strategy to implant this valved bioconduit, despite the fact that no mid- or long-term results were available at that time. Unfortunately, some patients developed complications that were not previously described with other conduits [1–5].

Table 5: Summary of patients with reoperation and detailed work-up with modes of failure

Case	Gender	Age	Indication	Add procedure	Years to reoperation	Mode of failure	TAVI	Mortality		Follow-up
								in operative	in hospital	
1	Male	62	Aneurysmatic disease, aortic regurgitation, aortic valve stenosis	CABG	11.7	Structural valvular degeneration	Yes	No	No	Alive
2	Male	62	Type A dissection, aortic regurgitation, CAD	DHCA, hemiarch replacement	11.7	Structural valvular degeneration	Yes	No	No	Alive
3	Male	46	Aneurysmatic disease, aortic regurgitation	DHCA, hemiarch replacement, CABG × 1	2.9	Aortoventricular disconnection	No	No	No	Alive
4	Male	63	Aneurysmatic disease, aortic regurgitation		9.9	Structural valvular degeneration	No	No	No	Alive
5	Male	73	Type A dissection, aortic regurgitation, CAD	DHCA, hemiarch replacement, CABG × 2	5.7	Coronary pseudoaneurysm	No	No	No	Alive
6	Male	14	Aneurysmatic disease, bicuspid valve, Marfan syndrome		1.9	Aortoventricular disconnection	No	No	No	Alive
7	Male	66	Aneurysmatic disease, aortic regurgitation		1.1	Aortoventricular disconnection	No	No	No	Dead
8	Male	65	Aneurysmatic disease, CAD	CABG × 2	6.5	Endocarditis	No	No	No	Dead
9	Male	36	Aneurysmatic disease, aortic regurgitation, aortic valve stenosis		4.6	Coronary pseudoaneurysm	No	No	No	Alive
10	Male	64	Type A dissection	DHCA, hemiarch replacement	7.3	Structural valvular degeneration	No	No	No	Alive
11	Female	74	Reoperation biological aortic valve endocarditis		0.8	Aortoventricular disconnection	No	Yes	No	Dead
12	Male	76	Reoperation mechanical aortic valve, annulo-aortic ectasia, CAD	CABG	8.7	Structural valvular degeneration	Yes	No	Yes	Dead
13	Female	78	Aneurysmatic disease, aortic regurgitation	DHCA, hemiarch replacement	0.8	Endocarditis	No	No	No	Alive
14	Male	60	Aneurysmatic disease, aortic regurgitation, aortic valve stenosis	DHCA, hemiarch replacement	0.7	Structural valvular degeneration	No	No	No	Alive
15	Male	76	Aneurysmatic disease, aortic regurgitation, CAD	CABG	7.6	Structural valvular degeneration	Yes	No	No	Alive
16	Male	34	Aneurysmatic disease, aortic regurgitation		8.7	Endocarditis	No	No	No	Alive
17	Female	70	Aneurysmatic disease, aortic valve stenosis		1.8	Endocarditis	No	No	No	Alive
18	Male	69	Aneurysmatic disease, aortic valve regurgitation		9.5	Structural valvular degeneration	Yes	No	No	Alive
19	Female	68	Aneurysmatic disease, aortic valve regurgitation		4.7	Endocarditis	No	No	No	Alive
20	Male	70	Aneurysmatic disease, aortic valve regurgitation		3.1	Coronary pseudoaneurysm	No	No	No	Alive
21	Female	71	Aneurysmatic disease, aortic valve regurgitation	DHCA, hemiarch replacement, CABG	7.6	Endocarditis	No	No	No	Alive
22	Male	67	Aortic valve regurgitation	Redo composite graft, CABG	0.2	Endocarditis	No	No	No	Alive
23	Male	78	Aneurysmatic disease, aortic valve regurgitation		0.1	Endocarditis	No	No	No	Dead
24	Female	60	Endocarditis		6.3	Coronary pseudoaneurysm	No	No	No	Dead
25	Female	69	Aneurysmatic disease, aortic valve regurgitation		0.8	Endocarditis	No	No	No	Alive

CABG: coronary artery bypass grafting; DHCA: deep hypothermic circulatory arrest; CAD: coronary artery disease; TAVI: transcatheter aortic valve implantation.

Totally biological valved conduits like the Shelhigh® No-React® valved graft were expected to combine several advantages for patients that need aortic root replacement. The stentless design promised superior haemodynamic performance as opposed to stented tissue valves. Other biological composite grafts had to be created intraoperatively by suturing a conventional tissue valve in

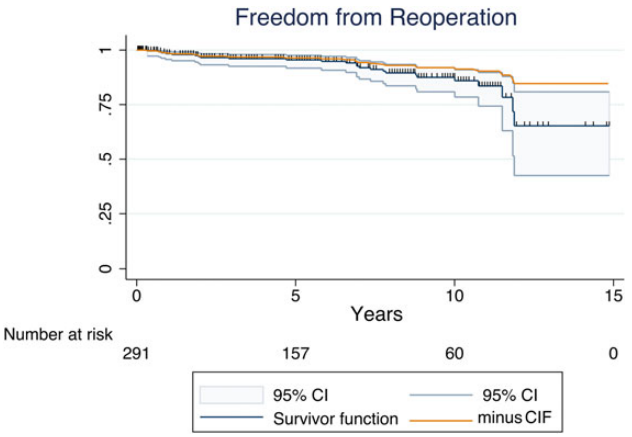

Figure 2: Kaplan–Meier for freedom of reoperation. CIF: cumulated incidence functions; CI: 95% confidence interval.

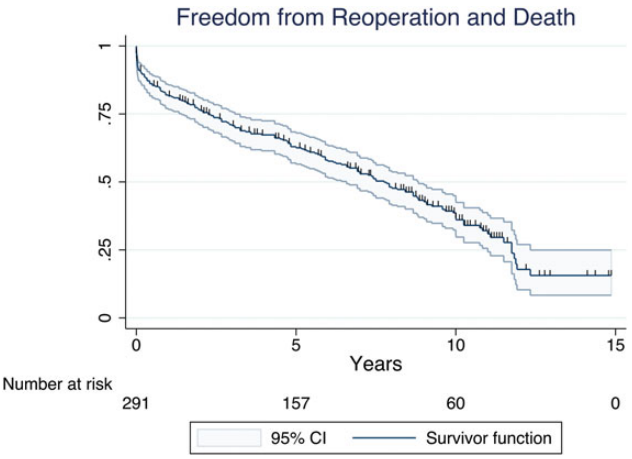

Figure 3: Kaplan–Meier for freedom of reoperation and death. Cumulated incidence functions. CI: 95% confidence interval.

a Dacron aortic prosthesis. In addition, traditional glutaraldehyde-preserved biological valves tended to calcify, especially in younger patients, whereas the novel No-React® detoxification process promised to eliminate residual glutaraldehyde and to ensure stable tissue cross-linking, resulting in less or absent calcification and tissue deterioration in the animal model [10, 11]. And finally, the availability and easy storage of the conduit (21–31 mm) as opposed to homografts with their suboptimal durability was an additional advantage [14].

Initial clinical experience was very satisfactory regarding the technical handling of the graft, the postoperative haemodynamics and the short-term clinical results [1–5]. In addition, excellent short-term outcome data were demonstrated by several teams in the UK and Germany when a Shelhigh® No-React® valve or a valved conduit was used in infective valve endocarditis [2–4]. As a result, we optimistically implanted routinely the Shelhigh® No-React® valved graft in patients scheduled for a biological aortic root replacement. After a short positive experience, our expectations were increasingly clouded by several patients presenting with abrupt disintegration of the graft along with rupture of the aortic root requiring urgent and extensive reoperation [6, 7, 9]. At that time, exchange with other institutions that implanted this conduit revealed that our observations were not singular, and later on, some case reports were published on the same problem. The aim of the current study was to present substantial data on long-term results of two institutions with a similar number of patients.

The initial favourable preliminary haemodynamic and clinical results could not be observed in the long term. Since the graft does not contain any fabric or mechanical components, it was thought to be ideal for the treatment of the infected root as an off-the-shelf alternative to homografts. Availability and handling made it the graft of choice in patients with combined and complex surgical procedures, reflected by the low number of patients who received isolated aortic root replacement (Table 2). The high rate of deaths in our long-term follow-up might therefore be at least explained by the special characteristics of these patients. But 8 patients surprisingly showed an identical finding that consisted in an 'autodestruction' of the graft at the level of the aortic root with the formation of pseudo-aneurysms.

At reoperations, the graft could be removed by simple pulling, without using scissors. Furthermore, initial suspicion for endocarditis could not be confirmed with negative intraoperative biopsies and blood cultures.

Our observation concerning graft degeneration is similar to that of Calderon *et al*. who presented a series of 51 consecutive patients with a reoperation rate of 13% (7/51) after Shelhigh® No-React® conduit implants [15]. All patients of this series demonstrated a similar finding to ours with a disintegration of the proximal anastomosis at the level of the aortic annulus within 1 year after implantation. The intraoperative findings were comparable with our patient group that underwent reoperation, with pseudo-aneurysmal formation and sterile abscess formation [7, 9].

Some authors of this paper also presented worrisome mid-term results. High incidence of culture-negative endocarditis in the Shelhigh® No-React® conduit has forced the group to look for alternatives [8]. It has to be questioned if this was not the first report of classical mode of failure in the form of aortoventricular disconnection due to graft disintegration.

Results from an extensive work of a group in Munich have independently focused on a No-React® patch used for pericardial closure in 127 patients. Interestingly, their clinical data also revealed a high incidence of subacute sterile abscess formation. Their work-up revealed an increased proinflammatory potential limited to the vicinity of the No-React® patch. Bacterial growth was never found. The underlying course of sterile abscess formation was suspected to be an immunogenic reaction in the form of a xenogeneic complement mediated graft rejection [16].

These findings shed light on similar experiences in smaller patient cohorts and our own experience where graft disintegration combined with sterile abscess formation was initially misdiagnosed as culture-negative conduit endocarditis.

The premature failure of the Shelhigh® No-React® porcine pulmonary valve conduit and the role of an immunological reaction [17, 18] suggested that this may well have been a product or process-specific phenomenon which culminated in a preliminary public health notification by the FDA on possible contamination and malfunction of devices manufactured by Shelhigh®, Inc. [19].

Conflicting results with the Berlin group that does not seem to have observed any similar problems despite a large experience with the Shelhigh® No-React® conduit might be due to the fact that their data rely mainly on the isolated use of the stentless valve which might provoke less immunological reaction [3, 4, 20, 21].

After a certain period of time, failure of the graft that may present as aortoventricular disconnection combined with sterile abscess formation seems to become less frequent. This could be due to the fact that the immunogenic response is limited to the

first years after implantation. The mode of failure then seems to be replaced by the classical structural valve degeneration where treatment can focus on the calcified valve. This is mirrored by our small series of TAVI in these patients [22].

This report that combines the long-term observation of two institutions is most probably one of the largest series reporting on Shelhigh® No-React® biocomposite grafts. In the long-term follow-up, we observed a worrisome rate of reoperation and deaths. We believe that the current finding may well support the hypothesis that part of the problems we observed (e.g. aortoventricular disconnection) is a product-specific immune response limited to the first years after implant. We have stopped the implantation of Shelhigh® conduits years ago and recommend close follow-up of patients with the Shelhigh® No-React® aortic valved conduit.

ACKNOWLEDGEMENTS

The authors thank Brigitta Gahl for their help and assistance.

Conflict of interest: none declared.

REFERENCES

[1] Carrel TP, Berdat P, Englberger L, Eckstein F, Immer F, Seiler C *et al*. Aortic root replacement with a new stentless aortic valve xenograft conduit: preliminary hemodynamic and clinical results. J Heart Valve Dis 2003;12: 752–7.

[2] Siniawski H, Lehmkuhl H, Weng Y, Pasic M, Yankah C, Hoffmann M *et al*. Stentless aortic valves as an alternative to homografts for valve replacement in active infective endocarditis complicated by ring abscess. Ann Thorac Surg 2003;75:803–8; discussion 808.

[3] Musci M, Siniawski H, Pasic M, Weng Y, Loforte A, Kosky S *et al*. Surgical therapy in patients with active infective endocarditis: seven-year single centre experience in a subgroup of 255 patients treated with the Shelhigh stentless bioprosthesis. Eur J Cardiothorac Surg 2008;34:410–7.

[4] Musci M, Siniawski H, Knosalla C, Grauhan O, Weng Y, Pasic M *et al*. Early and mid-term results of the Shelhigh stentless bioprosthesis in patients with active infective endocarditis. Clin Res Cardiol 2006;95:247–53.

[5] Cattaneo P, Bruno VD, Mariscalco G, Marchetti P, Ferrarese S, Salerno-Uriarte J *et al*. Early hemodynamic results of the Shelhigh SuperStentless aortic bioprostheses. J Card Surg 2007;22:379–84.

[6] Tjan TDT, Klotz S, Schmid C, Scheld HH. Creation of a self-made total artificial heart using combined components of available ventricular assist devices. Thorac Cardiovasc Surg 2008;56:51–3.

[7] Carrel TP, Schoenhoff FS, Schmidli J, Stalder M, Eckstein FS, Englberger L. Deleterious outcome of No-React-treated stentless valved conduits after aortic root replacement: why were warnings ignored? J Thorac Cardiovasc Surg 2008;136:52–7.

[8] Kaya A, Heijmen RH, Kelder JC, Schepens MA, Morshuis WJ. Stentless biological valved conduit for aortic root replacement: initial experience with the Shelhigh BioConduit model NR-2000C. J Thorac Cardiovasc Surg 2011;141:1157–62.

[9] Carrel TP. Another disastrous outcome following aortic root replacement with the Shelhigh No-react aortic valved tube. Thorac Cardiovasc Surg 2008;56:314–5.

[10] Abolhoda A, Yu S, Oyarzun JR, McCormick JR, Bogden JD, Gabbay S. Calcification of bovine pericardium: glutaraldehyde versus No-React biomodification. Ann Thorac Surg 1996;62:169–74.

[11] Abolhoda A, Yu S, Oyarzun JR, Allen KR, McCormick JR, Han S *et al*. No-react detoxification process: a superior anticalcification method for bioprostheses. Ann Thorac Surg 1996;62:1724–30.

[12] Kouchoukos NT, Wareing TH, Murphy SF, Perrillo JB. Sixteen-year experience with aortic root replacement. Results of 172 operations. Ann Surg 1991;214:308–18 discussion 318–20.

[13] Akins CW, Turina MI, Kouchoukos NT, Shahian DM, Hagl S, Mayer JE *et al*. Guidelines for reporting mortality and morbidity after cardiac valve interventions. J Thorac Cardiovasc Surg 2008;135:732–8.

[14] Kaya A, Schepens MA, Morshuis WJ, Heijmen RH, Brutel de la Riviere A, Dossche KM. Valve-related events after aortic root replacement with cryopreserved aortic homografts. Ann Thorac Surg 2005;79:1491–5.

[15] Calderon E, Spina A, Camurri N, Bellieni L, Bentini C, Pugliese P. Early failure of Shelhigh bioconduit in aortic position: an underestimated drawback. In: Fifth Biennal Meeting of the Society of Heart Valve Disease, Berlin, 2009.

[16] Elmer C. Experimental work-up of the bovine NO-REACT pericardial patch used in cardiac surgery in conjunction with late complications after its application. *Doctoral Thesis*. Institute of Surgical Research, Ludwigs-Maximilians-University-Munich, Germany, 2007.

[17] Ishizaka T, Ohye RG, Goldberg CS, Ramsburg SR, Suzuki T, Devaney EJ *et al*. Premature failure of small-sized Shelhigh No-React porcine pulmonic valve conduit model NR-4000. Euro J Cardiothorac Surg 2003;23: 715–8.

[18] Boudjemline Y, Beyler C, Bonnet D, Sidi D. Surprising outcome similarities between Contegra bovine jugular vein conduit and Shelhigh No-React porcine pulmonary valve conduit: role of immunologic reaction. Eur J Cardiothorac Surg 2003;24:850–1; author reply 851.

[19] FDA preliminary public health notification: possible contamination and malfunction of heart valves and valved conduits, annuloplasty rings, surgical grafts, meshes and other devices manufactured by Shelhigh, Inc. 2007. www.fda.gov/cdrh/safety/041807-shelhigh.html (22 August 2007, date last accessed).

[20] Musci M, Siniawski H, Hetzer R. Shelhigh bioprosthesis in active infective endocarditis. J Thorac Cardiovasc Surg 2009;137:1295–6; author reply 1296–7.

[21] Gabbay S. Why are the results reported from this center inconsistent with the general experience of 4000 implants and 10 years of follow-up? J Thorac Cardiovasc Surg 2009;137:1293–4; author reply 1294–5.

[22] Gisler F, Huber C, Wenaweser P, Carrel T. Severe calcification of a Shelhigh stentless valved conduit. Eur J Cardiothorac Surg 2014;46:334.