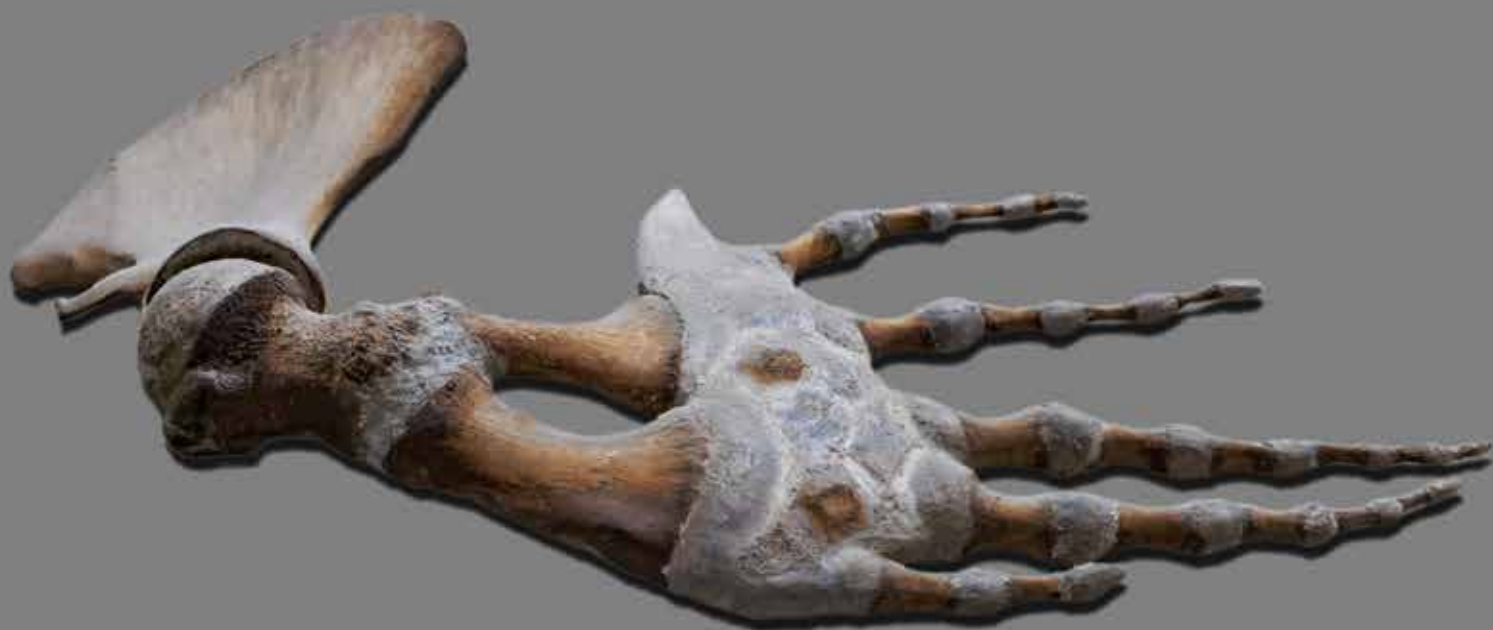

ezine ifssh

CONNECTING OUR GLOBAL HAND SURGERY FAMILY

EXECUTIVE NEWS
MEMBER SOCIETY UPDATES
UPCOMING EVENTS
HAND THERAPY: CMC OA



NATURAL HISTORY *of the* FOREARM

FLEXOR TENDON REPAIR

SKIN COVERAGE:
FINGERTIP RECONSTRUCTION



NEW SUBSCRIBERS: Take 20% off

A quarterly peer-reviewed periodical covering all aspects of wrist surgery and small bone surgery of the hand



Journal of Wrist Surgery

Editor-in-Chief: D. Slutsky

2015/Volume 4/4 issues p.a./ISSN 2163-3916

USA and Canada

Individuals: \$194 \$155

Institutions: \$523

Please contact customerservice@thieme.com

For institutional licenses, please contact esales@thieme.com

Mexico, Central and South America

Individuals: \$212 \$170

Institutions: \$541

Please contact customerservice@thieme.com

For institutional licenses, please contact esales@thieme.com

Europe, Africa, Asia, Australia, New Zealand

Individuals: €150 €120

Institutions: €395

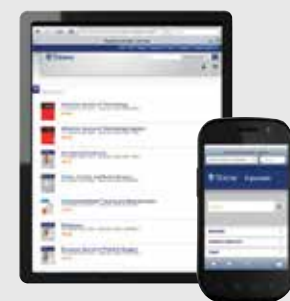(Please add shipping charges: €38.00)

Please contact customerservice@thieme.de

For institutional licenses, please contact eproducts@thieme.de

Bangladesh, Bhutan, India, Nepal, Pakistan, and Sri Lanka

For subscription rates in INR, please contact customerservice@thieme.in



SUBSCRIBE NOW AND STAY UP-TO-DATE IN 2015

Visit www.thieme.com/journals in order to subscribe or renew your subscription.

Take full advantage of your individual subscription by registering online at www.thieme-connect.com/products:

- Individual subscribers get **free online access to current and back issues** of their journal(s)
- Advanced online access for select journals via the **eFirst service**
- **Up-to-date Alerts** via email or RSS-Feed
- Advanced search across our entire library of journals

ORDER TODAY



<http://www.thieme.com>

Special introductory rates are only valid for new subscribers and are limited to the first year of subscription. Only qualified professionals and students are eligible for individual subscriptions. Orders from individuals must include the recipient's name and private address, and be paid by private funds.



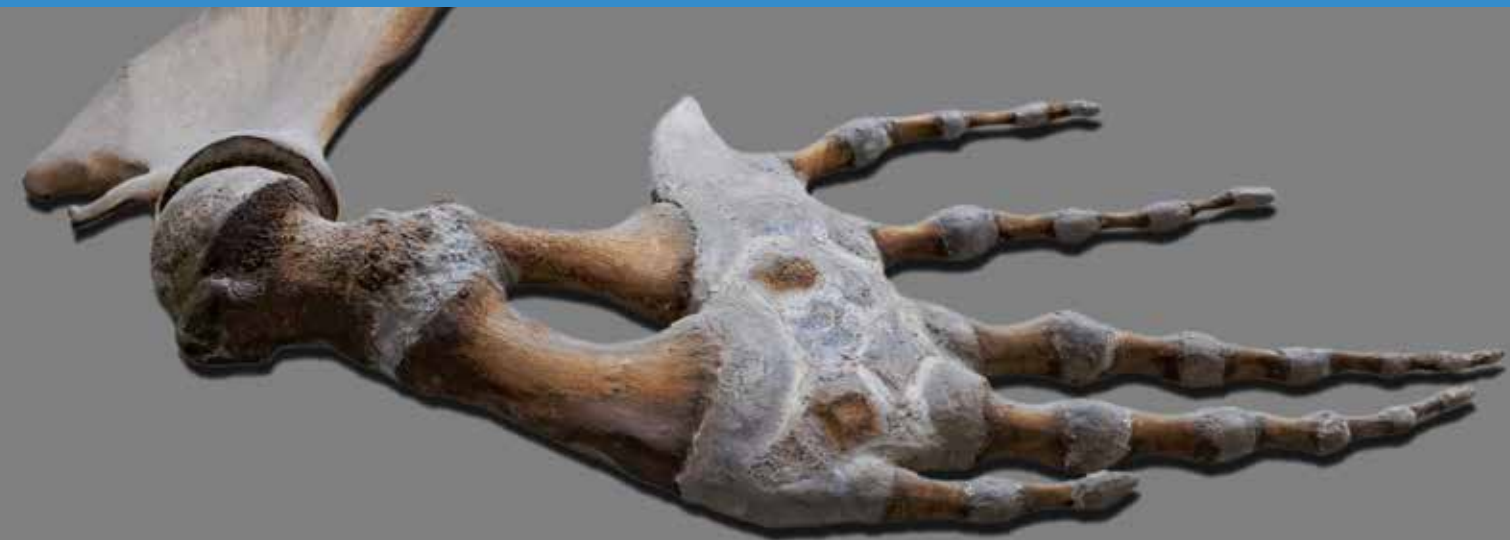Become a fan at www.facebook.com/thiemepublishers.



Follow us @ThiemeNY



Thieme



contents

4 EDITORIAL

A sense of perspective

Michael Tonkin, IFSSH Deputy Editor

6 PIONEER PROFILES

- George E. Omer
- Ezio Morelli

8 SECRETARY-GENERAL REPORT

IFSSH – Secretary General Report

10 SPECIAL FEATURE

The Natural History of the Forearm

20 PEARLS OF WISDOM

My approach to any clinical problem

21 IFSSH SCIENTIFIC COMMITTEE

- Flexor Tendon Repair
- Skin Coverage

51 HAND THERAPY

An evidence-based approach to conservative management of CMC OA

56 MEMBER SOCIETY UPDATES

- The Egyptian Society for Surgery of the Hand and Microsurgery (ESSHM)
- The Finnish Society for Surgery of the Hand
- French Society for Surgery of the Hand (SFCM)
- German Society for Surgery of the Hand (DGH)
- Indian Society for Surgery of the Hand
- Report from Hand and Wrist Biomechanics International (HWBI)

63 JOURNAL HIGHLIGHTS

- The Journal of Hand Surgery (American)
- Journal of Hand Surgery (Asian-Pacific Vol)
- Journal of Hand Therapy
- Journal of Hand Surgery (European volume)

69 UPCOMING EVENTS

List of global learning events and conferences for Hand Surgeons and Therapists

A sense of perspective

During consultation with a patient recently, I was confronted with an elderly, infirm man who had designed a small plastic splint which he wore on the palmar surface of the proximal phalanx of the right ring finger as management for triggering. The tensile recoil strength within the low profile splint maintained the proximal interphalangeal joint in about 20 degrees of flexion and, following active flexion, returned the finger passively to this position. I asked whether the wearing of this splint interfered with his function. The response was no. I then asked whether he would wish either an injection or an operation for the condition which, in his words, was causing no loss of function, nor pain for that matter. Receiving a response in the negative, I then asked why he had attended my clinic. He responded "well, it's my wife you see". I replied that "an operation might not help that problem". We agreed upon an injection in an attempt to satisfy all, including the patient's wife for whom I had previously performed a successful injection for treatment of her trigger finger. One hour after leaving, I

received a call from the patient's wife explain the directions I had given the patient regarding use of his splint and the exercises that I had recommended.

I suspect that this may not be the last I see of this patient but the light hearted encounter did lead me to reflect upon the indications we surgeons use to choose treatment options. Often in my congenital hand clinic I am confronted with clinical presentations which remind me of something I have never seen before. In these cases I find it helpful to consider a number of questions: 1) is the part too large or are there too many (digits); 2) is the part too small or are there too few (digits); 3) is there deviation (deformity) in any plane; 4) are joints unstable or immobile? The answers to these questions lead to a logical surgical approach, that being the removal of extra tissue or parts; the addition of tissue or parts; correction of deformity (perhaps multi-planar); stabilisation of unstable joints and an attempt to improve motion. Of course, the last of these is the most difficult, except perhaps in the case of a locked trigger digit.

“We should be grateful for our good fortune and should remember to apply a sense of perspective to all aspects of our lives.”

However, before deciding on whether any form of treatment, including surgery, is indicated, perhaps the appropriate question to ask is whether a treatment is being offered because the physician sees something wrong or whether the treatment offered will improve the circumstances of the patient with minimal risk of complications. This is particularly so for difficult congenital presentations.

My elderly, infirm patient with the trigger digit, suffering

no functional loss with the use of his home made splint, and no pain, did not need my intervention, at least not for physical reasons.

A sense of perspective is helpful, even when considering the most minor of clinical problems. A sense of perspective becomes more necessary when confronted with major tragedies, one's own or those of others. At these times, a focus on the importance of our own medical lives may seem misplaced. One such recent tragedy was the lamentable loss of our colleague Philippe Saffar, from France. Another is the loss of Toshihiko Ogino from Japan. Their wives, Michele and Tomoko respectively, and their families have lost a major part of their lives and our hearts go out to them. We have lost the most admirable of colleagues.

We are fortunate that, in a relatively small medical community, we are able to meet and interact with so many different people from different places, through congresses, medical writing, travel, and electronic communications. We are blessed with opportunities unavailable to most. We should

be grateful for our good fortune and should remember to apply a sense of perspective to all aspects of our lives.



Michael Tonkin
President : IFSSH
Deputy Editor:
IFSSHazine

ezone
ifssh
CONNECTING OUR GLOBAL HAND SURGERY FAMILY

IFSSH DISCLAIMER:

The IFSSH ezine is the official mouthpiece of the International Federation of Societies for Surgery of the Hand. The IFSSH does not endorse the commercial advertising in this publication, nor the content or views of the contributors to the publication.

Subscription to the IFSSH ezine is free of charge and the ezine is distributed on a quarterly basis.

Should you be interested to advertise in this publication, please contact the Editor:
ezine@ifssh.info

IFSSH EZINE EDITORIAL TEAM:

EDITOR:

Professor Ulrich Mennen
(Immediate Past President of the IFSSH)

DEPUTY EDITOR:

Professor Michael Tonkin
(President of the IFSSH)

GRAPHIC DESIGNER:

Tamrin Hansen

TO SUBSCRIBE GO TO:

www.ifssh.info/ezine.html

GEORGE E. OMER

Jr., MD, FACS, Col. USA (Ret) (1922-2014)



Dr. Omer graduated in medicine from the University of Kansas, and completed a residency at Brooke Army Medical Center while earning a master of science in orthopaedic surgery from Baylor University. After preceptor periods with Adrian E. Flatt and Daniel C. Riordan, Colonel Omer organized the first designated Section of Hand Surgery in the U.S. Armed Forces after World War II in 1962. He was the first career officer of the U.S. Armed Forces to be elected a member of the American Society for Surgery of the Hand. Colonel Omer remained on active duty from 1950 to 1970 and served as military consultant in hand surgery and orthopaedic surgery to the Surgeon General of the U.S. Army.

Dr. Omer is recognized for his series of unique contributions that initiated certification of hand surgery in the United States. The Certificate of Added Qualifications in Surgery of the Hand was formally initiated while Dr. Omer was President of the American Society for Surgery of the Hand (1978-79); subsequently, the Certificate was

recognized while Dr. Omer was Chairman of the Joint Committee for Surgery of the Hand (1984-92), representing the American Boards of Orthopaedic Surgery, Plastic Surgery, and Surgery. The first national examination for certification was held in 1989 when Dr. Omer was the Immediate Past-President of the American Board of Orthopaedic Surgery. In recognition of this accomplishment, Dr. Omer was awarded a special plaque in 1989 by the American Society for Surgery of the Hand.

Dr. Omer served as Professor and Chairman of the Department of Orthopaedics and Rehabilitation at the University of New Mexico Medical Center from 1970 to 1990. Dr. Omer established the first formal academic Division of Hand Surgery in North America in 1970, with an active fellowship program since 1972. His leadership in American orthopaedics was recognized by the Presidency of the Western Orthopaedic Association, 1981-82, and the Presidency of the American Orthopaedic Association, 1988-89. Dr. Omer was President of The Sunderland Society in 1981-82.

Dr. Omer has presented more than 950 papers at 465 meetings in 25 countries, emphasizing the management of peripheral nerve problems. He has published more than 130 peer-reviewed papers, two books, and 60 chapters. Dr. Omer is a honorary member of seven hand surgery societies. Dr. Omer served as Executive Director of the American Orthopaedic Association, 1990-93.

George E. Omer was honoured as "Pioneer of Hand Surgery" by the IFSSH at its sixth Congress in Helsinki, Finland on 3 July 1995.

EZIO MORELLI

MD (1923-2009)



Ezio Morelli was born in Montecastello Vibio, (Perugia) Italy on July 2, 1923. He graduated in Medicine and Surgery in July, 1948. In 1951, he did post-graduate training at the University of Munich School of Medicine under Professor Max Lange. In 1952 and 1956 he studied at the Unfallskrankenhaus in Vienna under the supervision of Professor Böhler.

Dr Morelli specialized in Orthopaedic Surgery and Traumatology in 1951, in Occupational Medicine in 1954, and in Plastic Surgery in 1961 and qualified for university teaching in Orthopaedics in 1962 and Plastic Surgery in 1967.

Professor Morelli headed the Division of Plastic Surgery and Hand Surgery of Legnano Hospital from 1964 to 1988.

Since 1948, Professor Morelli has worked predominantly in the field of hand surgery, vascular microsurgery and peripheral nerve surgery and later as a surgeon at the S. Ambrogio Private Hospital in Milan. His micro-surgical contributions became internationally known, and because of putting the city of Legnanesi on the world map, the 'Piazza Ezio Morelli' was named after him.

Professor Morelli has published 140 papers and has collaborated with many Italian and overseas universities in holding conferences and updating courses. Professor Morelli was Past-President of the Italian Society of the Hand. He was awarded the Gold Medal of the Public Health for his outstanding work by the Minister of Health.

His humanity and classic culture have earned him the esteem and friendship of many hand surgeons at home and abroad.

In 1995 he was honoured as "Pioneer of Hand Surgery" by the International Federation at its sixth Congress in Helsinki, Finland.

IFSSH - SECRETARY GENERAL REPORT

2015 IFSSH DELEGATES' COUNCIL MEETING

The annual IFSSH Delegates' Council Meeting was held in Seattle on September 10th, in conjunction with the annual meeting of the American Society for Surgery of the Hand. 32 of the 55 member societies were represented at the meeting and we thank these delegates for their contribution.

At this meeting, the Delegates unanimously adopted the newly modified bylaws of the IFSSH, as well as the proposition by the Executive Committee of registering our organization as an international non-for-profit organization based in the State of Illinois, USA. The IFSSH Charter had been initially registered in 1990 in Puerto Rico by the late Dr Miguel Vargas. The need for reconsidering the location of that registration had been raised in previous Delegates' Council meetings to optimize our legal and financial status.

The Delegates' Council accepted the membership application of the Kuwait Society for Surgery of the Hand. We welcome this society into the



Federation and look forward to inviting its delegate and members to participate in future activities.

Eduardo Zancolli reported on the progress of the IFSSH triennial congress, to be held in Buenos Aires, October 24th-28th 2016. The scientific and social programmes have been prepared and promise a stimulating and exciting congress. Registration opens on November 1st 2015. Detailed information is available on the new congress website -

<http://www.ifssh-ifsht2016.com/>

The 2016 congress will coincide with the 50th anniversary of the foundation of the IFSSH. We hope all members of the IFSSH societies will join us to celebrate this milestone.

IFSSH - SOUTH ASIAN REGIONAL COURSE IN HAND SURGERY

The IFSSH recently provided a US\$20,000 grant to assist with the conduct of a regional hand surgery course in South Asia. The following report was submitted by Dr. S. Raja Sabapathy, the Course Chairman:

The IFSSH sponsored South Asian Regional Live Hand Surgery Workshop was held at Ganga Hospital auditorium, Coimbatore, India, from 3rd to 5th July, 2015. It had prominent overseas faculty including the IFSSH President Dr. Michael Tonkin. Dr. Don Lalonde from Canada, Dr. Goo-Hyun Baek from South Korea, Dr. P.C. Ho from Hong Kong and Dr. Amit Gupta from USA were the overseas faculty and they were joined by the Ganga Hospital team of doctors.

293 delegates participated in the course and of them 37 were from overseas belonging to 18 nations. The conference was held in the comfortable Ganga Hospital auditorium. 24 live surgeries were demonstrated. It covered a wide range of procedures like cleft hand, syndactyly, brachial plexus nerve transfers, wrist arthroscopy, wide awake surgical demonstrations, tendon repair, tendon transfers and carpal injuries. At any one time two surgical procedures were demonstrated with the moderators helping the delegates to interact with the Surgeons. The

demonstrations were so intensive that the hall was full till the very end. Every session started with 2 didactic presentations from the faculty and a total of 10 lectures were delivered.

It also had good social programmes. We had Banquet Dinners on the evening of 3rd and 4th July. On the evening of 4th July, Dr. P.C. Ho with his Harmonica and Dr. Amit Gupta with the Indian Drums (Tabala) entertained the people with the fusion of western and Indian music which provided an opportunity for the delegates to interact with the faculty.

The feedback that we got from the delegates were very complimentary both to the content of the course and the organization. Together it was a very rewarding experience to the delegates.

Hand and Wrist Biomechanics International (HWBI) Awards

We are pleased to report that the HWBI, an allied organization of IFSSH, in their 9th symposium held in Milano, Italy, on June 16th-17th 2015, awarded four scholarships to encourage four investigators pursue research in hand and wrist biomechanics. The scholarships were generously sponsored by the ISB, HWBI, and William H. Seitz, MD Research Fund. The award committee selected this year's winners based on the abstract submissions to that symposium. The award winners

were Joseph N. Gabra (USA), Benjamin Goislard de Monsabert (France), Faes D. Kerkhof (Belgium), and Giovanni F. Solitro (USA). For more information about the HWBI and its events, please visit the website at www.hwbi.org.

FUTURE MEETINGS

A detailed list of national and regional hand surgery meetings is available on the IFSSH website.

The triennial IFSSH Congresses are as follows:

XIIIth IFSSH – Xth IFSHT Congress – Buenos Aires, Argentina
October 24-28, 2016
www.ifssh-ifsht2016.com

XIVth IFSSH – XIth IFSHT Congress – Berlin, Germany
May, 2019

Marc Garcia-Elias

Secretary-General, IFSSH

Email: secretary@ifssh.info



THE NATURAL history of the FOREARM

OLIVIER DELAERE M.D. (BELGUIM)

ABSTRACT

The natural history of the forearm started in water within the fins of some devonian fishes. Some 385 million years later, through amazing adaptations, the forearm bones allowed the tetrapods world to colonize every other kind of biotopes on Earth.

Initially devoted to locomotion in amphibians, birds and reptiles, the forearm develops more ambitiously in the mammalian lineage.

Adopting first an upright limb posture and bipedalism thereafter, the Hominidae forelimb acquires an extreme range of pro-supination

and can be dedicated to other tasks, including tool making and handling. By developing unconstrained joints at the elbow and wrist level, as well as more and more specialized soft tissues like the triangular fibrocartilage complex, the human forearm reaches the most sophisticated compromise between strength, mobility and stability and becomes the hand's greatest ally.

Chapter 1: AT THE ORIGINS...

The natural history of the forearm on planet Earth is a nearly 400 million years long journey. Indeed, the earliest witnesses of a forearm

skeleton are some fossil fishes of the Devonian. Fortunately, some of them like *Eusthenopteron foordi* remain perfectly preserved and the anatomy of their pectoral fin clearly shows the presence of a radius, an ulna and a humerus (fig.1). In fact, *Eusthenopteron foordi* is not a real fish anymore; it has internal nostrils, different teeth and most probably lungs, but the general shape of its body still reflects a fully aquatic lifestyle (Jarvik, 1980).

10 million years later, signs of an amphibian way of life are more obvious. *Tiktaalik roseae* (fig.1) can be considered as a true transitional

species; it still has scales and fins, but now it has a neck, a flat head and eyes on top of it, able to see what happens above water... According to Neil Shubin, *Tiktaalik roseae* was able to pull itself onto the shore for brief periods, thanks to a strong pectoral girdle and a primitive wrist, able to bend the distal fin to lie flat on the ground like seals, for example (Shubin et al., 2006).

It is surprising to see that the first real tetrapods, with hands and feet instead of fins were still aquatic creatures like *Acanthostega Gunnari* (fig.1). These odd hands, with 8 webbed fingers suggest that this early tetrapod was mainly using its arms, forearms and hands like paddles and probably nothing more (Coates and Clack, 1990; Long and Gordon, 2004).

The so-called "Romer's gap" is a 30 million year period between the end of the Devonian and the beginning of the Carboniferous periods. During this time, primitive tetrapods invaded land and their limbs replaced the tail as the main organ of propulsion (Hutson, 2010). Until recently, this gap was characterized by a lack of fossil records. Fortunately, it was partly filled by the recent description of other primitive tetrapods like *Pederpes finneyae* or *Casineria kiddi*, both species showing one peculiar feature; the feet (*Pederpes*) and hands (*Casineria*) are now pentadactyl (Long and Gordon, 2004; Paton et al., 1999; Smithson et al., 2012) (fig.1).

At that stage, the forelimb "bauplan" of land tetrapods is almost entirely drawn, even if it is not rigidly fixed (Hinchliffe, 2002). The common architecture of the carpus, made of several bones articulating on each faces with one another will be defined in more recent fossils with well-ossified wrists like *Seymouria*, a reptilomorph amphibian of the Permian (Carroll and Holmes, 2007) (fig.1).

To crawl out of the water onto land and to lose the advantages of Archimedes law required major anatomical changes. Adaptation to terrestrial locomotion needed very powerful pectoral girdle and forelimbs (Long and Gordon, 2004). To fight gravity, a new process raised at the proximal end of the ulna, increasing the strength of the extensor muscles; the olecranon (Liem et al., 2001-1). The limb bones became longer and more slender (Liem et al., 2001-1). But most important was the ability to redirect hands in the frontal plane: this was one of the first challenges of the forearm bones.

Pro-supination or rotation of the forearm is an older ability than one might think: it probably started in sarcopterygian fishes, but it was quite restricted, even in early aquatic tetrapods (Pierce et al., 2012). Land invasion will require a bigger range of motion...

Chapter 2: THE SPRAWLING FOREARM

To understand the anatomy of a

sprawling forearm, and how the reptile ulna and radius are able to pronate, one has simply to observe the forelimb of a contemporary species: the Varanidae.

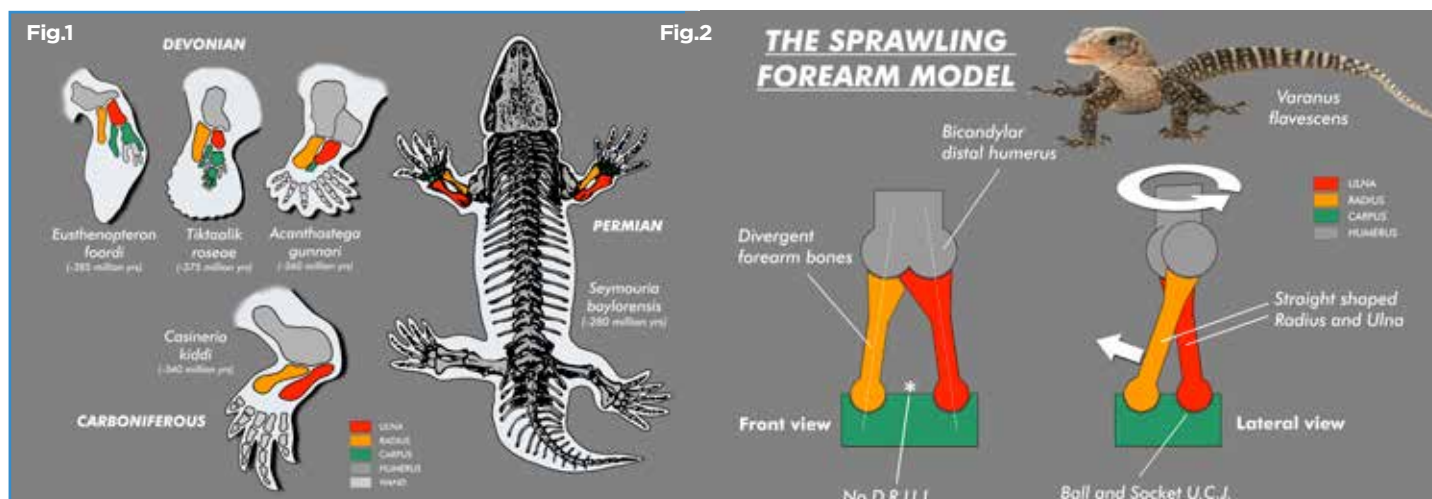
The schematic model in Fig. 2 shows the main features of a typical reptile forearm.

Ulna and radius are straight, divergent and there is no distal radioulnar joint. The ulnocarpal joint is of ball and socket type and the main feature is that whatever the rotation of the forearm, the ulna and radius never cross each other (Haines, 1946). Like all the sprawling vertebrates, the varanus elbow is a bicondylar joint. There is no interosseous membrane (Haines, 1946; Landsmeer, 1983).

Upon close inspection, the radial head has an oblong shape, restricting axial rotation of the radius (Fig.3).

In fact, the main and original way for reptiles to rotate their forearm is to flex and extend the radius independently from the ulna (Hutson, 2010; Landsmeer, 1983) (Fig.3).

At the elbow level, the radial condyle of the humerus extends further proximally, allowing a wider range of flexion of the radius compared with the ulna (Fig.3). Moreover, the radius flexion axis is orientated towards the ulna, both features helping the hand to keep a semi-prone position, whatever the locomotion phase (Hutson, 2010) (Fig.3). To stabilize the elbow, the proximal ulna is made of two condylar facets, separated by a

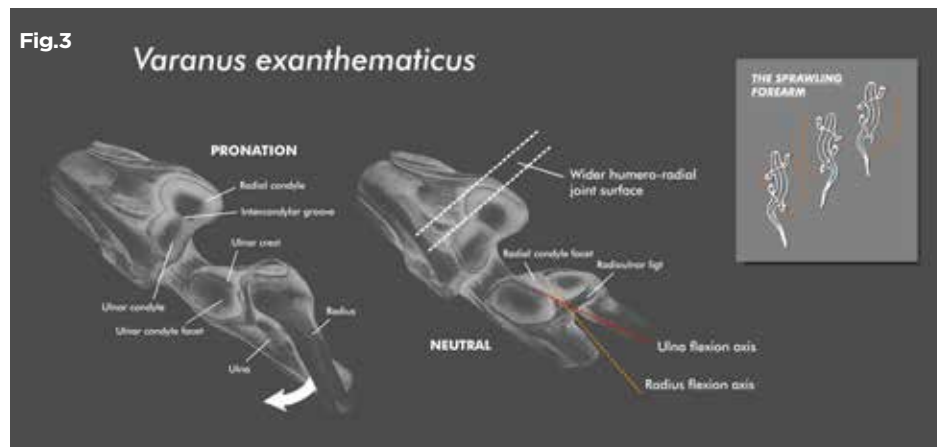


marked crest and articulating not only with the ulnar condyle but also with the ulnar side of the radial condyle of the humerus (Hutson, 2010; Landsmeer, 1983) (Fig.2&3).

At the wrist level, contrary to the simplified drawing in Fig. 2, only the ulno-carpal joint is really of ball and socket type and can be considered as the pivot point of the wrist. The radio-carpal joint anatomy does not allow significant rotation (Landsmeer, 1983).

Interestingly, even if some of these anatomical features are very distinctive of the sprawling species, the functional plan of the tetrapods forelimb seems to share a common principle: it is made of two functional units. The first one is the humero-ulnar segment, allowing a stable and "hinge-like" elbow joint. The second one is the radius-carpus-hand segment, allowing a stable wrist and articulating with the humero-ulnar unit with a kind and range of motion depending on species (Hutson, 2010).

Chapter 3: A FLYING FOREARM



INHERITED FROM DINOSAURS

Soon after land colonization, stem amniotes will split into different lineages and try to adapt themselves to other kinds of biotopes on Earth. In the history of reptiles, some in the dinosaur group will abandon the sprawling gait to more efficient ways of locomotion. Eoraptor for example, one of the world's earliest dinosaurs, is already bipedal. Oddly enough, from the mid-Jurassic, within a family of these running lizards, the aptly named Dromaeosauridae, something strange will happen within the forelimb. At the hand level, two fingers disappear. At the wrist level, the radiale bone or

"scaphoid" becomes wedge-shaped and the midcarpal joint becomes a trochlea (Sullivan et al. 2010). These anatomic features lead to a progressive ulnar shift of the hand. The forearm itself loses its ability to rotate. The radius migrates proximally to lie side by side with the ulna along the elbow flexion plane. In some specimens like Microraptor Gui, limbs and tail are covered with feathers (Sullivan et al. 2010) (Fig. 4). As these strong indicators tend to suggest, we are touching here on the origins of... birds!

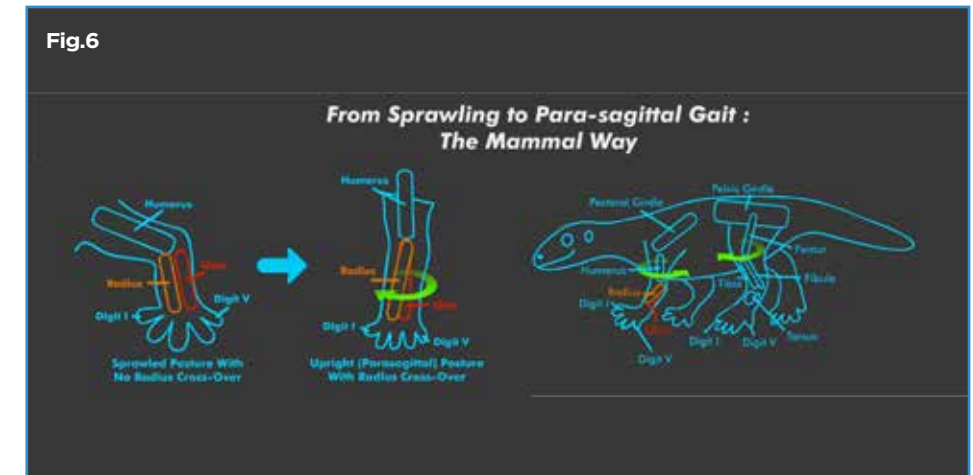
Within a flying forearm, ulna and radius need to be stable and to link elbow and wrist flexion

during upstroke, and extension during downstroke. This critical synchronization is ensured by the "drawing parallels" mechanism, even if the role of extensor metacarpi and flexor carpi ulnaris muscles, through a tenodesis effect, is considered even more important ((Liem et al., 2001-1; Vasquez, 1994) (Fig. 5).

Unlike the maniraptoran dinosaurs, the bird wings include an additional bone between the ulna and carpometacarpus, named "cuneiform" (Fig. 5). By preventing the manus from hyperpronating during downstroke and by rotating the manus towards the body during upstroke, the cuneiform probably offers a crucial advantage to master the airs (Vasquez, 1992).

Chapter 4: REACHING AN UPRIGHT LIMB POSTURE

By placing hands and feet closer to the center of gravity, straight limbs under the body provide some biomechanical advantages compared to the sprawling posture. This implies some fundamental changes, including shifting humerus and femur from a horizontal to a vertical position, and pointing elbow backward and knee forward (Humphry, 1876; Radinsky, 1987) (Fig. 6). But if internal rotation of the hindlimb is of no consequence for the foot, external rotation of the forelimb tends to put the hand in supine position, which is unsuitable for locomotion. On the other hand, the sprawling forearm model, with a straight radius only



able to sway forward and backwards does not allow a reorientation of the hand of such magnitude.

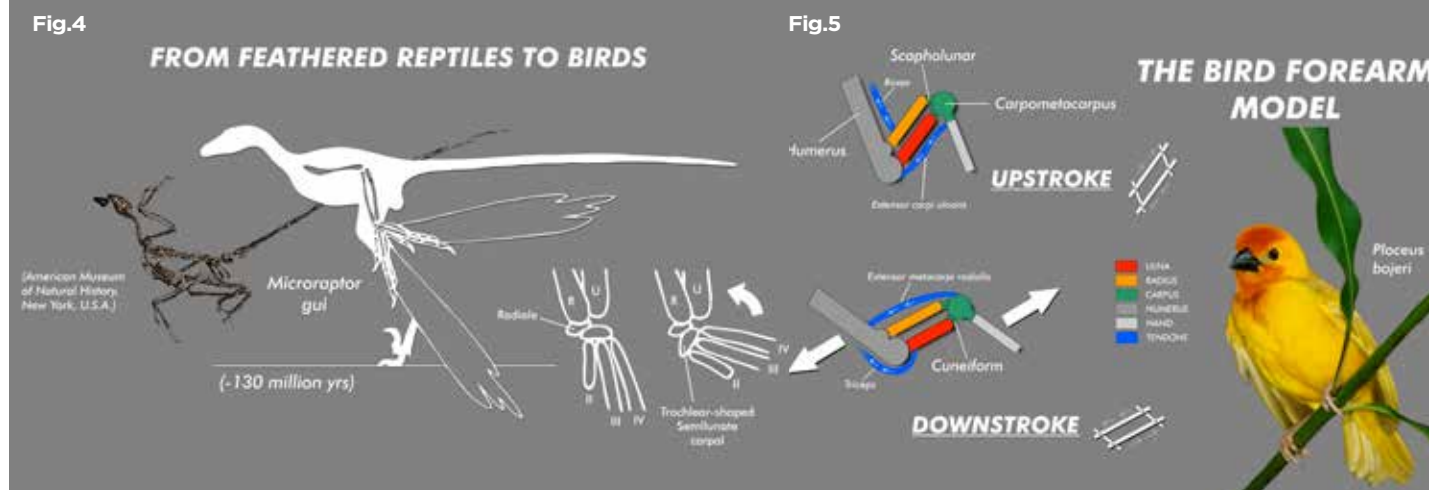
The most efficient solution to that issue will be provided by the therian mammal lineage. In therian mammals, the radius curves and crosses over the ulna: from the elbow to the wrist, it moves from a lateral to a medial position. By this half-turn, the radius is now able to put the wrist and hand in full pronation (Humphry, 1876) (Fig. 6&7); an almost exclusive capacity in the whole world of tetrapods, only shared by the funambulists chameleons (Hutson, 2010).

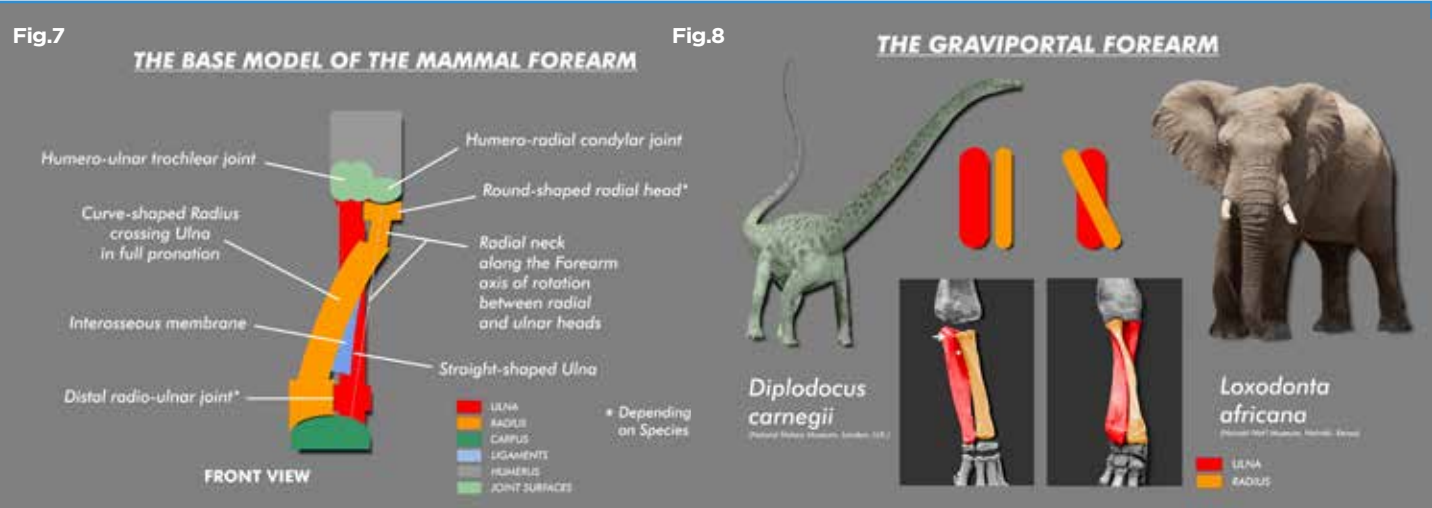
Moreover, by developing proximal and distal radio-ulnar joints of trochoid type, some mammal species will be able to make this half-turn back.

The main anatomical features of a therian mammal forearm are summarized in Fig. 7; a straight ulna, a curved radius, a rotational axis from radial head to ulnar head, a radial neck just along this axis, a longer forearm than reptiles and bones crossed in pronation, an interosseous membrane, the

presence of a capitellum and trochlea instead of a bicondylar elbow, and finally more or less developed proximal and distal radioulnar joints (Haines, 1946).

By the late Triassic, parasagittal gait and erect posture of the forelimb were also adopted by non-mammalian quadrupeds on Earth. Amongst the Dinosaurs, the Sauropods suborder remains a prime example. But the way they reoriented their hands is less ambitious; at the forearm level, the whole radius shifts from an antero-lateral to an antero-medial position in relation to the ulna (Bonnan, 2003) (Fig. 8). Proximally, the radial epiphysis is of triangular shape and articulates inside a deep triangular fossa on the anterior face of the ulna (Fig. 8). The proximal ulna develops an anterolateral process, most probably to support the mechanical stresses on the lateral part of the elbow (Bonnan, 2003) (Fig. 8). As a general rule for non-mammal tetrapods, this forearm shifting process is unable to achieve a full pronation of the hand (Hutson, 2010). Moreover, such a model does



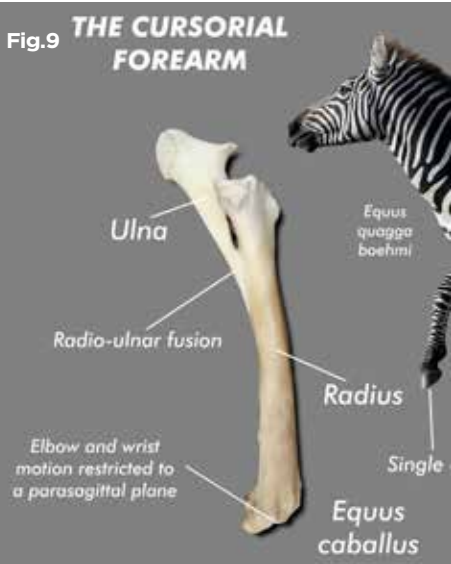

not allow any kind of rotation within the sauropods forearm.

Finally, despite appearances between Sauropods and graviportal mammals like elephants, the anatomy of their forearm has nothing in common but hypertrophied ulna and radius (Polly, 2007) (Fig. 8).

Chapter 5: THE VERSATILITY OF THE MAMMAL FOREARM

Provided with decisive anatomical improvements, including homeothermy, high metabolic rate, hair, diaphragm, four-chambered heart, three middle ear bones or



neocortex, mammals will be able to occupy an extraordinary variety of substrates on Earth (Polly, 2007; Radinsky, 1987).

Consequently, the mammalian forearm will adapt itself to a multitude of biological roles, and not only postural, but also feeding, exploratory, grooming or defense related behaviors (Salton and Sargis, 2008).

For obvious biomechanical reasons, fossorial (digging) species are distinguished by a long olecranon and short ulna and radius, cursorial (running) species by the converse (Liem et al. 2001-2; Polly, 2007; Salton and Sargis, 2008).


Interestingly, the more specific task the forelimb has to perform, the more its anatomy moves away from its original design.

In highly cursorial mammals like horses, the hand is reduced to a single digit, as well as the forearm, which is mainly reduced to the radius. And this is not only to optimize speed, but also the cost of energy while running (Liem et al., 2001-2) (Fig. 9).

An ulna mainly reduced to an olecranon process and its distal part fused to the radius is also typical of the only flying mammal species: bats (Gatesy and Middleton, 2007). Like birds, the bat's forearm is unable to rotate. Elbow and wrist joints move in the same plane.

But if birds flap an entirely rigid forelimb with a vestigial hand, bats flap a highly elastic wing made of 4 long and mobile metacarpals and fingers (fig. 10), making them the most efficient flyers on Earth (Swartz et al., 2012). Moreover, unique feature among mammals, the bat's forearm and hand bones have a low mineralization rate and become nearly cartilaginous at the distal wing to promote flexibility and lightness (Swartz et al., 2012).

In obligatory aquatic mammals like cetaceans, the forelimb is also remarkably modified. Like some reptiles which reverted back to aquaticism in the early Jurassic period (Fig. 11), humerus, radius and ulna shorten and lose their morphological differentiation. The hand develops hyperphalangism.



Elbow and wrist joints become stiff, the shoulder remaining the only synovial joint; the forelimb reverts to semi-pronation (Hutson, 2010) and is reduced to a steering tool (Liem et al., 2001-1; Thewissen and Taylor, 2007) (Fig. 12).

Chapter 6: RUNNING AND CLIMBING CATS

The felidae family brings another interesting example of forearm adaptation and an enlightening exercise of compared anatomy.

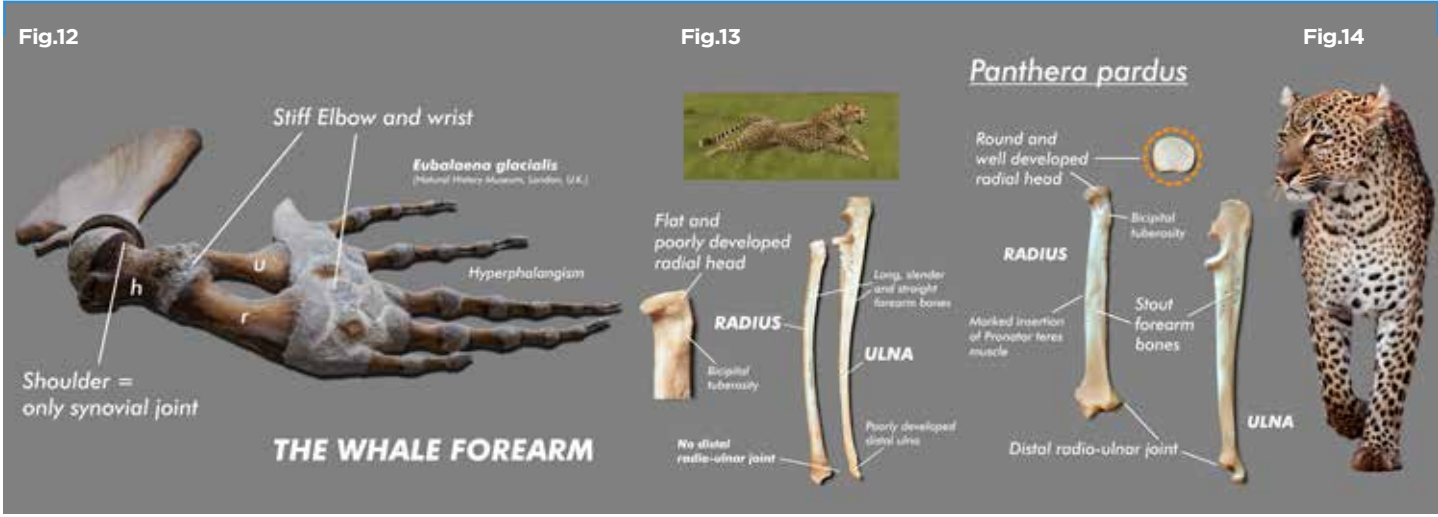
At first glance leopards and cheetahs looks quite similar. Yet, the peculiar shape of their forearm

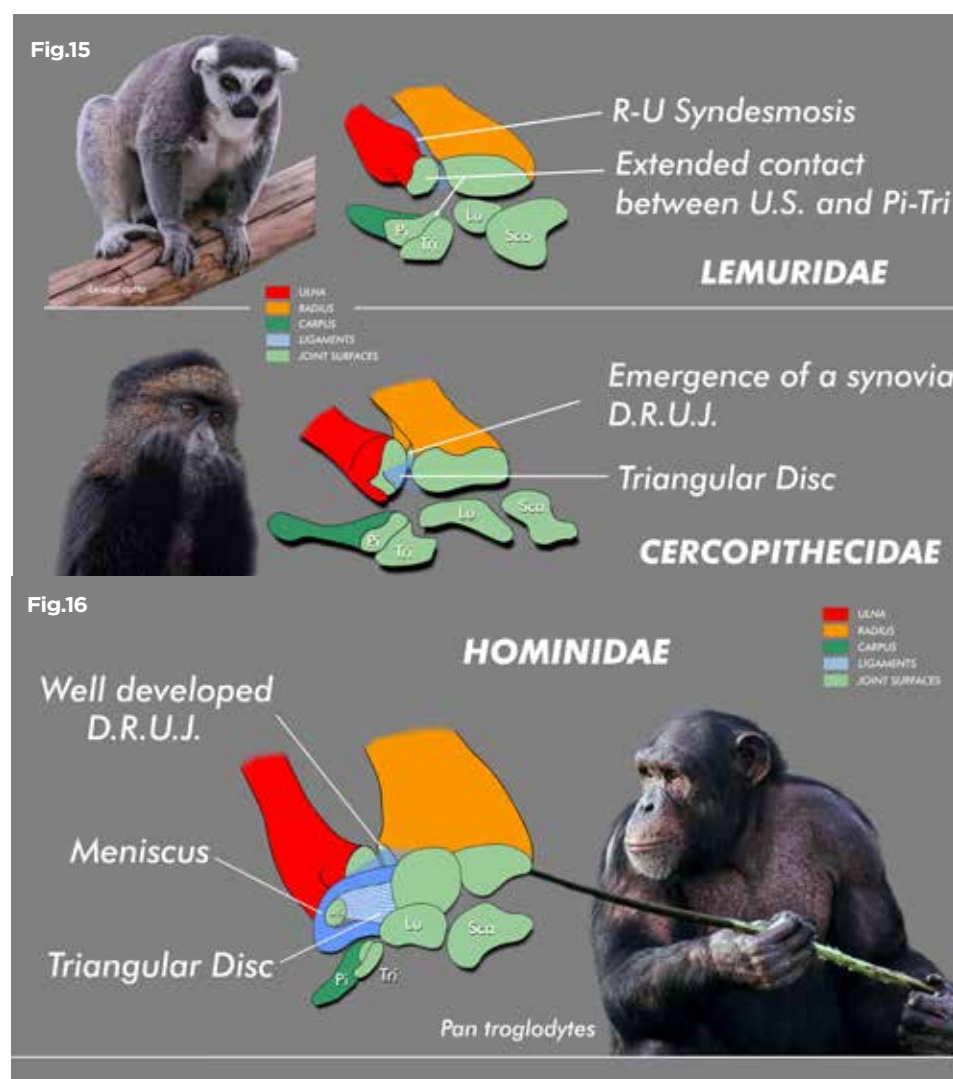
make them completely different cats.

The main peculiarities of the cheetah's forearm bones are highlighted in fig. 13. Ulna and radius are long and slender, typical features of a running species (Polly, 2007). The coronoid process is well developed, but this is common to all the mammals in upright position; the biomechanical advantage of that is obvious. The radial head is flat and poorly differentiated, as well as the distal ulna. At the wrist level, the distal radioulnar joint is made of a strong syndesmosis, locking the forearm in prone position (Hopwood, 1947). Moreover, a bony ridge at the

radio-palmar aspect of the distal radial epiphysis restricts radiocarpal joint flexion and lateral deviation (Ohale and Groenewald, 2003).

Compared with the cheetah, the leopard's forearm bones are shorter but stronger (Fig. 14). The radius is more curved. The radial head is round and well developed. The ulnar head includes an articular surface with the distal radius: the leopard radius is able to rotate and it is doing it up to 90° around the ulna. Bone insertions of the forearm muscles are distinctly marked on the ulna and radius, signs of greater strength, especially from pronator teres (Fig. 14) and supinator brevis





muscles (Hopwood, 1947). The radial tuberosity, in volar position in the cheetah, migrates to the ulnar side of the radius in the leopard (Hopwood, 1947) (Fig. 13 & 14); biceps brachii muscle is mainly an elbow flexor in the former but also a strong supinator in the latter.

These anatomical variations have a huge impact on forearm function. Cheetahs are built to run, and to run very fast. Reaching an outstanding speed of 70 mph, they really need their forelimb to be stable and locked in full pronation. Therefore, their long, light, thin and stiff forearm is a perfectly adapted tool... but only when chasing a quick

and mid-sized prey in open plains.

Conversely, by their ability to rotate their paws and claws a quarter turn to half-supination, leopards benefit from an invaluable advantage; they climb more skillfully than any other big cat, which makes their hunting grounds extremely diversified. Moreover, the leopard's forearm is strong enough to carry heavy preys on top of trees in places inaccessible to other predators (Fig. 14).

Chapter 7: BEYOND THE LIMITS OF LOCOMOTION

Within the climbing or "scansorial" species, one lineage will push the

forearm development even further; the primates.

The Lemuridae family is the most primitive of them. Their forearm has more in common with cheetahs than with leopards. There is no distal radio-ulnar joint and the distal forearm is stabilized by a strong syndesmosis (Lewis, 1965; Russel and Stern, 1998) (Fig. 15).

More evolved species like the Cercopithecidae start to develop not only a distal radioulnar joint like leopards but also a triangular disc, allowing the forearm to rotate up to 90° (Lewis, 1965; Russel and Stern, 1998) (Fig. 15).

Hominidae like gorillas or chimpanzees evolve towards a proximal retreat of the distal ulna and the interposition of a meniscus and a triangular disk between the ulnar head and the triquetrum and pisiform (Lewis, 1965) (Fig. 16). Thanks to that, big apes are now able to exceed 160° of pro-supination (Almquist, 1992; Russel and Stern, 1998).

A wide range of forearm rotation provides hominidae with new skills and abilities, like taking care of their young, gathering food or tool making and handling (Almquist, 1992). The latter faculty, long seen as exclusive to humans, also serves the interests of other primates; chimpanzees for example are known to use tiny twigs to fish for termites and even wooden spears to catch small monkeys (Pruetz et al., 2015).

Big apes and humans share not only an outstanding amount of similar behaviors. The genomes

of chimpanzees and humans are so close that some scientists tend to bring them together into the same genus (Wildman et al., 2003). Nevertheless, they do differ in one important way; the human clade, the so-called "hominins" shifted to fully obligate bipedalism, and no doubt this step played a major role in the human forelimb evolution. The lack of locomotor constraints allowed the forearm joints to decrease their stability and increase their mobility (Drapeau, 2008). At the elbow for example, Fig. 17 shows how flat the human trochlea is when compared with brachiating apes like gibbons (Drapeau, 2008). Moreover, the humeroulnar joint is not fully congruous: the mid part of the ulnar trochlear notch is deeper than the humeral trochlear surface (Eckstein et al., 1993) (fig. 17). The central part of the humero-ulnar joint only comes in close contact when heavily loaded (Drapeau, 2008; Eckstein et al., 1993).

The annular ligament is a strong stabilizer of the proximal radio-ulnar joint but still allows some antero-

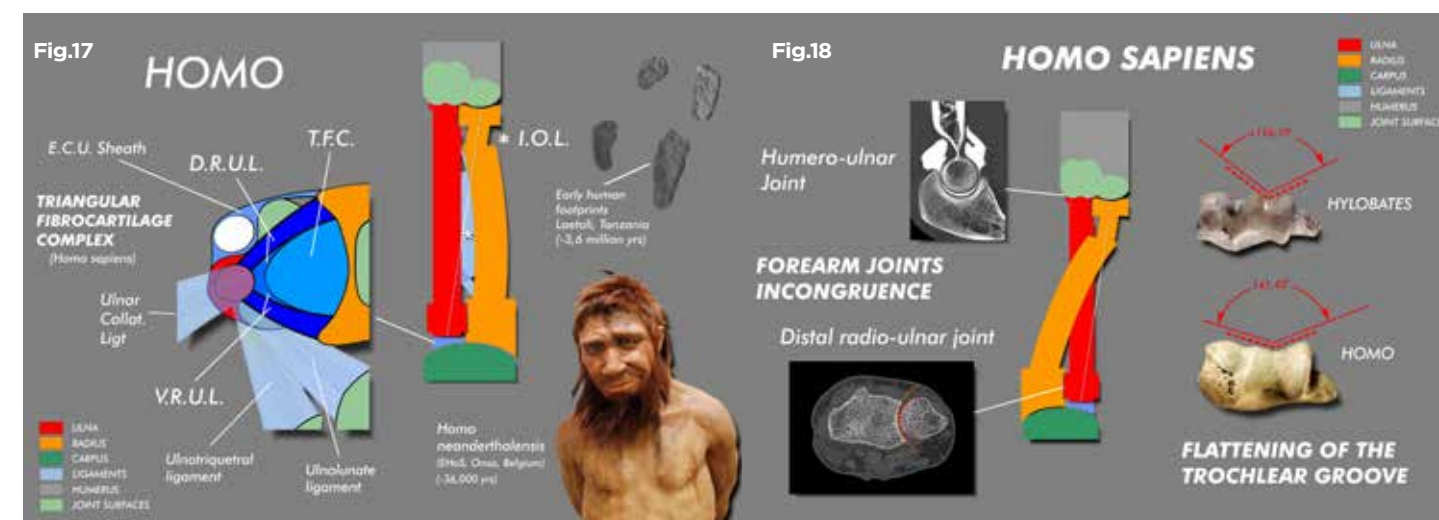
posterior and lateral translation of the radial head during pro-supination (Galik, 2007). The distal radioulnar joint is also notoriously non congruent. The radius of the sigmoid notch is markedly bigger than the one of the ulnar head (Lees, 2009) (fig. 17). Unconstrained joints at the elbow and wrist level allow humerus, radius and ulna a subtle range of motion between each other, in particular lateral shift of the distal ulna and volar shift of the distal radius in full supination or proximal shift of the radius in elbow flexion (Kapandji IA, 1980, Lees, 2009; Quigley et al., 2014); this probably helps the human forearm to further increase its arc of rotation.

The proximal retreat of the ulna, initiated by the big apes, goes one step beyond in humans: the ulnar styloid loses contact with the triquetrum and pisiform (Lewis, 1965), further improving ulnar deviation of the wrist and tool using (Russel and Stern, 1998). The ulno-carpal gap is filled with a more and more specialized structure, the

triangular fibrocartilage complex, to provide both mobility and stability of the ulnar part of the wrist (Lees, 2009; Palmer and Werner, 1981) (fig. 18).

As a result, the distal radius carries now about 80% of compressive load applied to the hand (Pfaeffle et al. 2000). To relieve the humeroradial joint, the interosseous membrane strengthens its central part; the interosseous ligament (fig. 18). As well as ensuring transverse stability of the forearm bones, this ligament also transfers axial stresses from the distal radius to the proximal ulna (Pfaeffle et al. 2000).

Unconstrained joints and highly specialized soft tissues make the human forearm the most sophisticated compromise between strength, mobility and stability. In the meantime, the human hand has evolved into an ultimate tool that the forearm will be able to place in space like never before to interact with its environment (Lees, 2009; Russel and Stern, 1998).



REFERENCES

- Almquist EE. Evolution of the distal radioulnar joint. *Clin Orthop Relat Res.* 1992, 275: 5-13.
- Bonnan MF. The evolution of manus shape in sauropod dinosaurs: implications for functional morphology, forelimb orientation, and phylogeny. *J Vertebr Paleontol.* 2003, 23(3): 595-613.
- Carroll RL, Holmes RB. Evolution of the appendicular skeleton of amphibians. In: Hall BK (Ed) *Fins into Limbs.* Chicago and London, University of Chicago Press, 2007: 185-224.
- Coates MI, Clack JA. Polydactyly in the earliest known tetrapod limbs. *Nature.* 1990, 347: 66-69.
- Drapeau MSM. Articular morphology of the proximal ulna in extant and fossil hominoids and hominins. *J Hum Evol.* 2008, 55(1): 86-102.
- Eckstein F, Löhe F, Schulte E, Müller-Gerbl M, Milz S, Putz R. Physiological incongruity of the humero-ulnar joint: a functional principle of optimized stress distribution acting upon articulating surfaces? *Anat Embryol (Berl).* 1993, 188(5):449-55.
- Galik K, Baratz ME, Butler AL, Dougherty J, Cohen MS, Miller MC. The effect of the annular ligament on kinematics of the radial head. *J Hand Surg Am.* 2007, 32(8): 1218-24.
- Gatesy SM, Middleton KM. Skeletal adaptations for flight. In: Hall BK (Ed) *Fins into Limbs.* Chicago and London, University of Chicago Press, 2007: 267-283.
- Haines RW. A revision of the movements of the forearm in tetrapods. *J Anat.* 1946, 80: 1-11.
- Hinchliffe JR. Developmental basis of limb evolution. *Int J Dev Biol.* 2002, 46:835-845.
- Hopwood AT. Contributions to the study of some african mammals. –III. Adaptations in the bones of the fore-limb of the lion, leopard, and cheetah. *Zool J Linn Soc-Lond.* 1947, 41: 259-271.
- Humphry GM. On the Comparison of the fore and hind limbs in vertebrates. *J Anat Physiol.* 1876, 10: 659-671.
- Hutson JD. A functional study of the origins of tetrapod forelimb pronation. Thesis. Northern Illinois University. Ann Arbor, ProQuest LLC, 2010. http://media.proquest.com/media/pq/classic/doc/2147714661/fmt/ai/rep/NPDF?_s=usMsPtWHsYRcURkt9dhdaw60jBY%3D
- Jarvik E. Basic structure and evolution of vertebrates. New York, Academic Press, 1980.
- Kapandji IA. L'articulation radio-cubitale inférieure vue sous l'angle de la prono-supination. In: Tübiana R (Ed) *Traité de Chirurgie de la Main.* Paris, Masson, 1980, vol.1: 156-165.
- Landsmeer JMF. The mechanism of forearm rotation in *Varanus exanthematicus*. *J Morphol.* 1983, 175: 119-130.
- Lees VC. The Functional anatomy of forearm rotation. *J Hand Microsurg.* 2009, 1(2): 92-99.
- Lewis OJ. Evolutionary change in the primate wrist and inferior radio-ulnar joints. *Anat Rec.* 1965, 151: 275-286.
- Liem KF, Bemis WE, Walker WF, Grande L. Functional anatomy of the vertebrates. An evolutionary perspective, 3rd Ed. Chapter 9: The postcranial skeleton: the appendicular skeleton. Belmont, Brooks/Cole, Cengage Learning, 2001: 294-314.
- Liem KF, Bemis WE, Walker WF, Grande L. Functional anatomy of the vertebrates. An evolutionary perspective, 3rd Ed. Chapter 11: Functional anatomy of support and locomotion. Belmont, Brooks/Cole, Cengage Learning, 2001: 351-393.
- Long JA, Gordon MS. The greatest step in vertebrate history: a paleobiological review of the fish-tetrapod transition. *Physiol Biochem Zool.* 2004, 77(5): 700-719.
- Ohale LOC, Groenewald HB. The morphological characteristics of the antebrachicarpal joint of the cheetah (*Acinonyx jubatus*). *Onderstepoort Journal of Veterinary Research.* 2003, 70:15-20.
- Palmer AK, Werner FW. The triangular fibrocartilage complex of the wrist – Anatomy and function. *J Hand Surg Am.* 1981, 6: 153-162.
- Paton RL, Smithson TR, Clack JA. An amniote-like skeleton from the early carboniferous of Scotland. *Nature.* 1999, 398: 508-513.
- Pfaeffle HJ, Fischer KJ, Manson TT, Tomaino MM, Woo S L-Y, Herndon JH. Role of the forearm interosseous ligament: is it more than just longitudinal load transfer? *J Hand Surg Am.* 2000, 25: 683-688.
- Pierce SE, Clack JA, Hutchinson JR. Three-dimensional limb joint mobility in the early tetrapod *Ichthyostega*. *Nature.* 2012, 486: 523-526.
- Polly PD. Limbs in mammalian evolution. In: Hall BK (Ed) *Fins into Limbs.* Chicago and London, University of Chicago Press, 2007: 245-268.
- Pruetz JD, Bertolani P, Boyer Ontl K, Lindshield S, Shelley M, Wessling EG. New evidence on the tool-assisted hunting exhibited by chimpanzees (*Pan troglodytes verus*) in a savannah habitat at Fongoli, Sénégal. *R Soc open Sci.* 2015. <http://rsos.royalsocietypublishing.org/content/royopensci/2/4/140507.full.pdf>
- Quigley RJ, Robicheaux GW, Lee TQ. The proximal and distal position of the radius relative to the ulna through a full range of elbow flexion and forearm rotation. *J Hand Surg Eur.* 2014, 39: 535-540.
- Radinsky LB. The evolution of vertebrate design. Chicago and London, University of Chicago Press, 1987: 141-171.
- Russell GV, Stern PJ. The phylogeny of the wrist. *Am J Orthop.* 1998, 7: 494-498.
- Salton JA, Sargis EJ. Evolutionary morphology of the tenrecoidea (mammalia) forelimb skeleton. In: Sargis EJ, Dagosto S (Eds) *Mammalian Evolutionary Morphology: A Tribute to Frederick S. Szalay.* Dordrecht, Springer, 2008: 51-71.
- Shubin NH, Daeschler EB, Jenkins FA. The pectoral fin of *Tiktaalik roseae* and the origin of the tetrapod limb. *Nature.* 2006, 440: 764-771.
- Smithson TR, Wood SP, Marshall JEA, Clack JA. Earliest Carboniferous tetrapod and arthropod faunas from Scotland populate Romer's Gap. *Proc Natl Acad Sci.* 2012, 109(12): 4532-4537.
- Sullivan C, Hone DWE, Xu X, Zhang F. The asymmetry of the carpal joint and the evolution of wing folding in maniraptoran theropod dinosaurs. *Proc Biol Sci.* 2010, 277(1690): 2027-33.
- Swartz SM, Iriarte-Diaz J, Riskin DK, Breuer KS. A bird? A plane? No, it's a bat: An introduction to the biomechanics of bat flight. In: Gunnell GF, Simmons NB (Eds) *Evolutionary History of Bats: Fossils, Molecules and Morphology.* Cambridge, Cambridge University Press, 2012: 317-352.
- Thewissen JGM, Taylor MA. Aquatic adaptations in the limbs of amniotes. In: Hall BK (Ed) *Fins into Limbs.* Chicago and London, University of Chicago Press, 2007: 310-322.
- Vasquez RJ. Functional osteology of the avian wrist and the evolution of flapping flight. *J Morphol.* 1992, 211: 259-268.
- Vasquez RJ. The automating skeletal and muscular mechanisms of the avian wing (Aves). *Zoomorphology.* 1994, 114: 59-71.
- Wildman DE, Uddin M, Liu G, Grossman LI, Goodman M. Implications of natural selection in shaping 99.4% nonsynonymous DNA identity between humans and chimpanzees: Enlarging genus *Homo*. *Proc Natl Acad Sci.* 2003, 100(12): 7181-7188.

Pearls of wisdom and quotes

My approach to any clinical problem was lifted from John Cleese, who created a number of videos aimed at developing a business management strategy. I watched his videos and found that, strangely, his approach is VERY relevant in our clinical arena.

The principles are :

- Develop the question
- What are the alternatives
- What are the risks and complications
- Weigh up the advantages vs the disadvantages.

If you follow this rule you will always make a defensible, and usually very sensible, clinical decision.

One of my teachers (the late Robert Wheeler, Western Australia, supervisor of clinical training and head of Unit) used to say:

An accident produces an uncontrolled injury inflicted for no purpose. Surgery is a controlled injury inflicted for a purpose.

Tony Pohl, director of Royal Adelaide Trauma unit says: A fracture is a soft tissue injury which involves bone.

Thank you for reading these little quotes. My personal opinion is that surgery is an art-form painted with a scientific brush.

Thanks for giving us a palette to work with.

Yours truly,
John Crock
john@johncrock.com
www.johncrock.com
www.aussiehealthabroad.com

“An accident produces an uncontrolled injury inflicted for no purpose. Surgery is a controlled injury inflicted for a purpose.”

IFSSH Scientific Committee on Flexor Tendon Repair

Chair: Esther Vögelin (Switzerland)

COMMITTEE: DAVID ELLIOT (UK), PETER C AMADIO (USA)

REPORT SUBMITTED MAY 2015

TRENDS IN FLEXOR TENDON SURGERY OVER THE LAST 10 YEARS

The results of flexor tendon repair in the hand have improved over the years, which is the result of a combination of improved surgical techniques and better rehabilitation. Further improvements may be on the way. Traditionally, to reduce muscle force on the repair, the wrist has been splinted in flexion after flexor tendon injuries. Now this practice has been called into question. There is debate about many details of technique. The central tenet of modern flexor tendon surgery is to repair and move divided flexor tendons within a few days of injury. The possibility of reducing the effect of adhesions on movement of the repaired tendon has been considered periodically but it remains to be proven whether, by drugs or other means, this can be useful routinely following flexor tendon repair. Like many other parts of hand surgery, when one looks more closely, one discovers that much that seemed fully understood is far from understood

and what we have assumed to be based on hard fact often rests on opinion. Nevertheless, the results of flexor tendon repair in the hand have improved over the last twenty years, as a result of a combination of improved surgical techniques and better rehabilitation. This report examines trends in both.

REHABILITATION REGIMES Splinting and wrist position

At the present time, flexor tendon repairs are mobilised by most surgeons in a dorsal blocking splint as an additional safeguard against tendon rupture, with a definitive dorsal thermoplastic splint being applied 24-72 hours after surgery, whatever the technique of rehabilitation. While the interphalangeal joints are invariably allowed to fully extend, the precise angles to which the wrist and MCP joints may extend in these splints vary from unit to unit. The degree of standardisation of splint construction possible in clinical practice probably belies such precision in print and the variability of the statements in

the literature would suggest that the precise degree to which these joints are allowed to extend may not be of great significance. The degree of flexion of the wrist is probably less significant than previously believed. In an unpublished series of patients in Chelmsford/UK, 50 patients mobilised in the neutral wrist position had no increase in tendon ruptures with the same percentage of good and excellent results as this unit had reported previously with the wrist in the flexed position. Many units now splint the wrist in this position. A paper presented to the American Society for Surgery of the Hand (ASSH) [1] compared the results of similar flexor tendon repairs, treated after surgery with splints that either did or did not immobilize the wrist. Both splints blocked finger metacarpophalangeal joint extension at 30°. Both passive and active finger motion exercises were performed by the patients while wearing the splints. At both six and twelve weeks after injury, the short-splint group had significantly ($p < 0.05$) better

interphalangeal joint motion; at the twelve-week point, it was better by about 10°. Rupture rates were similar in the two groups. On the basis of this study, it may be reasonable to consider changing the traditional wrist-immobilization splinting regimen when treating patients with flexor tendon lacerations in the fingers. Peck et al [2] compared the outcomes of patients with uncomplicated zone II flexor tendon repairs who had been rehabilitated using either the traditional forearm-based splint or the Manchester short splint (splint with no wrist component). It demonstrated similar rupture rates between the two groups (short arm splint: 4.4% after 3 and 6 weeks; long arm splint: 3.9% after 1, 8 and 10 weeks) comparable to published levels using four-strand repair techniques and indicated that the use of a shorter splint appears to be safe for the rehabilitation of these injuries.

Time of Splinting

Whatever the method of rehabilitation, there has been relative consensus of opinion about the length of rehabilitation, although the source of the timing of the various stages of this assisted recovery is obscure. Whichever technique of early mobilisation is used, flexor tendon repairs are currently mobilised in dorsal splints with no active grasping with the fingers for 4-5 weeks. There follows a period of 3-4 weeks of gradual increase of activity with the splint only being worn at night and in public places, where the fingers might be accidentally pulled into extension.

Full use of the hand for light activities and therapy to correct failures of finger extension begins only after 8 weeks, with heavy grasping activities being avoided for 12 weeks. Patients return to light manual activities at 8-10 weeks and to heavy manual labour at 12 weeks after surgery. Although suggestions of shortening of the period of splinting are sometimes aired in meetings, they have not yet appeared in print. An interesting finding of the recent unpublished work in Bern/Switzerland (see below) was that the ruptures occurred later following multi-strand repairs (average rupture time 47(range 24-80) days) than reported previously with two-strand repairs, after which rupture commonly occurred in the first four weeks [9].

“Overall, there was not a statistically significant difference when comparing total complications between passive versus active protocols

While this may reflect particular aspects of management in this unit, it, nevertheless, should suggest caution over moving to a shortened splinting period and suggests a need for further investigation.

Many of the recent papers described how active motion protocols aim to increase early tendon excursion to prevent adhesion formation and to produce increased motion [3-7].

Active/passive Rehabilitation protocols and functional outcome

One review analysis [3] showed that in passive motion rehabilitation, the overall complication rate was 13%, with 4% from rupture and 9% from decreased motion. Active motion rehabilitation showed an overall 11% complication rate, with 5% from ruptures and 6% from decreased motion. Rupture rate in early active motion articles did not reveal statistical difference between 4-strand, 2-strand or 6-strand repair. Overall, there was not a statistically significant difference when comparing total complications between passive versus active protocols. However, while passive protocols had a statistically significant lower risk of rupture, they also had a significantly higher risk of decreased post-operative range of motion compared to early active motion protocols.

Trumble et al [4], who produced level I evidence directly comparing active place-and-hold therapy with passive motion. The study showed greater interphalangeal joint motion, significantly smaller flexion contractures, and higher patient

satisfaction with early active motion without increased risk for repair rupture. They reported a 3% rupture rate.

Frueh et al [5] compared early passive mobilization (EPM) with controlled active motion (CAM) after a 4-strand flexor tendon repair in zones 1 and 2 in 159 digits. There was a statistically significant difference between the TAM values of the EPM (n=87; TAM 170°) and the CAM (n= 14; TAM 200°) protocols 4 weeks after surgery but not at 12 weeks (TAM 220°). Rupture rates were 5% (CAM) and 7% (EPM), which were not statistically different.

More recently, there has been some question as to whether early, limited arc active motion might have some benefit over place and hold exercise, but this has not been studied formally. Of the ongoing rehabilitation controversies, possibly the one most often discussed is which is the best of the active mobilization techniques today: Kleinert (active extension-passive flexion), now often amalgamated with that of Duran-Houser, or Early Active Mobilization (active extension-active flexion). If one looks at both techniques closely, one realizes that both are moving towards freer movement and both are pushing repairs ever harder during the early post-operative period, making this discussion an unproductive exercise. The questions begged by this trend to mobilise earlier and harder are how far we can go along this track without increasing the rate of tendon rupture and do we need to follow this path, rather than which is the best regimen

for doing this. It also has to be borne in mind that many units repairing flexor tendons have insufficient therapists and are unlikely to acquire more in the current economic climate. Early active mobilisation is the cheapest and least therapist dependent method of rehabilitation. The papers published in this century increasingly report mobilisation by early active motion, which may reflect these economic benefits rather than any functional benefit.

SURGICAL CONSIDERATIONS

At the time of writing, there is no 'best' suture material or 'best' suture technique and the choice of each in any one unit, country or area of the world is more often determined by opinion, historical precedence and availability of particular materials than by science.

Number of strands, core suture techniques and functional outcome

The 'best' of core sutures still remains to be identified, with surgeons publishing their results during the last ten years following 4-strand or 6-strand core suture repair reporting an average of 5.4 (range 0-17)% repair ruptures. (Table 1) Critical analysis of the rupture rates in clinical papers written during the last twenty years fails to show a consistently significant reduction in rupture of repairs, despite the laboratory evidence that four and six strand suture techniques are stronger than two-strand repairs. Most reported series of primary flexor tendon repairs in zone 2 of the fingers, which has been the testing ground of

flexor tendon surgery for fifty years, include a rupture rate of approximately 5%, whatever method of core and circumferential suturing is used.

A recent meta-analysis demonstrated no significant difference in rupture rates between 2-strand and multi-strand repairs. [6] This meta-analysis also showed a trend but no statistical significance that early active motion using a 4-strand core suture repair technique had a lower risk for rupture (2%) compared to those using a 2-strand technique (6%).

In another review [7], no difference in functional outcomes between 2- and multistrand core suture flexor tendon repairs could be shown. A comparison of 2-strand (755 digits vs 656 digits) versus multistrand (664 digits vs 145 digits) showed no significant difference in outcomes (Strickland Criteria group vs ASSH criteria group) The repair technique was also examined in zone 2 in the 2-strand repair group with modified Kessler (634 digits) versus other techniques (110 digits); no significant difference was found in either outcomes or rupture rate. There was a rupture rate of 3.9% (2-strand repair group: 4.3%, multistrand repair group: 3.2%). There was a trend for a lower rupture rate in the multistrand repair group but without statistical significance.

Even if rupture rates have slightly decreased over the last 10 years there remains great variation in results between different units, with some studies having higher rupture rates despite multistrand repair and other case series using two-strand sutures without any rupture. [8] (Table 1)

TABLE 1: Flexor tendon repair studies from 2002-2014

Reference	Patients/Digits Tendons,Zone II	CAM/Kleinert*	Suture Repair (digits)	Outcome	Rupture rates	Comments
Hatanaka H, 2002	6/7 tendons	Active mobilization,	FDP: 2-0 loop, epit. 6-0 FDS: 4-0 loop Tang, epit. 6-0; 2 strand	Strickland 86% good-excellent	1 (14%) after 6 weeks	
Klein L, 2003	35/40 tendons Zone I-III	Active motion, dorsal blocking splint, rubber band traction 5 weeks	Tajima, Kessler, Core 3-0/4-0, epit. 6-0; 4 strand	Strickland 95% good-excellent Zone II 88% goode-excellent Zone I,III	1 (2.5%) after 4.5 weeks	
Braga-Silva J, 2005	82/136 tendons	Active mobilization	Modified Kessler, 3-0, epit. 5-0; 2 strand	IFSSH and Strick-land criteria: Long fingers: 98% good- excellent (Strickland); 82%good (IFSSH)	5 (7.4% long-finger, 3.6% thumb) after 2 weeks	
Chai SC, 2005	8/15/28 tendons, only 25 repaired	Dynamic traction, passive motion	Supramid 6 strand (9); modified Kessler 2 strand(16)	Strickland 93% good-excellent	0	Multiple digits mixed results
Hung LK, 2005	32/46 : 24 II in Zone I,II,III,V	Early active mobilization: passive flexion, then active flexion	Modified Kessler— 4-0 nylon with 6-0 nylon epitendinous 2 strand repair	ASSH: 71% good-(8.3%) 6 weeks excellent in zone II	2 ruptures in zone II (8.3%) 6 weeks and 1 week after repair 1 rupture in zone III (4.5%)	
Su BW, 2005	67/85 29/34Tenofix 38/51 Control	Modified Kleinert, active Flexion at 4 weeks	TenoFix anchors, 2-0 stainless steel sut., epit. 6-0 (34); 3-0 cruciate, epit. 6-0 (51); 4-strand	Strickland: 67% good- excellent TenoFix 70% good-excellent control	TenoFix: 0 Control: 9 (17.6%) 6 weeks after repair	
Chan TK, 2006	16/21/31 tendons	3 wk active extension /passive flexion, 2 wk active flexion without resistance, 2 wk active flexion with resistance	FDP: modified Kessler —4-0 nylon with 6-0 nylon epitendinous FDS: horizontal mattress sutures 2-strand repair	Buck-Gramcko: 81% good-excellent	1 (4.8%) 1 week after repair	Multiple digits mixed results
Yen CH, 2008	20 patients	Active extension, active place-and-hold—10 patients Kleinert method—10 patients	4-0 Prolene core sutures plus 6-0 Prolene circumferential sutures 4-strand repair	Mayo Wrist Score: Active motion: 70% good-excellent Kleinert splint: 0% good-excellent	Active place and hold: 0 Kleinert splint: 1 (10%) 5 weeks after repair	
Hoffmann G, 2008	71/77	46/51 early active mobilization; 25/26 modified Kleinert's regimen	6-strand double loop polyamid (4-0), modified 2 strand Kessler suture 4-0 Prolene, both epit. 5-0 Prolene	Strickland: EAM: 39/50 good-excellent (78%) Mod.Kleinert: 9/21 good-excellent (43%)	EAM: 1/51(2%) Mod. Kleinert 3/26 (11%) between 4-8 weeks after surgery	28% vs 38% needed extension splints
Kitis A, 2009	192/263 digits	Group 1: modified Kleinert (Washington regimen) — 98/137 digits) Group 2: Controlled passive movement (CPM)—94/126 digits	Modified Kessler— 4-0 nylon with 6-0 nylon epitendinous 2-strand repair	Buck-Gramcko: Group 1: 87% excellent total active movement, 89% grip strength, Group 2: 75% excellent total active movement, 81% grip strength,	Modified Kleinert: 0 CPM: 1 (0.8%) in second week after repair	Modified Kleinert: 16 extension deficits CPM: 26 extension deficits

Reference	Patients/Digits Tendons,Zone II	CAM/Kleinert*	Suture Repair (digits)	Outcome	Rupture rates	Comments
Saini N, 2010	75 digits Zone II-V	Modified Kleinert's regimen and Silfverskiold regimen: active extension with initial active flexion and later passive flexion	Modified Kessler— 3-0 or 4-0 polypropylene core suture and epitendinous stitch 2-strand repair	Louisville: 82% good-excellent	2 (3%)	2 contractures (3%)
Trumble TE, 2010	103/119 digits	Passive motion—51 patients with 58 digits Active motion with place- and-hold—52 patients with 61 digits	FDP: Strickland method—2 core sutures of 3-0 polyester and 6-0 Prolene epitendinous FDS: simple Kessler with 3-0 polyester 4-strand repair	Strickland: Active motion: IP joint motion 156° ± 25°, 94% good- excellent Passive motion: motion 128° ± 22°, 62% good-excellent	Passive motion: 2 (3.8%) Active motion: 2 (3.7%) 3/4 ruptures in small digits	Six patients with multiple -digit injuries had overall worse outcomes in both groups
Bal S, 2010	31/78 Zone II (14/25) Zone V (17/53)	Modified Kleinert protocol	Modified Kessler— 3-0 Prolene with epitendinous 5-0 Prolene 2-strand repair	ASSH: 52% good-excellent in zone II 83% good-excellent in zone V	2 zone II (8%) 1 zone V (1.9%) after 4-8 weeks	
Sadow MJ, 2011	53/73 Zone I, II	Early active Mobilization; dorsal splint 20° wrist extension, 80° MCP flexion, IP joint 0° extension for 6 weeks, place & hold; buddy taping for 4 weeks	4-strand single cross grasp 3-0/4-0 polyester or 4-0 nylon or 4-0 polypropylene; epitendinous repair 5-0/6-0 nylon/ polypropylene	Strickland 71% good-excellent 34% fair, 15% poor	3 zone II (4.6%) after 2-4 weeks	Follow up 65/73 tendons
Starnes T, 2012	21/24 patients (sharp injuries) 13/17 patients (saw injuries)	Early active mobilization protocols (17/21 in the sharp group [81%]; 8/13 in the saw group[62%]); 5%/8% modified Duran protocol	4-strand core suture and epitendinous suture	Strickland: 30% good-excellent results in saw group; 46% in sharp group	0 in the sharp group 1 in the saw group (5.8%)	9/17 in saw group secondary surgery (3/24 in sharp group)
Frueh FS, 2014	132/159	Early passive motion (EPM): 138; Controlled active motion (CAM): 21 Dorsal splint in 10° wrist flexion, 40° MCP flexion, IP joint 0° for 5 weeks, then 3 weeks at night with active blocking exercise and passive flexion	85% 4-0/3-0 polyester braid ; 4-strand; 15% 2-strand or 6-strand; epit. 6-0	ASSH: 54% good-excellent EPM 65% good CAM	EPM 10 (7%) CAM 1 (5%)	29 patients reoperated (tenolysis)

In a review by Elliot et al. [9] the rupture and re-repair rate was evaluated between 1989-2003. The decrease of the rupture rates has been seen to decrease in reports of more recent years, typically after 2005 but remained between 2-7%. [9] With increased repair strength, the rate of ruptures seem to occur later than in the review by Elliot. Our own experience (University Hospital Bern) in a recent unpublished series of 147 flexor tendon repairs between 2011-13 using a six strand repair and early active flexion protocol [10,11] with flexion of the wrist in 30° for 4 weeks demonstrated a surprisingly high rupture rate of 10%. The average of rupture time was at 46.7 days (24-80) after primary repair. (Table 2) In 3 patients, there was a history of a fall causing the rupture, 1 patient suffered from a connective tissue disease, while 6 times no rupture cause

could be defined. In 6 cases the FDS tendon was resected (indicating perhaps a more difficult repair?). Eleven of the ruptured tendons had been treated with early active flexion protocol while 5 followed a classic Kleinert regime (active extension, passive flexion). Exceptionally, in 2 of 16 ruptures, a 4 strand and not a 6 strand repair was performed. This rupture rate is in contrast to another published series including 51 flexor tendon repairs with the same repair technique (6-strand Lim Tsai and epitendinous running suture) and an early active flexion protocol, which recorded a rupture rate of 2%. [10,11]

TABLE 2: Rupture delay after primary repair from 1989-2003 in comparison to 2011-13

Time after primary repair of rupture (weeks)	No of mechanical ruptures (Elliot 2006)	No of mechanical ruptures (Vögelin 2014, unpublished)
<1	8	-
1-2	23	-
2-3	11	-
3-4	8	1
4-5	6	1
5-6	2	4
6-7	2	2
7-8	1	1
8-9	1	-
9-10	-	1
11-12	-	1
Average (days)	18 (3-61)	46.72 (24-80)

Unpublished recent data from Chelmsford also suggests no improvement in rupture rate despite a move towards four and six strand core sutures. There is also some evidence that suture material has a deleterious effect on tenocyte activity and, hence, a possibility that increasing amounts of suture material increase this effect [12]. So, perhaps, we are, unwittingly, making tendon repair breakdown more likely as we put more foreign suture material into the tendon and simply putting in more complex sutures is possibly not the answer, or not the only answer.

Inserting these more complicated sutures may have another cost: they are more difficult to insert and make an already complicated procedure even more so. Bearing in mind that most

primary flexor tendon surgery is carried out by trainee hand surgeons world-wide, this may prove a serious disadvantage to their use. An alternative approach has become increasingly popular in the Far East using a single suture repair with a looped double strand nylon suture. Tang and his colleagues [13] still could not avoid the inevitable small rupture rate in their early clinical study, but its simplicity at a time when the Western approach may be becoming too complicated.

Over the past 10 years, surgeons have reported good to excellent results in 80% or more of the tendons that underwent 4-strand or 6-strand core suture repair, with 0% to 17% repair ruptures, on average 5.4%. (Table 1) This period saw the first widespread use of

multi-strand core suture repairs, but in most reports disruption is still seen after 5 weeks during early active motion. There are reports of no repair ruptures in some case series, but, despite all of the progress in surgical technique and rehabilitation protocols, the rupture rate has not disappeared yet. (Table 1) Nevertheless, most repairs are probably done currently with four-strand core sutures, although the literature in the last ten years includes more papers using two strand than multistrand repairs.

The Circumferential Suture

In the latter years of the last century, the tendon repair was commonly completed using a continuous circumferential over-and-over suture, usually of 5/0 or 6/0 monofilament nylon or polypropylene. This was originally introduced to tuck in ragged parts of the tendon edges to allow easier gliding. This is particularly so along the deep surface of the tendon repair after completing the core suture, especially in the tight confines adjacent to the A4 pulley. Placing sutures along the 'back wall' of the repair prior to completing the core suture, a technique commonly used with simple circumferential suturing to avoid bunching of the repair, is very much more difficult with the complex circumferential sutures. Although elaboration of the circumferential suture raised the possibility of dispensing with the core suture entirely, the pendulum of clinical activity has swung back

more recently to increasing the core suture strength, with simple circumferential over-and-over suturing being the commonest finishing suture in current use.

The Sheath

The period of closing the tendon sheath completely has passed. The repaired tendons, which are inevitably greater in diameter than the original tendon, are more likely to suffer restriction of their free movement if the sheath has been closed. However, even with a policy of simply laying the sheath back, catching of some repairs on the main pulleys remains a problem. Elliot [14] and Tang [13] have pointed out that repairs snagging on pulleys treated by early mobilisation will either restrict movement of the finger or cause the repair to snap and suggested that judicious venting of the A2 and A4 pulleys is often necessary to achieve free movement of the repair. This does not allow bow-stringing of the tendons provided most of the sheath is intact [8,9]. Wide-awake surgery [15] makes this factor more obvious to the operating surgeon. In all tendon surgery, surgeons should consider the diameters of the pulleys and how the tendon fits inside them. It is crucial to always leave room to accommodate edema and swelling of the tendons which have undergone surgery.

An independent analysis which compared venting of the pulley system and early active mobilization in 114 digits with

no venting and passive flexion-active extension mobilization in 335 digits showed a trend toward an improvement in the incidence of excellent outcomes in those fingers with appropriately vented pulleys, but this difference was not statistically significant. [7] The A2 pulley can be vented partly, up to 50% of its length, to allow tendon motion during tenolysis, provided that remaining elements of the sheath are intact (for proximal A2 release, the A1 pulley and for distal release A3). It appears as well that the A4 pulley can be safely vented, if the A3 and A5 pulleys are intact. [16] In all tendon surgery, surgeons should consider the diameters of the pulleys and how the tendon fits inside them. It is crucial to always leave room to accommodate edema and swelling of tendons that have been operated on. [7]

Improving the results of tendon repair by biological and biophysical interventions. Investigators have studied the effect of added lubricants on reducing adhesion formation for many years [17-29]. Results have been inconsistent, perhaps related to the residence time of the lubricant preparation. Higher molecular weight formulations appear to have better clinical results in some studies, but not uniformly. Fixing a lubricant to the tendon surface has a large effect on reducing adhesions, but at the cost of delaying healing, at least in animal models. Adding stem cells

within the repair site can to some extent reverse this problem, again in animal models, but there have been no clinical reports on the use of stem cells to aid flexor tendon healing [28]

CONCLUSIONS

Over the last 10 years, repair strength (4-and 6-strand repair) and newer suture materials (double loop polyester, supramid or tenofix) have been improved as well as active mobilization rehabilitation protocols including a change of wrist position by modification of splints to reduce the work of flexion during active flexion. Despite all of these modifications, tendon ruptures have not been eliminated, although they may seem to occur later, after 4-10 weeks, rather than at 2-4 weeks, as was often noted in past studies. This might suggest that the stronger repair may prevent earlier ruptures but raises the question as to whether stronger repairs and earlier mobilization may slow healing somehow, due either to the bulk of the multistrand repairs or to gapping that proceeds more slowly to rupture with a multistrand repair than it might with a 2-strand suture. The near future will show whether a change of wrist position and avoiding place and hold positions in the controlled active motion protocols will improve the results, or whether application of lubricants [29] will help to avoid gapping and rupturing of the tendons while maintaining full interphalangeal joint motion.

“The central tenet of modern flexor tendon surgery is to repair and move divided flexor tendons within a few days of injury.

REFERENCES

1. Amadio PC. What's new in Hand Surgery? J Bone Joint Surg Am.2014;96:522-6

2. Peck FH, Roe AE, Ng CY, Duff C, McGrouther DA, Lees VC. The Manchester short splint: A change to splinting practice in the rehabilitation of zone II flexor tendon repairs Hand Therapy 2014, Vol. 19(2) 47–53

3. Starr HM, Snoddy M, Hammond KE, Seiler JG. Flexor tendon repair rehabilitation protocols: a systematic review. J Hand Surg Am. 2013;38A:1712-1717

4. Trumble TE, Vedder NB, Seiler JG III, et al. Zone-II flexor tendon repair: a randomized prospective trial of active place-and-hold therapy compared with passive motion therapy. J Bone Joint Surg Am.

2010;92(6):1381–1389.

5. Früh FS, Kunz VS, Gravestock IJ, Held L, Haefeli M, Giovanoli P, Calcagni M. Primary flexor tendon repair in zones I und II: early passive mobilization versus controlled active motion. J Hand Surg Am. 2014;39(7):1344e1350

6. Dy CJ, Hernandez-Soria A, Ma Y, Roberts TR, Daluiski A. Complications after flexor tendon repair: a systematic review and meta-analysis. J Hand Surg Am. 2012;37(3):543e551.e1.

7. Hardwicke JT, Tan JJ, Foster MA, Titley OG. A systematic review of 2-strand vs multistrand core suture techniques and functional outcome after digital flexor tendon repair. J Hand Surg Am. 2014;39(4):686e695.

8. Tang JB Outcomes and Evaluation of Flexor Tendon Repair. Hand Clin 2013;29;251-259.

9. Dowd MB, Figus A, Harris SB, Southgate CM, Foster AJ, Elliot D. The results of immediate re-repair of zone I and II primary flexor tendon repairs which rupture. J Hand Surg. 2006;31B(5);507-513.

10. Hoffmann GL, Büchler U, Vögelin E. Clinical results of flexor tendon repair in zone II using a six-strand double-loop technique compared with a two-strand technique J Hand Surg 2008;33E:418-23

11. Vögelin E, Hoffmann G, van

der Zypen V. Clinical Primary Flexor Tendon Repair and Rehabilitation: The Bern Experience in Chapter 13 in Tendon Surgery of the Hand, Tang JB, Amadio PC, Guimberteau JC, Chang J. Elsevier Saunders 2012, ed

12. Wong JK, Cerovac S, Ferguson MW, McGrouther DA. The cellular effect of a single interrupted suture on tendon. J Hand Surg Brit 2006;31:358-367.

13. Elliot D. Primary Flexor Tendon Repair - Operative Repair, Pulley Management and Rehabilitation.J Surg Brit 2002;27:507-514

14. Tang JB. Indications, Methods, Postoperative Motion and Outcome Evaluation of Primary Flexor Tendon Repairs in Zone 2. J Hand Surg Eur 2007;32:118-129

15. Lalonde DH. An evidence-based approach to flexor tendon laceration repair. Plast Reconstr Surg 2011;127:885-890

16. Tang JB. Release of the A4 pulley to facilitate zone II flexor tendon repair. J Hand Surg Am 2014;39(11):2300-07

17. Hayashi M, Zhao C, Thoreson AR, Chikenji T, Jay GD, An KN, Amadio PC. The effect of lubricin on the gliding resistance of mouse intrasynovial tendon. PLOS ONE. 2013 (8);12:e83836

18. St Onge R, Weiss C, Denlinger JL, Balazs EA. A preliminary assessment of Na-hyaluronate injection into “no man's land”

for primary flexor tendon repair. Clin Orthop Relat Res. 1980(146):269-75

19. Hagberg L, Gerdin B. Sodium hyaluronate as an adjunct in adhesion prevention after flexor tendon surgery in rabbits. J Hand Surg Am. 1992;17(5):935-41.

20. Moro-oka T, Miura H, Mawatari T, Kawano T, Nakanishi Y, Higaki H, et al. Mixture of hyaluronic acid and phospholipid prevents adhesion formation on the injured flexor tendon in rabbits. J Orthop Res. 2000;18(5):835-40

21. Menderes A, Mola F, Tayfur V, Vayvada H, Barutcu A. Prevention of peritendinous adhesions following flexor tendon injury with seprafilm. Ann Plast Surg. 2004;53(6):560-4

22. Riccio M, Battiston B, Pajardi G, Corradi M, Passaretti U, Atzei A, et al. Efficiency of Hyaloglide in the prevention of the recurrence of adhesions after tenolysis of flexor tendons in zone II: a randomized, controlled, multicentre clinical trial. J Hand Surg Eur Vol. 2010;35(2):130-8

23. Wiig M, Olmarker K, Hakansson J, Ekstrom L, Nilsson E, Mahlapuu M. A lactoferrin-derived peptide (PXL01) for the reduction of adhesion formation in flexor tendon surgery: an experimental study in rabbits. J Hand Surg Eur Vol. 2011;36(8):656-62

24. McGonagle L, Jones MD, Dowson D, Theobald PS. The bio-tribological properties of

anti-adhesive agents commonly used during tendon repair. J Orthop Res. 2012;30(5):775-80

25. Zhao C, Sun YL, Jay GD, Moran SL, An KN, Amadio PC. Surface modification counteracts adverse effects associated with immobilization after flexor tendon repair. J Orthop Res. 2012;30(12):1940-4. PMCID: 3449004

26. Amadio PC. Gliding resistance and modifications of gliding surface of tendon: clinical perspectives. Hand Clin. 2013;29(2):159-66. PMCID: 3662633.

27. Kohanzadeh S, Lugo L, Long JN. Safety of antiadhesion barriers in hand surgery. Ann Plast Surg. 2013;70(5):527-9

28. Zhao C, Ozasa Y, Reisdorf RL, Thoreson AR, Jay GD, An KN, et al. CORR(R) ORS Richard A. Brand Award for Outstanding Orthopaedic Research: Engineering flexor tendon repair with lubricant, cells, and cytokines in a canine model. Clin Orthop Relat Res. 2014;472(9):2569-78. PMCID: 4117902

29. Zhao C, Wei Z, Reisdorf RL, Thoreson AR, Jay GD, Moran SL, et al. The effects of biological lubricating molecules on flexor tendon reconstruction in a canine allograft model in vivo. Plast Reconstr Surg. 2014;133(5):628e-37e. PMCID: 4006300

REFERENCES OF TABLE 1

(Flexor Tendon Repair between 2002-2014)

1. Hatanaka H, Kojima T, Mizoguchi T, et al. Aggressive active mobilization following zone II flexor tendon repair using a two-stranded heavy-gauge locking loop technique. J Orthop Sci. 2002;7(4):457–461

2. Klein L. Early active motion flexor tendon protocol using one splint. J Hand Ther. 2003;16(3):199–206.

3. Braga-Silva J, Kuyven CR. Early active mobilization after flexor tendon repairs in zone two. Chir Main. 2005;24(3–4):165–168.

4. Chai SC, Wong CW. Dynamic traction and passive mobilization for the rehabilitation of zone II flexor tendon injuries: modified regime. Med J Malaysia. 2005;60 Suppl C:59–65.

5. Hung LK, Pang KW, Yeung PL, et al. Active mobilization after flexor tendon repair: comparison of results following injuries in zone 2 and other zones. J Orthop Surg (Hong Kong). 2005;13(2):158– 163.

6. Su BW, Solomon M, Barrow A, et al. Device for zone-II flexor tendon repair. A multicenter, randomized, blinded clinical trial. J Bone Joint Surg Am. 2005;87(5):923–935.

7. Chan TK, Ho CO, Lee WK, et al. Functional outcome of the hand following flexor tendon repair at the ‘no man’s land.’ J Orthop Surg (Hong Kong). 2006;14(2):178–183.

8. Yen CH, Chan WL, Wong JW, et al. Clinical results of early active mobilisation after flexor tendon repair. *Hand Surg*. 2008;13(1): 45–50.
 9. Hoffmann GL, Büchler U, Vögelin E. Clinical results of flexor tendon repair in zone II using a six-strand double-loop technique compared with a two-strand technique *J Hand Surg* 2008;33E:418-23
 10. Kitis PT, Buker N, Kara IG. Comparison of two methods of controlled mobilisation of repaired flexor tendons in zone 2. *Scand J Plast Reconstr Surg Hand Surg*. 2009;43(3):160–165.
 11. Saini N, Kundnani V, Patni P, et al. Outcome of early active mobilization after flexor tendons repair in zones II-V in hand. *Indian J Orthop*. 2010;44(3):314–321.
 12. Trumble TE, Vedder NB, Seiler JG III, et al. Zone-II flexor tendon repair: a randomized prospective trial of active place-and-hold therapy compared with passive motion therapy. *J Bone Joint Surg Am*. 2010;92(6):1381–1389.
 13. Bal S, Oz B, Gurgan A, et al. Anatomic and functional improvements achieved by rehabilitation in zone II and zone V flexor or tendon injuries. *Am J Phys Med Rehabil*. 2011;90(1):17–24.
 14. Sandow MJ, McMahon M. Active mobilisation following single cross grasp four-strand flexor tenorrhaphy (Adelaide repair). *J Hand Surg Eur* 2011;36: 467–75
 15. Starnes T, Saunders RJ, Means KR. Clinical outcomes of zone II flexor tendon repair depending on mechanism of injury. *J Hand Surg Am* 2012;37:2532–40.
 16. Früh FS, Kunz VS, Gravestock IJ, Held L, Haefeli M, Giovanoli P, Calcagni M. Primary flexor tendon repair in zones I und II: early passive mobilization versus controlled active motion. *J Hand Surg Am*. 2014;39(7):1344e1350
- HISTORICAL LANDMARK REFERENCES**
- Mason ML, Allen HS (1941). The rate of healing of tendons. An experimental study of tensile strength. *Ann Surg* 1941;113:424-59
- The fundamental need to mobilise repaired flexor tendons early to avoid adhesion and loss of tendon gliding is now generally accepted, as is the fact that healing of the flexor tendon, at least in the digits, does not necessitate the formation of adhesions. Experimental evidence would also suggest that this early movement encourages more rapid tendon healing under the influence of longitudinal forces (Mason and Allen, 1941; Gelberman et al, 1981).
 - The principle of the core sutures in common use is that the suture grips the tendon at a distance from the cut ends to prevent the suture pulling through the tendon fibres when subject to longitudinal tension during mobilisation in the first few weeks after repair, at which time the tendon ends soften (Mason and Allen, 1941).
- Urbaniak JD, Cahill JD, Mortenson RA. Tendon suturing methods: analysis of tensile strengths. In Hunter JM, Schneider LH eds, *Symposium on Tendon Surgery*. St Louis: Mosby, 1975:70-80
- The softening of the tendon ends eliminates any advantage of strength of different suture materials (Urbaniak, 1975).
 - Kirchmayr L. Zur Technik der Sehnennaht. *ZBL Chir* 1917;40:906-7
- Kessler I, Nissim F. Primary repair without immobilisation of flexor tendon division within the digital sheath. *Acta Orthop Scand* 1969;40:587-601
- Until the beginning of this century, the commonest core sutures used in Europe and the United States of America were the two-strand Tajima and Strickland modifications of the suture originally described in 1917 by Kirchmayr and re-described in 1969 by Kessler and Nissim.
- Savage R. In vitro studies of a new method of flexor tendon repair. *J Hand Surg Brit* 1985;10:135-41
- Following the laboratory work of Savage in 1985, showing that a six strand Kirchmayr/Kessler-type of core suture was very much stronger than two-strand repairs, there has followed two decades of intense activity to find a four- or six-strand suture which achieves a similar strength but is more easily placed within the cut tendons than the Savage suture and a multitude of four and six strand core sutures have been described and tested, mostly in vitro (Tables 1 and 2).
 - Savage reported one rupture in 31 fingers with zone 2 complete flexor divisions repaired with a six strand suture, a rupture rate of 3%.
- Savage R, Risitano G. Flexor tendon repair using a “six strand” method of repair and early active mobilisation. *J Hand Surg Brit* 1989;14:396-9
- The degree of flexion of the wrist in a splint is probably less significant than previously believed. In fact, the extreme flexion advocated in early papers is almost a Phalen test position and can have the same effect on the median nerve as this test, particularly when associated with the considerable local oedema of a zone 5 injury. Savage (1988) suggested that flexion of the wrist did not achieve less tension on flexor tendon repairs distal to the wrist because any relaxation of the flexor muscles was countered by increased tension on, and spontaneous firing of, the extensor muscles applying force to the repairs in the opposite direction. He suggested that the position achieving least tension on repairs in the fingers and palm was the ‘resting position’ in which we commonly splint hands, with the wrist in slight extension.
- Harris SB, Harris D, Foster AJ, Elliot D. The aetiology of acute rupture of flexor tendon repairs in zones 1 and 2 of the fingers during early mobilization. *J Hand Surg Brit* 1999;24:275-80
- Harris et al, reported 17 ruptures (4%) in a series of 397 fingers with zone 2 complete flexor divisions using a two strand modified Kessler core suture, suggesting that other factors than the core suture configuration may influence the rupture rate of any one unit.
- Tsuge K, Ikuta Y, Matsuishi Y. Intra-tendinous tendon suture in the hand. *Hand* 1975;7:250-5
- Tsuge K, Ikuta Y, Matsuishi Y. Repair of flexor tendons by intratendinous suture. *J Hand Surg* 1977; 2:436-40
- Tang JB, Shi D, Gu YQ, Chen JC, Zhou B. Double and multiple looped suture tendon repair. *J Hand Surg Brit* 1994;17:699-703
- Tang JB, Gu YT, Rice K, Chen F, Pan CZ. Evaluation of four methods of flexor tendon repair for postoperative active mobilisation. *Plast Reconstr Surg* 2001;107:742-9
- Inserting these more complicated sutures may have another cost: they are more difficult to insert and make an already complicated procedure even more so. Bearing in mind that most primary flexor tendon surgery is carried out by trainee hand surgeons worldwide, this may prove a serious disadvantage to their use. An alternative approach has become increasingly popular in the Far East, where Tsuge described a single suture repair with a looped double strand nylon suture which acts to grip the tendon on either side of the division in a manner which is akin to a single, large epitendinous suture (Tsuge et al, 1975, 1977). This was elaborated by Tang, who suggested using three Tsuge sutures spaced evenly around the circumference of the tendon (Tang et al, 1994, 2001).
- Wade PJF, Wetherell RG, Amis AA. Flexor tendon repair : significant gain in strength from the Halsted peripheral suture technique. *J Hand Surg Brit* 1989;14:232-5
- Lin GT, An KN, Amadio PC, Cooney WP. Biomechanical studies of running suture for flexor tendon repair in dogs. *J Hand Surg Am* 1988;13:553-8
- However, it became evident that the circumferential suture has considerable strength and is much more significant than the tidying role originally ascribed to it (Wade et al, 1986; Lin et al, 1988).
- Kubota H, Aoki M, Pruitt DL, Manske PR. Mechanical properties of various circumferential tendon suture techniques. *J Hand Surg Brit* 1996;21:474-80
- A further problem of increasing the elaboration of this suture on the surface of the tendon is increasing resistance to free gliding of the tendon within the tendon sheath (Kubota et al, 1996) and it was never established which of the new circumferential sutures provided the most useful balance between additional strength and increased

resistance to movement.

Gelberman RH, Amilf D, Gonsalves M, Woo S, Akeson WH. The influence of protected passive mobilisation on the healing of flexor tendons : a biochemical and microangiographic study. Hand 1981;13:120-8

- The fundamental need to mobilise repaired flexor tendons early to avoid adhesion and loss of tendon gliding is now generally accepted, as is the fact that healing of the flexor tendon, at least in the digits, does not necessitate the formation of adhesions. Experimental evidence would also suggest that this early movement encourages more rapid tendon healing under the influence of longitudinal forces (Mason and Allen, 1941; Gelberman et al, 1981).

Duran RH, Houser RG. Controlled passive motion following flexor tendon repairs in zones II and III. In American Academy of Orthopaedic Surgeons Symposium on Flexor Tendon Surgery in the Hand, Hunter JM, Schneider LH eds, St.Louis:Mosby,1975:105-14

- Mobilising primary flexor tendon repairs completely passively in both directions (passive extension – passive flexion) , either by a therapist or by the patient with his/her other hand, was introduced by Duran and Houser in 1975 and embraced by Strickland and his colleagues in Indianapolis (Strickland and Glogovac, 1980). Although the original authors had a 15% rupture rate and only 53% of the digits achieved a good or excellent

range of motion in the second paper, this technique has been used widely, particularly in the United States.

Strickland JW, Glogovac SV. Digital function following flexor tendon repair in Zone II : a comparison of immobilisation and controlled passive motion techniques. J Hand Surg 1980;5:537-43

- Mobilising primary flexor tendon repairs completely passively in both directions (passive extension – passive flexion) , either by a therapist or by the patient with his/her other hand, was introduced by Duran and Houser in 1975 and embraced by Strickland and his colleagues in Indianapolis (Strickland and Glogovac, 1980). Although the original authors had a 15% rupture rate and only 53% of the digits achieved a good or excellent range of motion in the second paper, this technique has been used widely, particularly in the United States.
- The Tajima modification buries a single knot in the centre of the tendon. The Strickland modification uses a separate suture in each tendon end and buries two knots. These repairs were mostly made with a 3/0 or 4/0 monofilament polypropylene or braided polyester suture material, with both materials being of adequate strength and each having relative benefits. Both remain the commonly used materials.

Silfverskiöld KL, May EJ. Flexor tendon

repair in zone II with a new suture technique and an early mobilization program combining passive and active flexion. J Hand Surg Am 1994;19:53-60

- The series reported by Sifverskiöld and May, in 1994, from Gothenburg in Sweden, has probably the best results reported from a civilian unit, to date, in the world. It actually combines features of Kleinert, Duran-Houser and Belfast mobilizations.

IFSSH Scientific Committee on Skin Coverage

Chair: Maurizio Calcagni (Switzerland)

COMMITTEE: ROBERTO ADANI (ITALY) / SYLVIE CARMES (FRANCE)
CHRISTIAN DUMONTIER (FRANCE) / DAVID ELLIOT (UNITED KINGDOM)
THOMAS GIESEN (SWITZERLAND)

REPORT SUBMITTED OCTOBER 2014

Skin coverage in hand reconstruction is a challenging and vast chapter in Hand Surgery and to cover every aspect of it in a report is simply not feasible. Therefore this report focuses on a few specific topics.

The coverage of anatomical districts like the fingertips is common ground for the Hand Surgeon worldwide, but in the last ten years different refinements have been published in order to optimize the reconstruction of this organ. Nevertheless, in many emergency departments the amputation of badly injured fingertips, including the thumb, remains the preferred treatment. The main focus of this report is to counter this tendency, providing alternatives to the surgeons. Large defects to the digits involving more than one segment, defects to the palm and to the dorsum of the hand are currently debated in international meetings. The use of skin substitutes vs. the use of extremely refined microsurgical procedures vs. classic island flaps is the basis of animated discussions, which are also influenced by cultural and socio economic factors

around the world. This report offers the views of six different surgeons from four different countries, in the hope of animating discussions and to suggest new approaches.

FINGERTIP RECONSTRUCTION: THE ROLE OF CONSERVATIVE TREATMENT

SYLVIE CARMES AND CHRISTIAN DUMONTIER, FRANCE

As fingertip injuries are by far the most frequent finger injuries, one could expect that guidelines now exist to help emergency doctors as well as specialists to choose between treatment options. This is not yet the case. Treatment options in literature vary from the simplest conservative treatment to the most sophisticated microsurgical reconstruction. Regarding conservative treatment, some questions still arise:

WHAT DOES CONSERVATIVE TREATMENT MEAN?

In most publications, conservative treatment means lavage and

debridement under local anaesthesia. Protrusive bone, if present, is removed by 2mm to 5mm under the level of soft-tissue. Dressings using paraffin tulle changed every two or three days has been extensively used with good results (Chow and How, 1982. Ipsen et al., 1987). However as the authors had often experienced difficulty in removing such dressings, which may damage the underlying granulation tissue, experiments have been made using bacitracine ointment (Lamon et al., 1983), Hyphecan (Hyphecan Care Limited, Kwai Chung, Hong Kong), polyurethane foam (Williamson et al., 1987), silver sulphadiazine (de Boer and Collinson, 1981; Riyat et al., 1997). In some series, dressing changes were made 2-4 times a day (Farrell et al., 1977).

As early as 1977 (Fox et al., 1977) occlusive dressings leaving a moist environment have also been proposed and Mennen (Mennen and Wiese, 1993) presented his experience in 1993 without debridement and the use of "Opsite" (Smith and Nephew Corporate, London, UK) changed only

every week. His technique and results have been reproduced by others in large series (Mühldorfer-Fodor et al, 2013). The idea behind it is that fluid and enzyme around the tip promote healing.

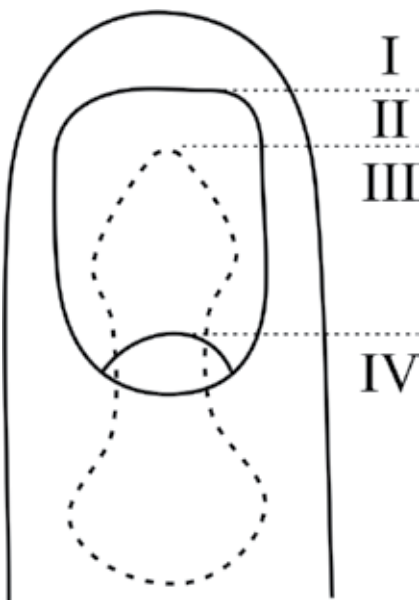
WHAT ARE THE EXPECTED RESULTS?

Results have been studied in a small series of 17 cases (Farrellet al, 1977) to a larger series of 200 cases (Mennen and Wiese, 1993; Muehldorfer et al, 2013) with 3 to 6 months follow-up. One series reporting 20 cases at 2 to 6 years follow-up showed similar results as those series with a shorter follow-up. Some of these series were prospective (Chow and How 1982; Ipsen et al, 1987, Williamson et al, 1987). Healing time took 3 to 5 weeks on average with extremes between 2 to 12 weeks, with larger injuries and exposed bone taking a longer time to heal than less severe injuries. According to the dressing protocol 3 to 29 dressing changes were necessary. Accordingly return to work took from 2 to 60 days with an average of 20 days. Most series reported no infection. Only in Lee's series (3%) and Lamon's (8%) were minor infections reported. Pulp sensitivity was considered normal in 50% to 80% of patients. When measured, Weber's two point discrimination was increased by 1mm average in Ipsen's series, it was between 2.25mm and 4.1mm in Rylat's series, or double compared to normal (6mm vs 3mm) in Lamon's series. Results were considered good to excellent in 90% to 100% of cases. Authors insisted on the remodeled

"fingerprint" and barely visible scars, regular perspiration, and very limited disability. Pulp tenderness was present in about 20% of cases (Riyat et al, 1997; Ipsen et al, 1987) but was less frequent than with other methods. Pulp shortening or problems were few, while nail dystrophies were considered frequent, varying between 25% to 60% (Chow et al, 1982; Ipsen et al, 1987; Riyat et al, 1997). Only half of them were disabling. Nail dystrophies were reported in only 50% of cases if the injury is in the distal third of the sterile matrix (Chow et al, 1982).

WHICH TYPE OF CONSERVATIVE TREATMENT IS SUPERIOR TO THE OTHERS?

None has really proved superior. In Allen's type I and II injuries (Fig 1 - below), dressing change was less painful in the silver sulphadiazine group compared to Paraffin, while at 3 weeks the fingertip was more sensitive. Healing was faster in the paraffin group, but shrinkage and



shortening was also more evident (Riyat et al, 1997). It seems that occlusive dressing without initial debridement is simpler to use, results in more comfortable dressing, and dressing change. Occlusive dressings may result in less wound contraction and a more cosmetically acceptable outcome.

WHEN SHOULD CONSERVATIVE TREATMENT NOT BE USED?

This is the major question. Particular emphasis is placed on involvement of distal phalangeal bone and nail matrix. However there is a high disparity in the literature that comes from variation in the injuries themselves with respect to orientation, tissue quality, vascularity, and patient factors such as age, hand use and occupation, smoking history, and concurrent diseases. What is obvious is that, when compared to other treatment modalities, conservative treatment is always favourable. Results of conservative treatment were superior to other types of treatment including flaps, with less pain and stiffness, less disability, faster healing time and fewer complications in Chow's series of 200 cases. There were no differences in functional and aesthetic outcomes at one year follow up in Södeberg's series. When comparing 7 types of treatment, simple dressings gave excellent results in Ma's series (Ma et al, 1982). Recently, Van den Berg (Van den Berg et al, 2012) found that the outcome of treatment of Allen II, III, and IV fingertip injuries (Fig 1) was irrespective of the treatment chosen. From the literature it appears that bone exposure is not a major

TABLE 1: The PNB Classification for fingertip amputation

PULP	
0	No injury
1	Laceration
2	Crush
3	Loss-distal transverse
4	Loss-palmar oblique partial
5	Loss-dorsal oblique
6	Loss-lateral
7	Loss-complete
NAIL	
1	Sterile matrix laceration
2	Germinal + sterile matrix laceration
3	Crush
4	Proximal nailbed dislocation
5	Loss-distal third
6	Loss-distal two thirds
7	Loss-lateral
8	Loss-complete
BONE	
0	No injury
1	Tuft fracture
2	Comminuted non articular fracture
3	Articular fracture
4	Displaced basal fracture
5	Tip exposure
6	Loss-distal half
7	Loss-subtotal (tendon insertion intact)
8	Loss-complete

problem if the bone is not protruding. However, except for the most simple sterile nail matrix injuries, nail dystrophies will not be avoided with conservative treatment. Using Evans PNB classification (Table 1), Muneuchi (Muneuchi et al, 2005) found that the boundaries between surgical treatment and conservative treatment were PNB 386, 666 and 700.

DAVID ELLIOT, UK

Perhaps the single most important and useful technique of digital reconstruction is the exploitation of the astonishing ability of the skin of the digits to close defects of considerable size by a combination of wound contraction and re-epithelialisation to give a cosmetic and functional result which cannot be bettered by any surgical procedure. This ability is well recognised and exploited in the management of digital tip injuries (Allen 1980; Chow and Ho 1982; Lee et al 1995; Mennen and Wiese 1993). In a moist environment, in the absence of infection, this occurs relatively quickly, not only at the tips but also on the other aspects of the digits. Galen recognised this almost two millennia ago and, two millennia before Galen, the Smith papyrus describes several hundred means of achieving healing of skin wounds by covering them with mixtures of honey and animal fats in ancient Egypt. Skin grafting of all defects of the digits has been a particular feature of plastic surgical management of hand injuries during the last fifty years which is

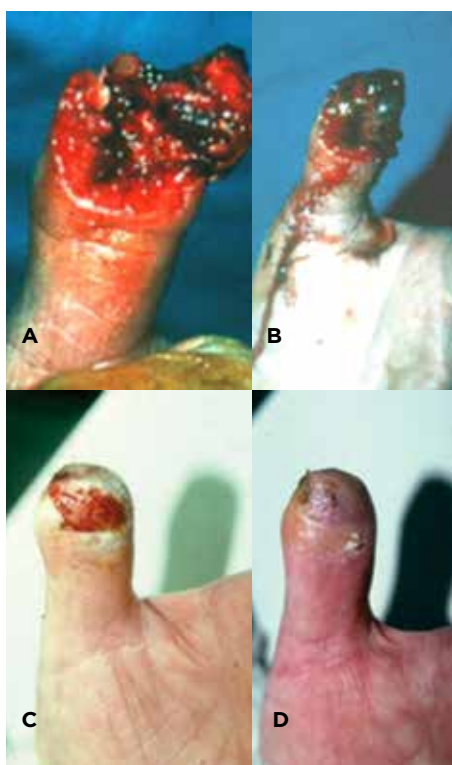often unnecessary and introduces further morbidity and delay of mobilisation. Healing open wounds under dressings avoids the creation of secondary donor sites and the patient can be encouraged to move if the bandaging is reduced to the minimum necessary to provide a moist environment for the raw area. The opportunity of dressing changes is used to encourage movement under water. This is both comfortable and helps debride the wounds. A further advantage of open wound management is that the oedema which is responsible for much of the long-term morbidity of digital injuries is not retained in the digit but leaks out of the open wound during early mobilisation. While the dogma of skin grafting has been dispelled for digital tip injuries without bone exposure, it is, unfortunately, still common practice in many hand surgery units to graft all skin defects of other parts of the digits. If skin can replace itself under moist antiseptic dressings, then operating to achieve skin cover, per se, is a dubious indication for surgery. However, we do require well-vascularised subcutaneous soft tissue to provide adequate protection of the bone at the digital tip, if exposed. With slight bone exposure, the bone may be nibbled back until it is covered by subcutaneous pulp tissue. The skin wound is then healed by secondary intention under moist antiseptic dressings. In doing this, we have accepted very slight digital

shortening in exchange for a simple plan of management. In most other circumstances, we are committed to moving flaps. In a ragged injury with significant bone exposure, there may be lengths of soft tissues adjacent to the amputation stump which are adequately vascularised and of sufficient size to provide bone cover: these "opportunistic flaps" can be used to convert the tip into a skin wound which can be healed by dressings (Fig 2). Where such opportunity for simple reconstruction of the digital tip does not exist, finger length can be maintained at that of the amputation by the use of flap reconstruction of the stump. Homodigital reconstruction involves rearrangement of the soft tissues of the injured digit to achieve healing without seeking tissue for reconstruction from outside that digit (Mouchet and Gilbert, 1982; Schiund et al., 1985; Foucher et al., 1989). While this concept of reconstruction has definite advantages of reconstructing 'like with like' and avoiding further scarring and morbidity elsewhere on the hand or body, the availability of donor tissue within an injured digit is obviously limited. Many of the injuries for which homodigital advancement flaps are used are palmar oblique with the amputation removing both skin and subcutaneous soft tissue distally to expose the bone but removing only skin proximally. We do not excise the pulp which is denuded

of skin cover but use it as the leading edge of the advancement flap(s), so lengthening the flap and reducing the extent to which it must be advanced. This technique does not allow direct skin to nail approximation but achieves cover of the distal bone with soft tissue. The digital tip is, thus, converted into an injury which can be epithelialised under dressings. A secondary benefit of this method of advancing homodigital flaps is that the process of epithelialisation helps to round off the digital tips and improves their final appearance.

FINGERTIP RECONSTRUCTION:

Figure 2: (A,B) Thumb primarily closed with opportunistic flap leaving a large raw area with no bone exposure. (C,D) Healing following daily moist dressing change



THE TRAUMATIC NAIL COMPLEX SYLVIE CARMES AND CHRISTIAN DUMONTIER, FRANCE

In this short report, we will only focus on acute nail complex injuries and will not discuss reconstruction or the treatment of associated phalangeal fractures.

Since the publications of Zook and Shepard in the 80's (Zook, 1981; Shepard, 1983), few publications have been presented regarding the high frequency of nail complex trauma. Most of them are technical tips that improve both the safety of the treatment and the quality of the functional as well as aesthetic results.

Nail traumas represent 8% of all finger injuries in adults and 5% to 6% of child trauma (Duthie and Adams, 1984; Guy, 1990; Ardouin et al, 1997). The middle finger and thumb are the digits most frequently involved. A crushing mechanism is the most frequent cause of the lesion. In one personal series of almost 200 cases (Carmès et al. under submission), surgical exploration found: 47 isolated lesions of the nail plate (25%), 103 nail bed lesions (55%), 14 matrix (+/- bed) lesions and 23 nail bed hematomas (12.3%). In 134 cases (71.65%) there was an associated lesion: of the pulp in 50 cases (26.7%), of the distal phalanx in 29 cases (15.5%), an associated pulp and phalangeal lesion in 49 cases (26.2%) and another lesion of the finger or hand in 22 cases (11.8%). The associated lesion was on the

same finger in 128 cases.

SHOULD ALL NAIL TRAUMA BE TREATED?

Nail complex and fingertip injuries are frequently associated. Although conservative treatment usually gives good results for pulp injuries, nail dystrophies are always present (up to 60% of cases) except for the most minor injuries involving less than a third of the distal nail bed (Chow, 1982; Ipsen, 1987). Only half of them were disabling. We believe that nail injuries should be treated as a separate entity, whatever the treatment of associated lesions may be, as inadequate treatment may lead to severe disabling sequelae while early treatment usually gives good to excellent results (Ardouin et al, 1997; Inglefield et al., 1995; Shepard, 1990).

NAIL PLATE INJURIES

Nail plate injuries are the less severe lesions and one should ask whether or not the nail plate should be replaced. O'Shaughnessy et al. found no difference whether or not the nail plate was replaced (O'Shaughnessy, 1990), however Zook recommended replacement and found that its non-replacement gave less satisfactory results (Zook et al., 1984). Recently, nail replacement in paediatric cases has been challenged and Miranda (2013) considered its replacement as more detrimental than absence of nail plate or substitute. We use sutures that do not pass through the nail complex but only pass through the

lateral side of the pulp. Others do not fix the nail plate anymore and have found that the plate quickly adheres to the nail bed and will stay in place if the dressing is changed carefully. (Tos, 2012).

If one chooses to replace the nail plate when absent or destroyed, among the many substitutes that have been proposed, we use, as do others (Tos et al., 2009), the bubble trap (reservoir) of a perfusion set, as the natural curvature is adapted to most nails. This substitute is sterile, inexpensive, and easily available in emergency and elective operating theatres. A small hole in its proximal part is made to allow for drainage.

NAIL HAEMATOMAS

There are many discussions about the best treatment option for subungual nail haematomas (Mignemi et al., 2013). Only large subungual haematomas present with lesions that are amenable to repair (Simon and Wolgin, 1987) but surgical exploration is still questionable (Seaberg et al., 1991). We have chosen to explore those patients whose subungual hematomas were over 50% of the surface of the nail plate; this is a current trend today as the quality of nail edges is regarded as more important than the percentage of hematoma (Sommer and Brown, 2011).

Nail bed and/or matrix wounds Zook (1981; 1984) and Shepard (1983, 1990) emphasized the need

for meticulous repair using loops and small sutures (6/0 or under). To get access to the underlying tissue, removal of the nail plate is mandatory. Partial removal can be done for nail tumor surgery but is not indicated in trauma cases. To get access to the nail matrix, surgical incision at the junction of the proximal and lateral nail wall, as described by Kanavel, is necessary. One of the incisions can be prolonged over the second phalanx if a rotation-advancement flap is needed to reconstruct the proximal nail wall. Large debridement is not necessary due to the good vascularization of the tissues and approximation sutures are all that is needed as the nail bed or matrix do not glide over the distal phalanx. All nail bed/matrix fragments are preserved and replaced as free grafts in order to attain an optimal final result. Any irregularities of the wound edges of the nail bed or matrix should be avoided. We believe that moulding the repair using the nail plate or a substitute is a useful adjunct. We have no experience with the use of cyanoacrylate for the repair of nail bed wounds.

NAIL FOLD RECONSTRUCTION

Nail fold integrity is needed in order to have a normal nail shape. Reconstruction is made using local flaps, most of them being designed for burn injuries.

However in distal finger amputation, the nail is shortened and this is sometimes badly

tolerated from an aesthetic point of view. This is why Bakhach (1998) proposed a proximal-sliding eponychial flap to lengthen the visible portion of the nail plate. Merlino et al. (2011) reported 28 cases with a little technical modification. Chinese authors reported over 300 cases by simply resecting the distal free edge of the eponychium (proximal wall) (Wang and Yuan, 2012). Whatever the technique chosen, aesthetically it is worthwhile lengthening the visible part of the nail plate in distal transverse amputations of the fingertip that are unsuitable for replantation.

LOSS OF SUBSTANCE OF NAIL BED / MATRIX

These are more severe injuries and according to Shepard (1983, 1990), nail bed loss should be treated with split-thickness nail bed grafts, taken either from the same finger (rarely possible in our experience) or the great toe (which leaves about 25% of patients with some nail dystrophies). Sometimes a bank finger, when the injured finger is not available for replantation, may be used as a donor site.

However, nail bed replacement has been challenged by Ogo (1987) and Ogunro (Ogunro, 1989, Ogunro and Ogunro, 2007) who believe that a nail plate substitute may instigate spontaneous healing. It is likely that small losses of substance do not need grafting, however we do still consider nail bed grafting for loss of substance of at least one-

third of the nail bed. However, Lemperle (Lemperle et al., 2003) used the potential "regeneration process of the nail" in 11 patients and reported satisfactory results. For distal loss of substance of the nail bed, we described with Foucher a distally de-epidermised VY volar flap to "graft" the distal loss of substance of the nail bed (Dumontier et al., 1992). We still use this technique as it is simple and easy to perform and the results justify trying it. Nail matrix loss of substance will lead to the most dystrophic nails, especially if the eponychium is injured. Translation flaps (Schernberg and Ameil, 1987) may be used in the most severe cases, but with average results at most. We have no experience with nail matrix graft done in emergency except with the use of a bank finger. For a matrix graft, full-thickness graft is necessary.

FINGERTIP RECONSTRUCTION: FLAP RECONSTRUCTION

DAVID ELLIOT, UK

The Neurovascular Tranquilli-Leali

The type of flap reconstruction which is appropriate for digital tip reconstruction depends on the extent and configuration of the tip loss. In those amputations which are oblique, the direction and degree of obliquity are also of significance in our choice of flaps. In transverse amputations beyond the mid-nail level and dorsal oblique amputations beyond the

proximal nail fold, a Tranquilli-Leali or Atasoy flap works well (Tranquilli-Leali 1935; Atasoy et al 1970). The flap remains vascularised through small vessels, beyond the trifurcations of the digital arteries, within the subcutaneous pulp tissue lateral to the body of the flap. This flap can achieve the slight advancement needed to suture the skin to the nail in such cases. However, with greater losses of finger length and in palmar oblique injuries, even at this level, this flap is too small and cannot advance sufficiently to create a well-rounded digital tip with adequate bone cover.

In those palmar and sagittal oblique fingertip amputations which have a slope of 30 degrees, or less, we use a variant of the Tranquilli-Leali flap which we have called the "Neurovascular Tranquilli-Leali" flap (Elliot et al., 1995). This flap has the same shape as the original flap but is larger, extending to, or across, the DIP joint crease proximally. It is islanded on both neurovascular pedicles. The incisions of the V cross the distal interphalangeal joint crease at an angle and thus do not cause contractures. When designing the flap one takes the V incisions out almost to the lateral nail folds distally. Having made the flap wide, the leading edge of the flap after advancement is wider than the original fingertip. Unless the lateral corners of the flap are excised, this results in an ugly broad end to the digit. Cutting off the lateral corners and allowing

the resulting raw edges and tip to epithelialize not only narrows the digital tip but also rounds it to achieve a good appearance. Many of the injuries for which these advancement flaps are being used are palmar oblique with the amputation removing both skin and subcutaneous soft tissue distally to expose the bone but removing only skin proximally. We do not excise the pulp which is denuded of skin cover but use it as the leading edge of the advancement flap(s), so lengthening the flap and reducing the extent to which it must be advanced. This technique does not allow direct skin to nail approximation but achieves cover of the distal bone with soft tissue. The digital tip is, thus, converted into an injury which can be epithelialised under dressings. A secondary benefit of this method of using advancement flaps is that the process of epithelialisation helps to round off the digital tips and improves their final appearance. Although all of the advancement flaps we use are designed as a 'V' at their proximal extremity and were conceived to close proximally as a 'Y' after the flap has moved distally, the proximal donor defects are usually left open to close under dressings as closing the vertical limb of the 'Y' tightens the finger proximal to the vascular pedicles of the flaps. Generally, even in very distal amputations of suitable shape, the bipedicle Tranquilli-Leali or Atasoy flap does not work well on the

“The use of skin substitutes vs. the use of extremely refined microsurgical procedures vs. classic island flaps is the basis of animated discussions, which are also influenced by cultural and socio economic factors around the world.

thumb because of the inflexibility of the subcutaneous soft tissues. The neurovascular Tranquilli-Leali flap also moves less freely than on a finger, partly because of the fibrous nature of the subcutaneous tissues of the thumb and partly because of what has been described as the 'vertical dimension' of the thumb, that is its palmar-dorsal width at

the tip (Gaul, 1987). On fingers, it can be used to reconstruct defects with a palmar slope of up to 30 degrees; on the thumb it can only reconstruct defects with bone exposure which are dorsally facing, transverse or palmar facing with less than 10 degrees of slope. This flap can be used for stump reconstruction of any length of amputated finger or thumb and we find this version of the Tranquilli-Leali flap much more useful than the original.

For more sloping palmar oblique defects, we use two alternatives. To reconstruct the thumb tip, we use O'Brien's modification of the bipedicle Moberg flap (Moberg, 1964; O'Brien, 1968) with the addition of a 'V' tail proximally instead of a skin graft (Elliot and Wilson, 1993). There is no danger in raising Moberg-type flaps on the thumb, as the dorsal skin of the thumb has a separate blood supply. However, on the fingers, there is a risk of loss of the dorsal skin if the lateral incisions of the palmar flap cut the dorsal branches of the digital arteries feeding the dorsal skin (Snow, 1967). More recently, this flap has been re-described by Kojima et al (1994) but preserving the dorsal arterial branches, so making it safe for use in the fingers. For more sloping palmar oblique defects of the fingertip, we use the single pedicle, an extended version of the Segmüller flap (Segmüller, 1976) or the Venkataswami flap (Venkataswami and Subramanian, 2000).

THE SEGMÜLLER FLAP

Homodigital advancement flaps are of particular value in respect of their ability to replace the missing fingertip after amputation with similar and innervated soft tissues, while retaining digital length at, or near to, that of the level of amputation. The lateral V-Y flap, based on the small vessels of the distal digital pulp tissue, was first described as a unilateral flap by Geissendörfer (1943) and, later, used as bilateral flaps by Kutler (1947) and others. The Geissendorfer/Kutler flap was designed as a triangle on the lateral aspect of the distal segment of the finger with the apex of the triangle proximal and the flap raised on the microcirculation of the subcutaneous pulp tissue beyond the trifurcation of the neurovascular bundle. It continues to be described in most textbooks and continues to disappoint with its failure to advance as much as shown in line drawings. The minor modification described by Shephard (1983) is only a little better. A larger, but less well known, lateral V-Y flap, with the apex taken back to the DIP joint crease and islanded on the neurovascular bundle was first described in Switzerland by Segmüller (Segmüller, 1976) and again, independently in South Africa, by Biddulph (1979). This flap is more useful, being more mobile and capable of greater advancement. However, these flaps remain confined to the

terminal segment of the finger, so still have limited potential for advancement. Lanzetta et al (1995) reported the use of longer Segmüller flaps in 5 cases with good results. Independently, over the same period, we also developed flaps based on the Segmüller principle, but extending proximally into the middle and, even, into the proximal segment of the digit, to achieve larger flaps which are capable of greater advancement and, so, greater versatility (Smith and Elliot, 2000). The extended version of the flap is of particular use in the treatment of extensive volar-sloping defects of the tips of the digits for which the shorter bipedicle flaps are not appropriate. The latter paper analyses the results of 100 such fingertips reconstructed with the extended flap. Foucher and his colleagues analysed a similar number of flaps of this kind but raised without the V-Y tail, with skin graft reconstruction of the proximal donor defect, with similar results (Schiund et al., 1985; Foucher and al., 1989).

The extended version of the Segmüller flap involves the use of a larger triangular flap, also raised as an island on the neurovascular pedicle, but with the apex of the flap at the PIP crease. The base of the flap is the proximal margin of the tip defect and the lateral boundary is the mid-lateral line of the finger. The third side of the flap is marked to join the flap apex (proximally) to the base of the flap

in the mid-line of the finger. The flap extends only to the midline of the finger and differs in this respect from a Venkataswami flap ((Venkataswami and Subramanian, 2000), which is taken right across the volar aspect of the finger to the other mid-lateral line and, at least theoretically, has no innervation distally on the side opposite the neurovascular bundle on which it is raised.

Because of the volar sloping nature of the tip injuries for which these flaps are commonly used, the proximal edge of the tip defect often includes several millimetres of subcutaneous tissue without skin. This is included in the flap to increase its length and reduce the distance by which it must be advanced to the end of the digit, with the consequence that the bone at the tip of the finger may only be covered by denuded pulp tissue after flap advancement and not by pulp and skin. When this is the case, the tip is treated with moist antiseptic dressings for several weeks until re-epithelialisation completes tip cover.

The flap is raised from distal to proximal, starting from the lateral corner of the base of the flap. The skin incision begins down the mid-lateral line and dissection is continued medially and proximally in the plane immediately superficial to the periosteum laterally and the tendon sheath more medially. Using this approach, the digital artery on the dorsal surface of the neurovascular

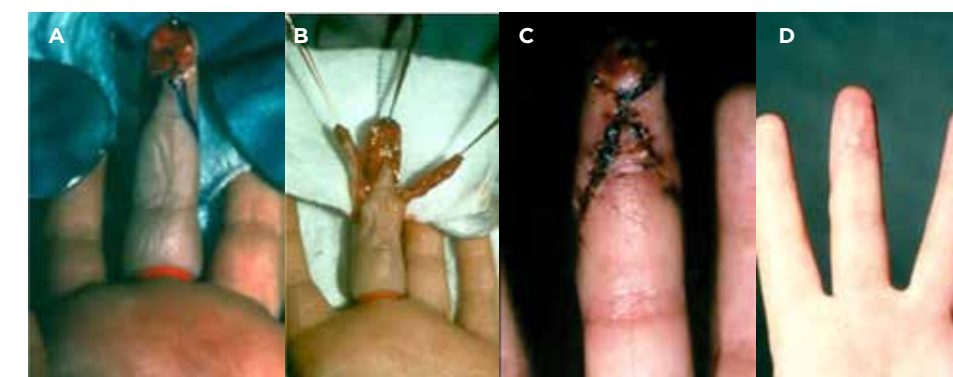
bundle is immediately identified from its deep surface on the underside of the flap and, thereafter, protected. All of the fibrous septa which connect the dermis to the periosteum and tendon sheath and the vessels feeding the vinculae of the flexor tendons at both interphalangeal joints are divided. The sloping medial side of the flap is incised through skin and those fibres immediately deep to the dermis are also divided to mobilise the flap. The most difficult part of the dissection is at its apex, at the PIP joint level, as the neurovascular bundle is directly deep to the meeting point of the lateral and medial incisions, and tethered by the branch of the artery running medially to feed the vincula of the flexor tendons, with little room for scalpel error without damaging the pedicle of the flap. It is safer to extend the lateral midline incision proximally down the proximal phalangeal segment of the finger, find the neurovascular bundle proximal to the apex of the flap, then follow the bundle distally to the apex of the flap at the PIP joint crease. It is necessary to completely island the flap on the neurovascular pedicle with a cuff of fat around the palmar surface of the artery and nerve to maintain venous drainage. When the neurovascular bundle is divided from its medial feeding branch to the vincula of the flexor tendons, the flap will be felt to 'jump' up to a centimetre distally. The flap is then advanced without tension and loosely sutured to cover

the bone of the digit tip. Commonly, part of the mid-lateral margin of the flap is left unsutured to avoid tension from post-operative oedema. This wound subsequently heals by secondary epithelialisation under moist antiseptic dressings. A single flap is usually raised on the blind side of the finger, unless the particular shape of the tip defect determines otherwise. In some injuries, a single flap provides sufficient tissue to reconstruct the digital tip but, in others, two flaps are necessary and a second flap is raised on the other neurovascular bundle and advanced (Fig 3). The finger is splinted dorsally with the PIP joint slightly flexed for the first 72 hours to take tension off the pedicle. However, this position is not maintained beyond this length of time as there is a risk of volar plate contracture of the PIP joint following use of all of the longer advancement flaps. After 72 hours, specific measures are taken by the therapists to avoid this, extension exercises and/or splinting sometimes being necessary for

several weeks or, occasionally, months.

Commendable features of the extended Segmüller flap are its versatility, ease of use and reliability. It is a single stage reconstruction which borrows from no other part than the already injured recipient digit. While requiring careful technique, it requires no microsurgical expertise and is well within the capabilities of most hand surgeons. It can be used to treat digital tip defects of variable size, shape and slope. The flap is suitable for any transverse or oblique loss of the distal segment, however steeply sloping the latter, with the length of the flap being tailored to the size of the tissue loss. Where one flap provides insufficient tissue bulk at the tip after advancement, a second can be brought into use. Like all homodigital flaps, this flap is useful in multidigital injuries in which adjacent digits are not available as a source of flaps. It can also be moved dorsally to reconstruct

Figure 3: (A) Volar oblique amputation of the index finger. (B,C) Coverage with a double Segmüller. (D) Final result at 3 months



nailbed loss or, in combination with other flaps, for more complex reconstruction of combined tip and dorsal injuries.

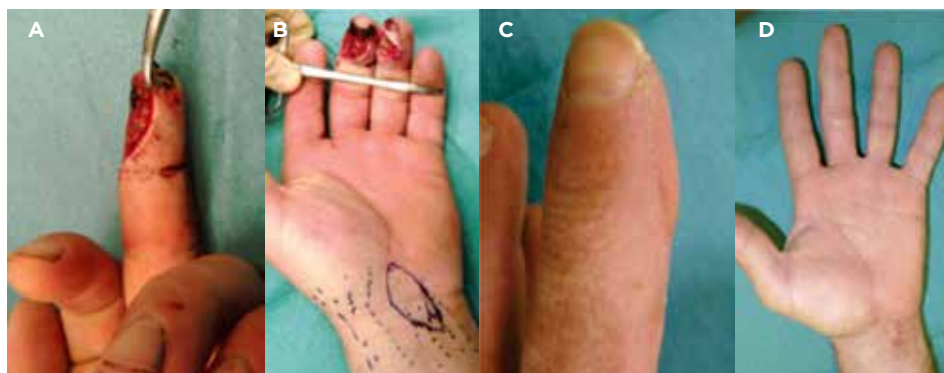THOMAS GIESEN, MAURIZIO CALCAGNI, SWITZERLAND
The role of perforator flaps and free flaps for the reconstruction of fingertips.

Recent publications have widened the choice of flaps in fingertip reconstruction, raising the technical difficulty of surgical reconstruction with the aim of lowering the local morbidity related to local flaps and at the same time to improve the quality of reconstruction.

Koshima et al., recently published the use of perforator flaps to reconstruct the tip of the finger (Koshima et al., 2006; Mitsunaga et al., 2010). These flaps are based on the small perforator arteries rising from the digital artery at the middle phalanx level, allowing the coverage of the fingertip without the need to sacrifice a digital artery as in homodigital reverse flaps. In our practice these flaps have not so far found any practical application, as for the classic local flaps, the Venkataswami flap or the Segmuller flap, which offer, with a simpler technique, an equivalent skin quality that is, in contrast, immediately sensate. In our opinion there is no relevant difference in the donor site and the latter flaps are technically less demanding. The use of free flaps for reconstruction of the fingertip

has, in our practice, very limited indications. We normally return to these flaps in acute traumatic cases of volar oblique amputations if there is a major contraindication or the impossibility of using an adjacent digit. Our indication for free flaps is if there is the need to reconstruct pulp in a "cold" situation where the soft tissue cover of the fingertip is insufficient and the other digits are intact. In those situations our first choice is a free venous flap harvested from the palmar aspect of the wrist, including skin from the thenar eminence or hypothenar eminence and the terminal branches of the lateral or medial cutaneous nerve of the forearm. We take two parallel veins from the proximal margin of the flap, using one of them as an afferent vessel anastomosed to a digital artery and one of them as a draining vein anastomosed preferentially to a volar vein of the digit, if available (Fig 4).

Figure 4: (A) Burr Injury to the radial side of a dominant middle finger. (B) Cover with a retrograde free venous flap from the volar aspect of the wrist including some glabrous skin from the hypothenar eminence. (C,D) Result at 3 months with donor site



The skin of these flaps is similar to the skin of the pulp and the harvesting of these flaps is technically easy.

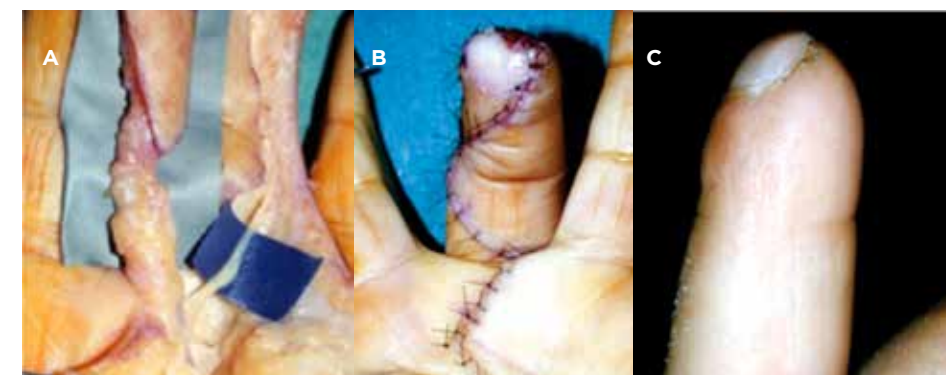We have very limited experience of the use of free thenar flaps and their modifications (Yang et al., 2010) based on the palmar branch of the radial artery and including terminal branches of the cutaneous nerves of the distal forearm and of the proximal hand. The reliability of these flaps was questionable and the harvesting more demanding; therefore we abandoned this technique.

In cases of small defects to the pulp we prefer the hemipulp free flap from the second toe (Kimura and Saito, 2006). In cases of composite defects including bone we prefer composite flaps from the great toe.

LARGE DEFECTS TO THE DIGITS
ROBERTO ADANI, ITALY
Refinements of the heterodigital island flap

The heterodigital flap comes from the standard cross-finger flap (Gourdin and Pangman, 1950), which is considered a random pattern regional flap employing the dorsal skin of an adjacent finger to provide soft tissue coverage to resurface a volar finger defect including pulp loss. To achieve recovery of sensitivity, the dorsal digital nerves (one or both) are included and sutured to the digital nerves of the injured finger (Lassner et al., 2002; Shao et al., 2009). There are two main disadvantages related to this technique: it is a two-stage procedure, and it requires finger immobilisation for up to three weeks. The heterodigital arterialized flap represents an evolution of the above methods: it is transferred from the lateral surface of a nearby digit including only the digital artery without the digital nerve. To reduce donor site morbidity the flap is harvested from the lateral side of the middle phalanx with the vascular pedicle located on the palmar side of the flap (Hirase et al., 1992; Leupin et al., 1997). The cosmetic result of the grafted donor area is more acceptable because the defect is over the midlateral line without affecting the palmar aspect of the finger. Moreover the dorsal branch of the digital nerve raising from the main nerve at this level can be used to innervate the flap with

Figure 5: (A) Heterodigital Flap based on the radial digital artery of the ring finger. (B) Coverage of a two segment defect to the middle finger and (C) final result.



acceptable sensory recovery (Adani et al., 2010).

With large skin digital pulp defects of the middle finger it is not always easy to resurface the pulp without extending the distal incision of the flap over the DIP joint crease on the donor finger. This may damage the function and the cosmetic appearance of the donor finger pulp. The heterodigital island flap with reverse-flow vascularisation (Adani et al., 1999; Adani et al., 2005) may answer such a problem. With this flap the pedicle is isolated up to its bifurcation in the palm and the common digital artery between the injured finger and the flap-donor finger is ligated just before its bifurcation. The Y-like vascular bifurcation then turns into a V shape and the two converging branches of the digital arteries become a single vascular pedicle for the flap, increasing its original length. The vascularization is supplied by a reversed flow through the proximal transverse digital palmar arch of the injured finger allowing the flap to cover the

defect completely. The heterodigital flap achieves acceptable sensory recovery: the mean static two-point discrimination test (s2PD) over the reconstructed pulp is about 9mm and the mean dynamic two-point discrimination test (m2PD) 7mm (Adani et al., 1999; Adani et al., 2005). These results are very similar to those reported by other authors (Hirase et al., 1992; Leupin et al., 1997) using the same donor area. No sensory deficit was reported in the donor fingers with the direct and the reverse heterodigital pedicle flaps.

The heterodigital neurovascular island flap is indicated for large losses of finger pulp when a direct island flap could be too small to cover the defect and represents a suitable option instead of the reverse homodigital island flap or free flaps (Fig 5). The reverse-flow type may be employed for large loss of pulp to the index and middle finger. This procedure is not recommended in cases of severe crushing injury involving multiple finger pulp losses because of the

possible damage to the vascular network including the proximal or middle transverse digital palmar arches.

THOMAS GIESEN AND MAURIZIO CALCAGNI, ITALY

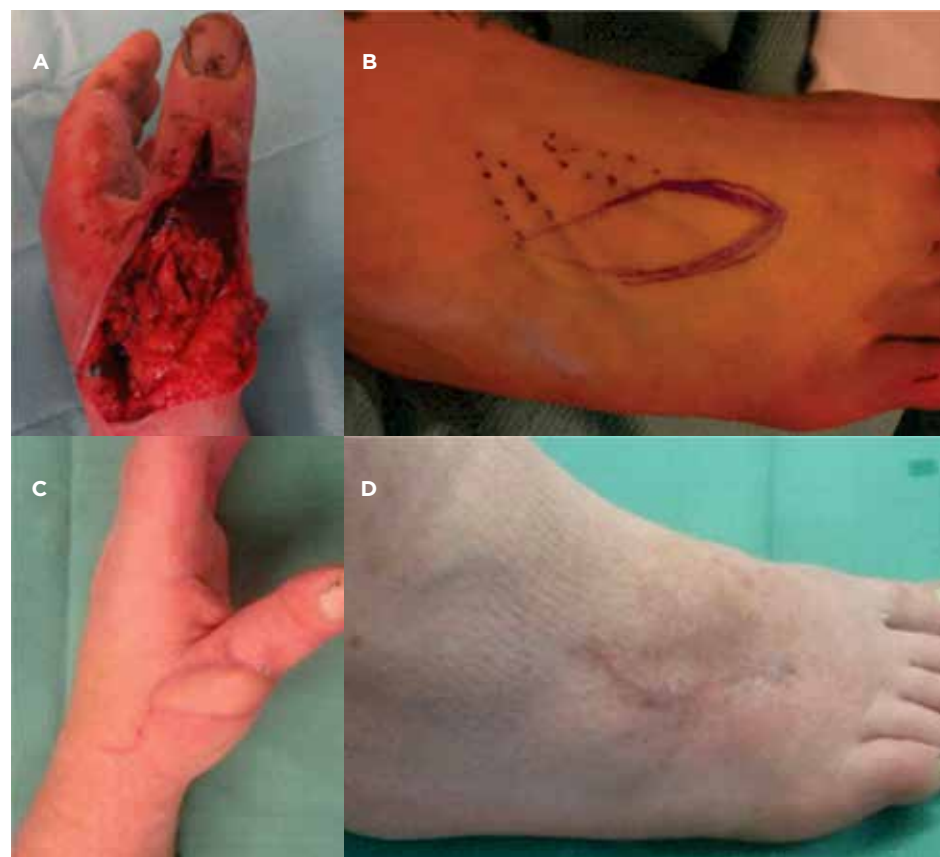Retrograde arterialized free venous flaps

Although the literature is encouraging with regard to the survival rate of arterialized free venous flaps, previously reported difficulty in healing owing to early venous congestion and subsequent epidermolysis has prevented their widespread application.

Recent papers from Lin et al and from the authors of this section (Lin et al., 2010; Giesen et al., 2014) have demonstrated that if a shunt situation between the arterial and venous system created by the flap is avoided by the means of a valve (retrograde arterial flow against the valves) or a ligature, these flaps are more predictable and might become a first line choice in hand reconstruction.

In two segment defects of the digits, the choice of local flaps might be limited to the Quaba flap with the modification illustrated by Vuppapapati (Vuppapapati et al., 2004), large heterodigital flaps or distant flaps from the forearm and the groin. These options might not fit a complex traumatic situation or a specific anatomic area such as the ulnar side of the little finger, and might leave long scars to the forearm or force the patient into a

Figure 6: (A) two segment defect to the P1 and distal metacarpal of the dorsum of a replanted thumb. (B) Plan of a retrograde free venous flap from the dorsum of the foot in a obese patient. (C) Result at three months and (D) donor site at three months.



cumbersome immobilized position. Free venous flaps offer different advantages in terms of a pliable and thin skin that fits easily around the contours of the hand. They are easy to harvest and because they are usually taken from the same forearm under tourniquet, the harvesting time takes, in our experience, around 30 minutes. The donor site morbidity is reduced when compared to forearm island flaps as the scar is only as big as the dimension of the flap without the need to expose or sacrifice any arterial vessel. They can be harvested as composite flaps

including nerves and tendons for more complex reconstruction and, as reported in the fingertip section, they can include glabrous skin from the thenar or hypothenar eminence.

In our department we use the retrograde technique for arterialized free venous flaps, with the arterial flow running against the valves. With this choice the feeding vessel and the draining vessel are left on the same side of the flap, facilitating anastomoses. The position of the flap that is going to be harvested on the forearm is influenced mainly by the criteria

of calibre matching the recipient artery and veins: for large defects of the digits we normally use the common digital artery of the fingers or the dorsal branch of the radial artery after its division into two branches between the dorsal aspect of the base of the 1st and 2nd metacarpal bones. To match this calibre the flap is harvested from the middle third of the forearm. The position of the flap might also be influenced by the need to harvest a composite flap with tendons, usually the palmaris longus or the flexor carpi radialis, and nerves, usually the lateral cutaneous nerve of the forearm. The presence of hair is one more factor influencing the harvesting site.

The flap is harvested by incising the skin on the outside of the line obtained with the defect template in order to obtain a slightly larger flap than required. This technical step is due to the postoperative swelling we observed occurring in the first 48 hours, as already pointed out by Woo et al in 2007. We usually wash the vein that is going to be arterialized with heparin-saline solution prior to anastomosis in order to exclude the presence of a valve in the pedicle before it enters the flap. For the same reason we normally take the cuff of fat tissue from around the vessels. After the arterial anastomosis, if a shunt situation is observed and the chosen draining vein is pulsating, we now look for the communicating branch between the feeding and the

draining vessel and ligate it with a clip, as described by Lin (Lin et al., 2010).

In the literature, several papers have been published recently with refinements in this technique and the use of different donor sites like the dorsum of the foot (Fig 6) (Yu et al., 2012), introducing the idea of the possibility for these flaps to become routine procedures in hand reconstruction.

LARGE DEFECTS OF THE HAND

ROBERTO ADANI, ITALY

The role of the ALT in the coverage of large defects in the hand, the palm and the dorsum

Fasciocutaneous flaps are most frequently used to cover hand defects (Saint-Cyr and Gupta, 2007). Many factors should be considered when choosing a flap. The most significant are the cosmetic match of the skin surrounding the defect, the donor site morbidity and the simultaneous approach to wound debridement and flap harvesting (Scheker and Ahmed, 2007). In the last decade the anterolateral thigh flap has received considerable interest (Javaid and Cormack, 2003; Adani et al., 2005; Adani et al., 2006) from hand surgeons and represents a good alternative to other fasciocutaneous flaps. The anterolateral thigh flap shows several advantages: simultaneous flap elevation and preparation; shorter operative time; longer vascular pedicle (approximately 10cm long); larger skin paddle.

Despite its versatility, the anterolateral thigh flap has some potential drawbacks: the greatest concern has been variability of the perforators and flap reliability (Wang et al., 2005). Large clinical series show that almost all patients will have an adequate vessel for supplying the flap and Doppler examination can accurately identify the perforators preoperatively, planning the flap accurately. The flap should be thinned to approximately 3mm to 4mm by removing a considerable amount of fatty tissue before it is transferred onto the hand. This allows an optimal match between the donor tissue and the area to be reconstructed with the flap. Despite flap thinning, additional debulking could still be necessary to improve the final cosmetic result, particularly in Caucasian patients whose thigh characteristics differ from patients of Asian origin. Defects of the donor site smaller than 7cm - 8cm in width can be closed primarily without a skin graft. In this case the scar is less noticeable than with other flaps harvested from the arm or forearm. The donor site scars associated with skin grafts of larger defects may preclude its use, particularly in female patients. The ALT flap is recommended in very large defects of the dorsum of the hand and the wrist; if employed for palm reconstruction, it requires aggressive thinning and a secondary debulking to reach an acceptable appearance.

The current role of the forearm flap for reconstruction of the palm and dorsal hand

The radial forearm flap may be used to cover the dorsal aspect of the hand. The sacrifice of a major artery in an already traumatized hand and the donor site result, which is not always satisfactory, represent the major drawbacks of this surgical procedure. However if this flap can resurface medium-sized defects with direct closure of the donor site and without jeopardizing the vascularisation of the hand, this approach may still be useful in the armamentarium of hand surgeons. In our practice the radial forearm flap is mainly used with direct closure of the donor site avoiding the need for skin graft. These problems can be partially solved by the radial artery perforator flap used as either a fasciocutaneous flap or an adipofascial flap (Page and Chang, 2006; Ho and Chang, 2010; Saint-Cyr et al., 2010.) The retrograde radial fascia-fat forearm flap removes only the fascia and fat layers of the forearm tissue leaving the radial artery and the forearm skin intact. The perforator flaps show some disadvantages: the pedicle is relatively bulky after rotation, which makes direct closure dangerous, and their pivot point is located more proximally than in the traditional radial forearm flap making it difficult to extend and cover the distal dorsal aspect of the hand completely. For these reasons they can be used only to treat moderate-sized defects and

they should be considered very carefully in patients with complex hand injuries to the forearm with possible damage to the perforators of the radial artery. Another possibility is to divide the radial forearm flap into different sections, following the perforators, by using a long narrow flap which allows primary closure of the donor site (Mateev et al., 2009). The use of the radial forearm flap with large skin defects (more than 20cm²) is more restricted because of the poor donor site result. Attempts to minimize the donor site morbidity have been widely reported in literature using different types of skin grafts (Zuidam et al., 2005; Ito et al., 2005.), regional advancement flaps (Ahn et al., 2007; Lane et al., 2013) or special types of skin substitutes (Rowe et al., 2006; Murray et al., 2011). The radial forearm flap finds a specific indication for use for the thenar region because it provides thin and pliable skin; on the contrary, it is not ideal for the hypothenar and central region of the palm, where stability cannot be achieved with this type of flap.

REFERENCES

1. Adani R, Busa R, Scagni R, Mingione A. The heterodigital reversed flow neurovascular island flap for fingertip injuries. *J Hand Surg.* 1999, 24B: 431-6.
2. Adani R, Giesen T, Inguaggiato M. Heterodigital flaps for severe pulp defects. In TP Dubert Ed. Primary Care of Complex Injuries of the Hand

and Wrist. Kostantaras Medical Publications Athens, 2010, 317-22.

3. Adani R, Marcoccio I, Tarallo L, Fregni U. First web space reconstruction by the anterolateral thigh flap. *J Hand Surg Am.* 2006, 31A: 640-6.
4. Adani R, Marcoccio I, Tarallo L, Fregni U. The reverse heterodigital neurovascular island flap for digital pulp reconstruction. *Tech Hand Up Extrem Surg.* 2005, 9: 91-5.
5. Adani R, Tarallo L, Marcoccio I, Cipriani R, Gelati C, Innocenti M. Hand reconstruction using the thin anterolateral thigh flap. *Plast Reconstr Surg.* 2005, 116: 467-73.
6. Ahn HC, Choi MS, Hwang WJ, Sung KY. The transverse radial artery forearm flap. *Plast Reconstr Surg.* 2007, 119: 2153-60.
7. Allen MJ. Conservative management of finger tip injuries. *The Hand.* 1980, 12: 257-65.
8. Ardouin T, Poirier P, Rogez JM. Fingertips and nailed injuries in children. Apropos of 241 cases. *Rev Chir Orthop Reparatrice Appar Mot.* 1997, 83: 330-4.
9. Atasoy E, Ioakimidis E, Kasdan ML, Kutz JE, Kleinert HE. Reconstruction of the amputated finger tip with a triangular volar flap. *J Bone Joint Surg Am.* 1970, 52: 921-6.
10. Bakhach J. Eponychial flap. *Ann Chir Plast Esthet.* 1998, 43:

259-63.

11. Bickel KD, Dosanjh A. Fingertip Reconstruction. *J Hand Surg Am.* 2008, 33: 1417-9.
12. Biddulph SL. The neurovascular flap in finger tip injuries. *The Hand.* 1979, 1: 59-63.
13. Buckley SC, Scott S, Das K. Late review of the use of silver sulphadiazine dressings for the treatment of fingertip injuries. *Injury.* 2000, Jun 31: 301-4.
14. Chow SP, Ho E. Open treatment of fingertip injuries in adults. *J Hand Surg Am.* 1982, 7: 470-6.
15. Dumontier C, Tilquin B, Lenoble E, Foucher G. Reconstruction of distal loss of substance in the nail-bed by a de-epithelialized flap from the digital pulp. *Ann Chir Plast Esthet.* 1992, 37:553-9.
16. de Boer P, Collinson PO. The use of silver sulphadiazine occlusive dressings for fingertip injuries. *J Bone Joint Surg Br.* 1981, 63: 545-7.
17. Duthie G, Adams J. Meshed adhesive tape for the treatment of crushed fingers in children. *J Hand Surg Br.* 1984, 9: 41.
18. Elliot D, Moiemmen NS, Jigjinni VS. The neurovascular Tranquilli-Leali flap. *J Hand Surg Br.* 1995, 20: 815-23.
19. Elliot D, Wilson Y. V-Y advancement of the entire volar soft tissue of the thumb in distal reconstruction. *J Hand Surg Br.* 1993, 18: 399-402.
20. Farrell RG, Disher WA, Nesland RS, Palmatier TH, Truhler TD. Conservative management of fingertip amputations. *JACEP.* 1977, 6: 243-6.
21. Foucher G, Smith D, Pempinello C, Braun FM, Citron N. Homodigital neurovascular island flaps for digital pulp loss. *J Hand Surg Br.* 1989, 14: 204-8.
22. Fox JW 4th, Golden GT, Rodeheaver G, Edgerton MT, Edlich RF. Non-operative management of fingertip pulp amputation by occlusive dressings. *Am J Surg.* 1977, 133: 255-6.
23. Gaul JS. A palmar-hinged flap for reconstruction of traumatic thumb defects. *J Hand Surg Am.* 1987, 12: 415-421.
24. Geissendörfer H. Beitrag zur Fingerkuppenplastik. *Zentralbl Chir.* 1943, 70: 1107-8.
25. Giesen T, Forster N, Künzi W, Giovanoli P, Calcagni M. Retrograde arterialized free venous flaps for the reconstruction of the hand: review of 14 cases. *J Hand Surg Am.* 2014, 39: 511-23.
26. Gourdin M, Pangman WJ. The repair of surface defects of fingers by trans-digital flaps. *Plast Reconstr Surg.* 1950, 5: 368-71.
27. Guy RJ. The etiologies and mechanisms of nail bed injuries. *Hand Clin.* 1990, 6: 9-19.
28. Henry M. Specific complications associated with different types of intrinsic pedicle flaps of the hand. *J Reconstr Microsurg.* 2008, 24:221-5.
29. Hirase Y, Kojima T, Matsuura U. A versatile one-stage neurovascular flap for fingertip

reconstruction: the dorsal middle phalangeal finger flap. *Plast Reconstr Surg.* 1992, 90: 1009-15.

30. Ho A, Chang J. Radial artery perforator flap. *J Hand Surg Am.* 2010, 35: 308-11.
31. Inglefield CJ, D'Arcangelo M, Kolhe PS. Injuries to the nail bed in childhood. *J Hand Surg Br.* 1995, 20: 258-61.
32. Ipsen T, Frandsen PA, Barfred T. Conservative treatment of fingertip injuries. *Injury.* 1987, 18: 203-5.
33. Ito O, Igawa HH, Suzuki S, Muneuchi G, Kawazoe T, Saso Y et al. Evaluation of the donor site in patients who underwent reconstruction with a free radial forearm flap. *J Reconstr Microsurg.* 2005, 21: 113-7.
34. Javaid M, Cormack G. Anterolateral thigh free flap for complex soft-tissue hand reconstruction. *J Hand Surg Br.* 2003, 28:21-7
35. Kimura N, Saitoh M. Recovery of disused replanted digits by second toe hemipulp flap transfer. *Plast Reconstr Surg.* 2006, 117: 507-13.
36. Kojima T, Kinoshita Y, Hirase Y, Endo T, Hayashi H. Extended palmar advancement flap with V-Y closure for finger injuries. *British Journal of Plastic Surgery.* 1994, 47: 275-9.
37. Koshima I, Urushibara K, Fukuda N, Ohkochi M, Nagase T, Gonda K, Asato H, Yoshimura K. Digital artery perforator flaps for fingertip reconstructions.

- Plast Reconstr Surg. 2006, 118: 1579-84
38. Kutler W. A new method for finger tip amputation. JAMA. 1947, 133: 29-30.
 39. Lamon RP, Cicero JJ, Frascione RJ, Hass WF. Open treatment of fingertip amputations. Ann Emerg Med. 1983, 12: 358-60.
 40. Lane JC, Swan MC, Cassel OC. Closure of the radial forearm donor site using a local hatchet flap: analysis of 45 consecutive cases. Ann Plast Surg. 2013, 70: 308-12.
 41. Lanzetta M, Mastropasqua B, Chollet A, Brisebois N. Versatility of the homodigital triangular neurovascular island flap. J Hand Surg Br. 1995, 20: 824-9.
 42. Lassner F, Becker M, Berger A, Pallua N. Sensory reconstruction of the fingertip using the bilaterally innervated sensory cross-finger flap. Plast Reconstr Surg. 2002, 109: 988-93.
 43. Lee LP, Lau PY, Chan CW. A simple and efficient treatment for fingertip injuries. J Hand Surg Br. 1995, 20: 63-71.
 44. Leupin P, Weil J, Buchler U. The dorsal middle phalangeal finger flap. J Hand Surg Br. 1997, 22: 362-71.
 45. Lemperle G, Schwarz M, Lemperle SM. Nail regeneration by elongation of the partially destroyed nail bed. Plast Reconstr Surg. 2003, 111: 167-72.
 46. Lin YT, Henry SL, Lin CH, Lee HY, Lin WN, Lin CH, Wei FC. The shunt-restricted arterialized venous flap for hand/digit reconstruction: enhanced perfusion, decreased congestion, and improved reliability. J Trauma. 2010, 69: 399-404.
 47. Ma GFY, Cheng JCY, Chan KT, Chan KM, Leung PC. Fingertip injuries--a prospective study on seven methods of treatment on 200 cases. Ann Acad Med Singapore. 1982, 11: 207-13.
 48. Mateev M, Ogawa R, Trunov L, Moldobaeva N, Hyakusoku H. Shape-modified radial artery perforator flap method. Analysis of 112 cases. Plast Reconstr Surg. 2009, 123: 1533-43.
 49. Mennen U, Wiese A. Fingertip injuries management with semi-occlusive dressing. J Hand Surg Br. 1993, 18: 416-22.
 50. Merlino G, Carlucci S. A simple modification of the Bakhach's eponychial flap for nail lengthening after fingertip amputation. J Plast Reconstr Aesthet Surg. 2011, 64: e265-6.
 51. Mignemi ME, Unruh KP, Lee DH. Controversies in the treatment of nail bed injuries. J Hand Surg Am 2013, 38: 1427-30.
 52. Miranda BH, Vokshi I, Milroy CJ. Pediatric nailbed repair study: nail replacement increases morbidity. Plast Reconstr Surg. 2012, 129: 394e-6e. (Erratum in Plast Reconstr Surg. 2012, 129: 1028)
 53. Mitsunaga N, Mihara M, Koshima I, Gonda K, Takuya I, Kato H, Araki J, Yamamoto Y, Yuhei O, Todokoro T, Ishikawa S, Eri U, Mundinger GS. Digital artery perforator (DAP) flaps: modifications for fingertip and finger stump reconstruction. J Plast Reconstr Aesthet Surg. 2010, 63: 1312-7.
 54. Moberg E. Aspects of sensation in reconstructive surgery of the upper extremity. J Bone Joint Surg Am. 1964, 46: 817-25.
 55. Mouchet A, Gilbert A. Covering distal amputations of the finger using homodigital neurovascular island flaps. Ann Chir Main. 1982 1: 180-182.
 56. Mühldorfer-Fodor M, Hohendorff B, Vorderwinkler KP, van Schoonhov...

An evidence-based approach to conservative management of CMC OA

Anne Wajon, PhD

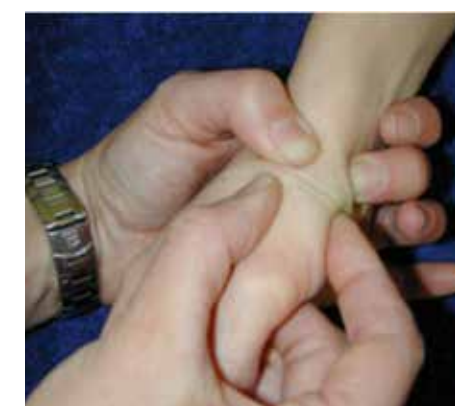Pain at the base of the thumb is particularly common in post-menopausal women in the fifth to seventh decades of life (Swigart, Eaton, Glickel, & Johnson, 1999). It is frequently located either at the palmar surface of the trapeziometacarpal joint, or more dorsally, between the base of the first and second metacarpals. The pain is most often aggravated by opening jars, writing, turning taps and sustained grip activities, however, in cases of more advanced arthritis, it can also result in a constant dull aching pain.

Radiographs may reveal joint space narrowing, sclerosis, articular debris and joint subluxation (Eaton & Glickel, 1987). Severe (stage IV) joint degeneration will be associated with scaphotrapezotrapezoidal (STT) joint involvement and these patients will often complain of wrist pain along with pain at the base of the thumb.

Careful palpation of the STT joint and trapezium, just distal to the scaphoid, will assist in determining the source

of symptoms (Skirven, 1996). Further, axial compression and rotation of the first metacarpal on a stabilized trapezium (the grind test: Figure 1) is a recommended maneuver for reproducing pain and crepitus at the joint (Skirven, 1996).

Figure 1: The Grind test



It is important to provide the patient with pain at the base of the thumb education regarding the disease, including the diagnosis, likely prognosis, specific objectives of treatment, self-management approaches and instruction in joint protection techniques. It is essential for the patient to become aware of the activities that aggravate their

symptoms, so they can understand the need to change their task performance by either using a different posture or technique, assistive devices or splints. By so doing, they will take some responsibility for alleviating their symptoms, and play an active role in their rehabilitation. Simple strategies include advice to:

- Use the strongest joint for the task
- Use two hands to hold a book or a stack of plates, to distribute the load
- Avoid prolonged static positions, such as holding a smart phone while texting with the other hand
- Alternate repetitive activities with rest breaks

Various assistive devices are available that assist patients perform ADL without aggravating their symptoms. They include jar openers, tap turners, large handled cutlery, large key holders, and wide grip vegetable peelers. By identifying aggravating activities, patients will be able to identify which of these assistive

devices could be useful in their day-to-day life.

Many patients find symptomatic relief with massage using Arnica or NSAIDs, and the regular use of thermal modalities. My recommendation for the patient who complains of morning stiffness is to gently squeeze a sponge in warm water on waking. Similarly, a hot pack at the end of the day can be helpful, although some people prefer to use cold after a period of overuse.

Figure 2: Neoprene thumb and wrist brace (eg Comfort Cool® from NCM)

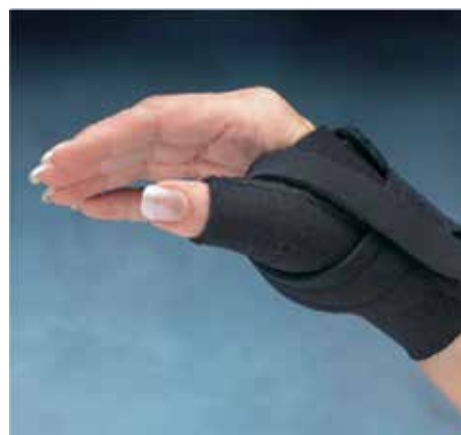
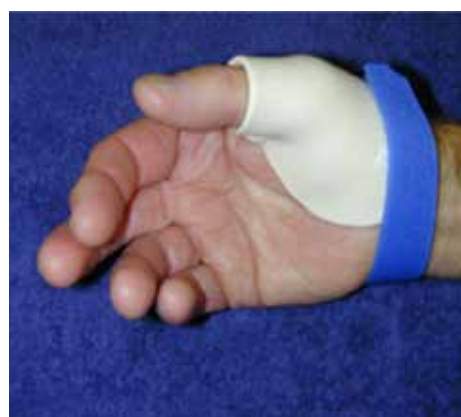
Figure 3: Short opponens splint



A variety of splinting options are available for patients with pain at the base of the thumb, however there is no

evidence to support the superiority of one over another (Wajon & Ada, 2005). Splints aim to relieve pain, prevent progression of deformity, reduce inflammation and provide support to allow improved function. In general, a more flexible neoprene style splint is appropriate for those with mild symptoms (Figure 2), and the rigid thermoplastic short opponens splint useful for those with more severe pain that limits most activities of daily living (Figure 3). The long opponens splint will be helpful for those with STT joint involvement as it supports the wrist (Figure 4), whereas the short opponens splint should suffice if the pain is limited to the carpometacarpal joint. Alternatively, the smaller Push Ortho CMC brace (Figure 5) (J. Colditz, 2000) or three point strap splint (Figure 6) (Wajon, 2000) may be useful for more specific task performance activities, including writing, stringed instrument playing and crafts. It is essential to consider the severity and source of symptoms, along with specific patient requirements when deciding which splint to provide.

While there is no evidence to support the superiority of one exercise program over another, there is a general consensus that exercise may improve pain, function and strength (Davenport, Jansen, & Yeandle, 2012; Wajon & Ada, 2005). Guidelines for the performance of exercises may be found in a narrative review by Valdes and Heyde (Valdes K & Von der Heyde, 2012). They suggest that exercises should be pain-free and not lead to an aggravation of pain for

more than two hours after the activity. A retrospective review of a dynamic stability approach to the treatment of this common condition reported a reduction in pain and disability scores with a combination of splinting, web space release, mobilizations to provide distraction and to reduce dorsal subluxation, 1st dorsal interosseous strengthening and taping (O'Brien & Giveans, 2013).

Figure 4: Long opponens splint

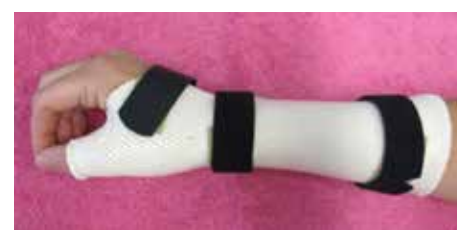

Figure 5: Push Brace

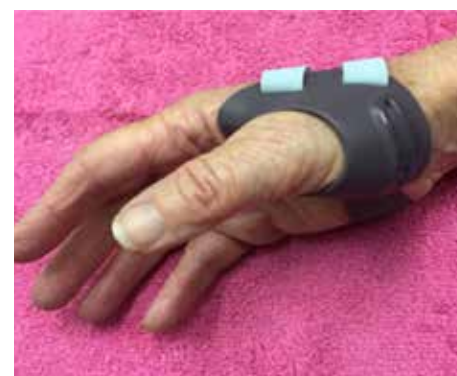

Figure 6: Three point splint



Anatomical studies have identified the presence of mechanoreceptors in the dorsal carpometacarpal joint ligaments (Hagert & Mobargha, 2012), supporting their proprioceptive role in enhancing joint stability. Further, recent studies have confirmed the importance of the first dorsal interosseous in counteracting dorsoradial subluxation (Mobargha et al., 2015). This has led the author to develop specific exercises for

Figure 7: Trace tennis ball



Figure 8: Tearing paper



Figure 9: Use of chopsticks



neuromuscular retraining, particularly concentrating on activities that address stability. These exercises include improving the patient's awareness and control of the alignment of their thumb while tracing along the line of a tennis ball with the tip of the thumb (Figure 7). Similarly, they may practice tearing sheets of paper while 'maintaining the thumb joints in an ideal arc' (Figure 8) (J. C. Colditz, 2013), incorporate regular use of chopsticks to improve joint position sense and neuromuscular control (Figure 10), or enhance stability by rotating a credit card in exercise putty.

Considering the dorsal CMC joint capsule is innervated by the dorsal sensory branch of the radial nerve, and the volar capsule intermittently receives branches from the median nerve (Hagert E, 2012; Mobargha, Ludwig, Ladd, & Hagert, 2014), the author also instructs patients in radial (Figure 10) and/or median nerve glides (Figure 11). These exercises are particularly useful when patients report dorsal or volar CMC joint pain respectively, and have found to be effective in reducing pain sensitivity and increasing pinch strength (Villafane, Silva, Bishop, & Fernandez-Camero, 2012).

The specific intervention that is appropriate for any given patient will depend on the severity of the patient's symptoms at the time, and their response to treatment provided. Failure of symptom relief with such conservative interventions may lead

Figure 10: Radial nerve glides

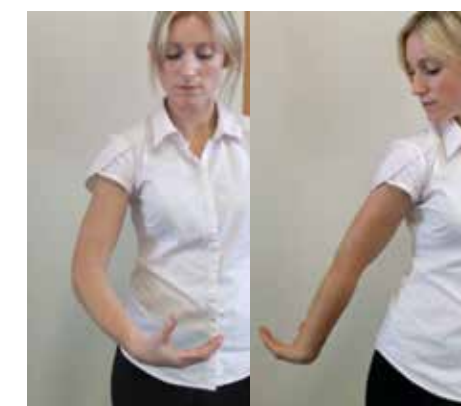

Figure 11: Median nerve glides



the therapist to consider whether graded motor imagery could be useful, as recent research has suggested sensitization mechanisms may contribute to chronic pain in this population (Chiarotto, Fernandez-de-Las-Penas, Castaldo, & Villafane, 2013). Of course, there will be some patients who fail to respond to conservative measures and decide to proceed with surgery for ongoing debilitating pain and limitation of function.

This article has been expanded from a recent short article written by this author in Grieve's Modern Musculoskeletal Physiotherapy, 4th edition (2015).

REFERENCES:

- Chiarotto, A., Fernandez-de-Las-Penas, C., Castaldo, M., & Villafane, J. H. (2013). Bilateral Pressure Pain Hypersensitivity over the Hand as Potential Sign of Sensitization Mechanisms in Individuals with Thumb Carpometacarpal Osteoarthritis. *Pain Medicine*, 14(10), 1585-1592. Retrieved from <http://0-ovidsp.ovid.com.alpha2.latrobe.edu.au/ovidweb.cgi?T=JS&CSC=Y&NEWS=N&PAGE=fulltext&D=prem&AN=23802919>
- Colditz, J. (2000). The biomechanics of a thumb carpometacarpal immobilisation splint. *Journal of Hand Therapy*, 13(3), 228-235.
- Colditz, J. C. (2013). Dynamic loading posture of the thumb: the Colditz tear test. *Journal Hand Therapy*, 26(4), 360-362.
- Davenport, B. J., Jansen, V., & Yeandle, N. (2012). Pilot randomized controlled trial comparing specific dynamic stability exercises with general exercises for thumb carpometacarpal joint osteoarthritis. *Hand Therapy*, 17(3), 60-67. doi:10.1258/ht.2012.012010
- Eaton, R., & Glickel, S. (1987). Trapeziometacarpal osteoarthritis. Staging as a rationale for treatment. *Hand Clinics*, 3(4), 455-471.
- Hagert E, L. J., Ladd A. (2012). Innervation patterns of thumb trapeziometacarpal joint ligaments. *Journal Hand Surgery*, 37A, 706-714.
- Hagert, E., & Mobargha, N. (2012). The role of proprioception in osteoarthritis of the hand and wrist. *Current Rheumatology Reviews*, 8, 278-284.
- Mobargha, N., Esplugas, M., Garcia-Elias, M., Lluch, A., Megerle, K., & Hagert, E. (2015). The effect of individual isometric muscle loading on the alignment of the base of the thumb metacarpal: a cadaveric study. *Journal Hand Surgery*. doi:10.1177/1753193415597114
- Mobargha, N., Ludwig, C., Ladd, A., & Hagert, E. (2014). Ultrastructure and Innervation of Thumb Carpometacarpal Ligaments in Surgical Patients With Osteoarthritis. *Clinical Orthopaedics and Related Research*, 472(4), 1146-1154. doi:10.1007/s11999-013-3083-7
- O'Brien, V. H., & Giveans, M. R. (2013). Effects of a dynamic stability approach in conservative intervention of the carpometacarpal joint of the thumb: a retrospective study. *Journal of Hand Therapy*, 26(1), 44-52.
- Skirven, T. (1996). Clinical examination of the wrist. *Journal Hand Therapy*, 9(2), 96-107.
- Swigart, C., Eaton, R., Glickel, S., & Johnson, C. (1999). Splinting in the treatment of arthritis of the first carpometacarpal joint. *Journal of Hand Surgery*, 24A, 86-91.
- Valdes K, & Von der Heyde, R. (2012). An exercise program for carpometacarpal osteoarthritis based on biomechanical principles. *Journal Hand Therapy*, 25, 251-263.
- Villafane, J., Silva, G., Bishop, M., & Fernandez-Camero, J. (2012). Radial nerve mobilization decreases pain sensitivity and improves motor performance in patients with thumb carpometacarpal osteoarthritis: a randomized controlled trial. *Archives Physical Medicine Rehabilitation*, 93, 396-403.
- Wajon, A. (2000). The thumb strap splint for dynamic instability of the trapeziometacarpal joint. *Journal of Hand Therapy*, 13(3), 236-237.
- Wajon, A., & Ada, L. (2005). No difference between two splint and exercise regimens for people with osteoarthritis of the thumb: a randomised controlled trial. *Australian Journal of Physiotherapy*, 51, 245-249.



To provide global networking and educational opportunities to develop and enhance the practice of hand therapy

UPDATE

www.ifsht.org | info@ifsht.org

Vol. 9 Issue 4 | Oct 2015

THE UPDATE IS UPDATED!

Welcome to our NEW graphic design for the IFSHT Update.

SPOTLIGHT ON MEMBER SOCIETY: CANADA

CSHT has 180 members from across the country with the majority based in Ontario, Canada's most populous province. Members mainly come from an occupational therapy background (approximately 80%) and typically work in a public healthcare setting. Private practice opportunities are growing as the public system is less able to offer outpatient hand therapy services.

CSHT hosts an annual conference every May. This year the conference was in Montreal, Quebec focusing on Pain Management, including best evidence for management of CRPS. The May 2016 conference will be held in Toronto, Ontario. CSHT produces a quarterly newsletter 'In-Hand', with useful clinical information.

CSHT applauds our member, Lynne Feehan, Past President of IFSHT. For more information, contact Trevor Fraser at president@csht.org.



Trevor Fraser, President of CSHT

SILENT AUCTION IFSHT 2016

IFSHT is excited to again hold a silent auction at the 2016 Congress in Buenos Aires. This is one of the many highlights of the IFSHT Congress, and provides an opportunity to raise much needed funds to support both speakers and therapists with financial hardships to attend the IFSHT Congress in 2019.

Please plan to donate small and easily transportable items in new or good condition such as educational resources, assessment tools, or objects of art. Bring them with you or give them to someone else from your association who is attending.



2015 BRAZILIAN HAND THERAPY CONFERENCE

The Brazilian Hand Therapy Society met Septem-

ber 5-7 at São Paulo University in Ribeirão Preto for their 13th Hand Therapy Congress. The congress theme was "The Hand and Upper Limb, the Search for Functionality." Invited speakers from five countries completed the local scientific program. More than one hundred therapists attended the congress. Sarah Ewald, IFSHT President, enjoyed the congress and the opportunity to liaise with colleagues in Brazil while raising awareness of the upcoming IFSHT Triennial Congress in Buenos Aires next year.



13th Brazilian National Hand Therapy Congress, L to R: Valeria Elui, Birgitta Rosen (invited speaker, Sweden), Marisa Fonseca, Sarah Ewald (President, IFSHT), Candida Luzo, Patrícia Mazzer (President)

IFSHT LEADERSHIP NOMINATIONS 2016-2019

If you are a therapist from one of IFSHT's full member societies and are interesting in joining the IFSHT Executive Committee, please take a moment to review the descriptions of each office (<http://www.ifsht.org/page/executive-committee-job-descriptions>). Nominations are open until April 2016; ask your association to nominate you for a position on the 2016-2019 IFSHT Executive Committee.

HAND THERAPY CONNECTIONS E-NEWSLETTER

Sign up for the IFSHT Hand Therapy Connections email sent 2-3 times per year with information about events in the hand therapy community. Log in at <http://ifsht.org/page/e-mail-newsletter> to sign up.

DYNAMOMETER PROGRAM



IFSHT dynamometers are distributed in Guatemala.

Nancy Winiecki (right), a Grand Valley State University faculty member, recently provided Sylvia, a PT in Zaca with an IFSHT dynamometer for use in the Hand in Motion Clinics.

For hand therapy educational events, go to "National/International Education Events" under "Education" at www.ifsht.org.

Member Society Updates

THE EGYPTIAN SOCIETY FOR SURGERY OF THE HAND AND MICROSURGERY (ESSHM)

The Egyptian Society for Surgery of the Hand and Microsurgery has had a busy year in 2014-2015.

In October 2014, the annual Wrist Surgery Instructional Course was held in beautiful Alexandria under the leadership of Professor Essam El Karef, ESSHM President, and Professor Hany Morsey. The course was very successful and well attended.

In April 2015, the 8th annual congress of ESSHM was held in Cairo. The distinguished guest speakers included Professor Marc Garcia-Elias from Barcelona, Spain, Professor Jin Bo Tang from Nantong, China and Professor Loree Killiainen from St. Paul, Minnesota, USA. The congress was also very well attended. Professor Garcia-Elias chaired an instructional course, along with Professor Nash Naam, on Wrist Examination and Evaluation. This was very popular.

Professor Tang chaired a hands-on surgical workshop, along with Professor Mostafa Mahmoud, on how to repair flexor tendons. These courses were the highlights of the meeting considering the talent and the quality of the course instructors.

The society still promotes local meetings in civilian and Military hospitals to promote hand surgery across the country. ESSHM continues to be the leader in the Arab World promoting hand surgery and research across the area and the Kuwaiti Hand Society has been accepted as a member of IFSSH during the last council meeting in Seattle, USA. The ESSHM has been accepted as a corresponding member of the European Federation of Societies for Microsurgery (EFSM).

This month (October) the annual Wrist Surgery Instructional Course will be held again in Alexandria. Professor Marc Garcia-Elias will be the distinguished guest speaker.

The 9th annual congress for ESSHM will be held in Cairo on April 5-7, 2016. We would like to invite all our friends from across the globe to honor us with their presence. The meeting will have a stimulating scientific program and an ambitious social program as well. For information please email Professor Abdel Hakim A. Massoud at mass321@hotmail.com

Nash H Naam, MD, FACS - ESSHM Representative to IFSSH (drnaam@handdocs.com)

Below Right:
The Faculty of the April 2015 Annual Congress; Professors Massoud, Garcia-Elias, Killiainen, Mrs. Tang, Professor Tang and Drs. Awad and Naam

Below Left:
Professor Marc Garcia-Elias demonstrate how to examine the wrist



Top: The faculty and the attendees of the April 2015 Annual Congress

THE FINNISH SOCIETY FOR SURGERY OF THE HAND

The Finnish Society for Surgery of the Hand is arranging the 2016 Scandinavian Hand Society meeting in Levi, Lapland, Finland. This will be held from 31 March to 3 April, 2016.

The topics of the meeting will include sports-related injuries of the elbow and the wrist, nerve and tendon transfers, brachial plexus surgery and new techniques in hand surgery. The speakers will be international top specialists as well as Scandinavian leading authors.

Full details are available on the website: www.sssh2016.fi

Please join us for science and fun!

FRENCH SOCIETY FOR SURGERY OF THE HAND (SFCM)

Hand Surgery in France has probably never been so active than during 2015 regarding meetings and relationships with colleagues of other national Hand Surgery Societies.

First of all, the French Society for Hand Surgery gave up its old informal name (GEM, Groupe d'Etude de la Main) in January 2015, to become the SFCM, Société Française de Chirurgie de la Main (translation: French Society for Hand Surgery).

The SFCM currently has more than 600 Members and has two meetings a year, the largest being the December meeting in Paris (about 1000 attendees each year). A junior members section was created in 2014 for residents and young fellows interested in hand surgery, and who are working in accredited hand and upper extremity surgical centers. We think this will be an incentive to produce excellent future hand surgeon. The SFCM has its own journal, "Chirurgie

de la Main", a website (sfcml.fr) and a dedicated, highly efficient Secretary, Mrs. Juliette Chort. The upcoming 2015 SFCM Meeting in Paris, to be held over three days in December, promises to be very special. The SFCM executive committee has invited two well-known international hand surgeons, Dr RA Berger (Rochester, Mayo Clinic, USA) and Dr D Slutsky (Los Angeles, USA), as well as a special Chinese Delegation convened by PC Ho (Hong Kong) which will include 10 well renowned surgeons from Mainland China (W Xu, CY Fan from Shanghai, SL Chen, B Liu from Beijing, JB Tang, YJ Rui from Jiangsu), from Hong Kong (PC Ho, CW Wong) and from Taiwan (JT Shih, YK Tu). All of these prestigious speakers will give lectures and will participate as session moderators. Two other highlights of the meeting will be the gala dinner at Palais du Luxembourg in Paris, a political and historical French bastion, and a lecture by Colonel Velluz, the former squadron leader of

the famous Patrouille de France flight escadrille. For the first time ever, the whole meeting will go all-electronic and will include a downloadable app. Since we should not forget our precious, highly qualified OR nurses, a special Nurses' Session will also be a new feature on the Program this year. The heritage of the old "GEM" Pioneers is in good shape! The SFCM liaises in close relationship with other societies, such as the French Orthopedic Society and the French Plastic Surgery Society. This year for the very first time we will have a combined session within the Annual Orthopedic Meeting during their Specialty day on 11 November 2015. We have worked hard throughout this year to reinforce the links with both the French Orthopedic and Plastic Societies. The SFCM also has close ties with the GAM (Group for Microsurgery Advances- annual meeting in May), the GEMMSOR (Hand Physiotherapists Society- annual meeting in December in conjunction with SFCM meeting), the FESUM (European Federation for Emergency care of Hand Trauma- two annual meetings) and EWAS (European Wrist Arthroscopy Society which held no less than 3 hands-on meetings this year).

Twice a year, the EWAS sponsors a very special international "Wrist Arthroscopy Tour de France" where senior residents and fellows can watch prominent wrist arthroscopy



Above: First Official Meeting of the Editorial Board of the new Journal of Wrist Surgery, Lyon, France, during the Lyon Wrist Surgery 2011. From left to right: M. Haerle, M. Boeckstyns, L De Smet, P.C. Ho, C. Mathoulin, G. Herzberg, R. Luchetti, P. Liverneaux, D. Slutsky, J.R. Haugstvedt, M. Chammas

surgeons perform numerous live arthroscopic procedures. Since 2005, EWAS has also sponsored an annual International Wrist Course in Lyon (alcoms69.fr) in October. This year, we will welcome 33 prestigious speakers from Europe, USA, Hong Kong, Japan and Australia.

I had the privilege of being the President of SFCM during this active and exciting year, and will also have the honor next year to participate in the Buenos Aires IFSSH Congress as President of the EWAS.

My thanks to the Editor of the Ezine.

Guillaume Herzberg

2015 President of SFCM (French Society for Hand Surgery)

GERMAN SOCIETY FOR SURGERY OF THE HAND (DGH)

During 2015, the German Society for Surgery of the Hand (DGH) council met several times to discuss further activities. The work on the hand trauma register was continued and new ideas were raised. Relationships with the German Society for Surgery (DGCh), the German Society for Plastic, Reconstructive and Aesthetic Surgery (DGPRÄC) as well as the German Society for Traumatology (DGU) and Orthopedic Surgery (DGOOC) have been intensified with activities during several meetings.

The 56th annual congress of the DGH was held recently - September 24-26, 2015 - in Ludwigsburg, Germany, in conjunction with the German Hand Therapist Group (DAHTh). Prof. Max Haerle was the President of the congress. He is also Secretary General of the Federation of European Societies for Surgery of the Hand (FESSH). The congress was very successful and the guest society was the Italian Society



Prof. Max Haerle (DGH Congress President in Ludwigsburg 2015) and Prof. Michael Sauerbier (DGH Congress President 2016 in Frankfurt am Main)

Buck-Gramcko Lecturer Prof. Giorgio Brunelli (third from left) with Prof. Riccardo Giunta, Prof. Max Haerle, Dr. Martin Richter

for Surgery of the Hand (SICM). New and old friendships have been fostered. The speaker for the traditional Buck-Gramcko Lecture of our society was Prof. Giorgio Brunelli from Brescia, Italy. The new President of the DGH is now Dr. Martin Richter from Bonn, Germany, and the new Secretary General is Prof. Jörg van Schoonhoven from Bad Neustadt, Germany.

2016 will be a busy year for the Germany Society. It will start with an invitation to be the guest society during the annual meeting of the American Association for Hand Surgery (AAHS) in Scottsdale, Arizona, USA, January 13-16. After this meeting, the council will focus on the next congress of the International Societies for Surgery of the Hand (IFSSH) from October 24-28, 2016 in Buenos Aires, Argentina. As the German Society for Surgery of the Hand (DGH) will host the following IFSSH triennial congress in May 2019 in Berlin, Germany, many DGH members have made travel plans to go to Argentina and support our

friends over there.

The next annual congress of the German Society for Surgery of the Hand will be held in Frankfurt am Main, Germany, September 22-24, 2016. The American Association for Hand Surgery (AAHS) will be the invited guest society. Prof. Michael Sauerbier will be the local host and congress President, and the program co-chairs will be Prof. Riccardo Giunta (Munich, Germany) and Michael Neumeister (Springfield, Ill, USA). Scientific topics will include Microsurgical reconstruction after severe hand injuries; Thumb reconstruction; Treatment of malignant tumors of the hand and forearm; Scaphoid fractures and their sequelae; Distal radioulnar joint; and an open choice of subjects. The abstract submission deadline is May 8, 2016. Further information is available on the website: www.dgh-kongress.de

Michael Sauerbier, MD, PhD

IFSSH Delegate, German Society for Surgery of the Hand (DGH)

INDIAN SOCIETY FOR SURGERY OF THE HAND.

The 39th Annual Meeting of the Indian Society for Surgery of the Hand was held from 25th to 27th September, 2015 at Indore in the State of Madhya Pradesh. Indore is in central India and this was the first time this meeting was held in the city, keeping with the ideology of the ISSH to rotate the meetings to new places and also to propagate the spread of the specialty. Dr. Shailesh Gupta and Dr. Bhangani were the organizers and they did a creditable job.

The Indian Society for Surgery of the Hand had two guest orations - Prof. P C Ho (Hong Kong) delivered the BB Joshi Oration and Prof. Fuminori Kanaya delivered the Venkataswami Oration. Dr. Makarand Tare and Dr. Amit Tolat from the UK conducted a symposium on Flexor Tendon Injuries.

There was a change of the Secretary of the ISSH. The new address of the

Secretary is as follows:

Dr. Rajendra Nehete,
Vedant (Nehete) Hospital
Shreehari Kute Marg,
Nashik 422002
Email : rajendranehete@gmail.com
Ph-(0253) 2313811 / 2576360
Mob - 94239 71725/ 98220 51900

Dr. S. Raja Sabapathy continues to act as the liaison for the IFSSH and he has been elevated to be a member of the Board of Trustees of ISSH. The next meeting of the ISSH will be held in Ranchi from 15th to 17th September, 2016. Dr Anant Sinha (Devkamal Hospital, Ranchi) will be the Organising Chairman.



Dr. Prakash Kotwal, President ISSH felicitating the Dr Venkataswami Orator, Dr. Fuminori Kanaya and Dr. Vikas Gupta



Dr. Bhangani, Organising Chairman, ISSH felicitating the BB Joshi Orator, Dr. P.C. HO

REPORT FROM HAND AND WRIST BIOMECHANICS INTERNATIONAL (HWBI)

HWBI 2015 Symposium Milan, Italy

The Hand and Wrist Biomechanics International (HWBI) was formed to further enhance multidisciplinary and international collaborations related to hand/wrist biomechanics. The HWBI has established affiliations with the International Society of Biomechanics (ISB) and the International Federation of Societies for Surgery of the Hand (IFSSH). The HWBI is proud of these affiliations, which support the HWBI's driving focus of advancing hand science by collectively addressing challenging clinical problems.


The HWBI has a long history of international symposia dating back to 1992. This year, the HWBI held its 9th Symposium at Milano Congressi in Milan, Italy from June 16-17, 2015. This year's symposium was held in conjunction with the 20th Congress of Federation of European Societies for Surgery of the Hand (FESSH), June 17-20, 2015. The symposium program featured 56 presentations including keynotes, invited talks, and open paper submissions. Main topics covered at this year's event included the wrist, carpal tunnel, finger mechanics, motor control, distal radial ulnar joint (DRUJ), distal radius, ligaments, tendons, and biomaterials. The 2015

symposium also featured the 2nd International Thumb Osteoarthritis Workshop. There was record attendance at this year's event, with 102 participants including hand surgeons, hand therapists, and engineers from 16 countries. The HWBI is excited to continue building upon the excitement and success generated during the symposium.

For the first time, the HWBI awarded travel scholarships for the 2015 symposium to outstanding students, residents, and fellows. Four scholarships were generously sponsored by the ISB, HWBI, and William H. Seitz, MD Research Fund. An award committee was formed to select this year's winners based on their abstract submissions to the symposium. The award winners were Joseph N. Gabra (USA), Benjamin Goislard de Monsabert (France), Faes D. Kerkhof (Belgium), and Giovanni F. Solitro (USA). The HWBI is grateful to the ISB and Dr. Seitz for their sponsorship and hopes to award even more scholarships at future symposia. For more information about the HWBI and its events, please visit the website at www.hwbi.org.

Zong-Ming Li, Chair,
HWBI Board of Directors
Marc Garcia-Elias,
Co-Chair, HWBI 2015 Symposium
Fred Werner,
Co-Chair, HWBI 2015 Symposium

HWBI scholarship recipients with symposium organizers. From left: Ken Fischer, Marc Garcia-Elias, Zong-Ming Li, Giovanni Solitro, Benjamin Goislard de Monsabert, Joseph Gabra, and Faes Kerkhof, and Fred Werner



ezine
ifssh
CONNECTING OUR GLOBAL HAND SURGERY FAMILY

IFSSH-IFSHT CONGRESS 2016

We are organizing an amazing scientific program, with the best colleagues from all over the world, and wonderful social events for you. The 13th IFSSH and 10th IFSHT Congress will be held in Buenos Aires, Argentina, at the Hilton Hotel & Convention Center, from the 24th to 28th October 2016.

Buenos Aires
Argentina
2016
13th IFSSH & IFSHT Congress

Setting New Frontiers
24th- 28th October, 2016



Come join us for an unforgettable experience!



Eduardo R. Zancolli
President for the
IFSSH&IFSHT 2016 Congress

[HTTP://WWW.IFSSH-IFSHT2016.COM](http://www.ifssh-ifsht2016.com)



www.ifssh.info

Buenos Aires
Argentina
2016
13th IFSSH & IFSHT Congress 10th
October 24 - 28

Make your plans to attend
the first world Congress in South America
www.ifssh-ifsht2016.com

Contact us AACM






THE JOURNAL OF HAND SURGERY (AMERICAN)

VOLUME 40, ISSUE 10, PAGES A1-
A20, 1937-2132 (OCTOBER 2015)

- Prosthetic Arthroplasty Versus Arthrodesis for Osteoarthritis and Posttraumatic Arthritis of the Index Finger Proximal Interphalangeal Joint
Pages 1937-1948
Mark A. Vitale, Kristin M. Fruth, Marco Rizzo, Steven L. Moran, Sanjeev Kakar
- Revision Proximal Interphalangeal Arthroplasty: An Outcome Analysis of 75 Consecutive Cases
Pages 1949-1955.e1
Eric R. Wagner, T. David Luo, Matthew T. Houdek, Daryl J. Kor, Steven L. Moran, Marco Rizzo
- Pyrocarbon Metacarpophalangeal Joint Arthroplasty in Noninflammatory Arthritis: Minimum 5-Year Follow-Up
Pages 1956-1962
David R. Dickson, Ravi Badge, David Nuttall, Adam C. Watts, Sumedh C. Talwalkar, Mike Hayton, Ian A. Trail
- The Efficacy and Safety of Concurrent Collagenase Clostridium Histolyticum Injections for 2 Dupuytren Contractures in the Same Hand: A Prospective, Multicenter Study
Pages 1963-1971
- Lateral Femoral Condyle Flap: An Alternative Source of Vascularized Bone From the Distal Femur
Pages 1972-1980
Victor W. Wong, Heinz K. Bürger, Matthew L. Iorio, James P. Higgins
- Biomechanical Study of the Digital Flexor Tendon Sliding Lengthening Technique
Pages 1981-1985
Ken Hashimoto, Kazuki Kuniyoshi, Takane Suzuki, Ryo Hiwatari, Yusuke Matsuura, Kazuhisa Takahashi
- The Effect of 1-Ethyl-3-(3-Dimethylaminopropyl) Carbodiimide Suture Coating on Tendon Repair Strength and Cell Viability in a Canine Model
Pages 1986-1991
Andrew R. Thoreson, Ryo Hiwatari, Kai-Nan An, Peter C. Amadio, Chunfeng Zhao
- The Reliability of Ultrasound Measurements of the Median Nerve at the Carpal Tunnel Inlet
Pages 1992-1995
John R. Fowler, David Hirsch, Kevin Kruse
- Hand Sensibility, Strength, and
- Laxity of High-Level Musicians Compared to Nonmusicians
Pages 1996-2002.e5
Susan E.G. Sims, Laura Engel, Warren C. Hammert, John C. Elfar
- Management of Isolated Musculocutaneous Injury: Comparing Double Fascicular Nerve Transfer With Conventional Nerve Grafting
Pages 2003-2006
Prem Singh Bhandari, Prabal Deb
- Afferent Innervation, Muscle Spindles, and Contractures Following Neonatal Brachial Plexus Injury in a Mouse Model
Pages 2007-2016
Sia Nikolaou, Liangjun Hu, Roger Cornwall
- The Effects of Generally Administered Anti-Nerve Growth Factor Receptor (p75NTR) Antibody on Pain-Related Behavior, Dorsal Root Ganglia, and Spinal Glia Activation in a Rat Model of Brachial Plexus Avulsion
Pages 2017-2025
Tomoko Kobayashi, Kazuyo Yamauchi, Yusuke Matsuura, Kazuki Kuniyoshi, Kazuhisa Takahashi, Seiji Ohtori
- The Extended Flexor Carpi Radialis Approach for Concurrent Carpal Tunnel Release and Volar Plate Osteosynthesis for Distal Radius Fracture
Pages 2026-2031.e1
Shruti C. Tannan, Ioannis P. P

- appou, Frank W. Gwathmey, Aaron M. Freilich, Abhinav Bobby Chhabra
- Biomechanical Comparison of Volar Fixed-Angle Locking Plates for AO C3 Distal Radius Fractures: Titanium Versus Stainless Steel With Compression
Pages 2032-2038
Tyler Marshall, Amit Momaya, Alan Eberhardt, Nilesh Chaudhari, Thomas R. Hunt III
 - The Palpable Scaphoid Surface Area in Various Wrist Positions
Pages 2039-2044
Juan M. Giugale, Daniel Leigey, Kyle Berkow, David M. Bear, Mark E. Baratz
 - Plate and Screw Fixation of Bicolumnar Distal Humerus Fractures: Factors Associated With Loosening or Breakage of Implants or Nonunion
Pages 2045-2051.e2
Femke M.A.P. Claessen, Yvonne Braun, Rinne M. Peters, Gregory P. Kolovich, David Ring
 - Aneurysmal Bone Cysts of the Hand, Wrist, and Forearm
Pages 2052-2057
Matthew M. Crowe, Matthew T. Houdek, Steven L. Moran, Sanjeev Kakar
 - The Hand in Art: Clinodactyly in Renaissance Paintings
Pages 2058-2060
Davide Lazzeri, Luca Grassetti, Giovanni di Benedetto, William R.
- Albury, George M. Weisz
- Poems: Kubler Ross V; Silo, or Collective Nouns
Page 2061
Noah M. Raizman
 - Journal CME Instructions
Page 2062
 - Kirschner Wire Exposure in Hand and Wrist Trauma
Pages 2063-2064
Mark H. Henry
 - Acute Scapholunate Ligament Instability
Pages 2065-2067
Michael S. Guss, Wesley H. Bronson, Michael E. Rettig
 - Superficialis Sling (Flexor Digitorum Superficialis Tenodesis) for Swan Neck Reconstruction
Pages 2068-2074
David H. Wei, Andrew L. Terrono
 - Distal Radius Joint Surface Reconstruction Using a Pedicle Pisiform Osteochondral Transfer
Pages 2075-2080
Hisao Ishii, Masahiro Tatebe, Hitoshi Hirata
- JOURNAL OF HAND SURGERY (ASIAN-PACIFIC VOLUME)**
- 335
Journal of Hand Surgery Asian-Pacific Volume: Current Status and the Future
Michael A. Tonkin
- 336
The OMT Classification of Congenital Anomalies of the Hand and Upper Limb
Michael A. Tonkin, Kerby C. Oberg
- 343
Anticipatory and Reactive Response to Falls: Muscle Synergy Activation of Forearm Muscles
Greg Couzens, Graham Kerr
- 352
Kienböck Disease: Recent Advances in the Basic Science, Assessment and Treatment
Gregory Ian Bain, Chong Jin Yeo, Levi Philip Morse
- 366
3D Dynamic Analysis of the Wrist
Michael J. Sandow
- 369
Structural Failure Mechanisms of Common Flexor Tendon Repairs
Tim Sebastian Peltz, Roger Haddad, Peter James Scougall, Sean Nicklin, Mark Peter Gianoutsos, Rema Oliver, William Robert Walsh
- 380
The Use of Composite Tissue Spare Parts to Restore Tripod Hand Function in Post-Traumatic and Congenital Hand
- Deficiency
Bhaskaranand Kumar, Anil Keshavamurthy Bhat, Ashwath Madhusudan Acharya
- 386
Comparison between Collagenase Injection and Partial Fasciectomy in the Treatment of Dupuytren's Contracture
Terence Khai Wei Tay, Huey Tien, Elizabeth Yenn Lynn Lim
- 391
Wrist Septic Arthritis: An 11 Year Review
Robert Tze Jin Yap, Shian Chao Tay
- 396
Proposed Guidelines for Treatment of Concomitant Distal Radius and Distal Ulna Fractures
Benjamin Liang, Jen Ming Lai, Arul Murugan, Kin Ghee Chee, Sreedharan Sechachalam, Tun-Lin Foo
- 402
Dupuytren's Contracture: A Bibliometric Study of the Most Cited Papers
Cormac Weekes Joyce, Kenneth Mary Joyce, George Rahmani, Sean Michael Carroll, Jack Laurence Kelly, Padraic James Regan
- 410
Characteristics of Fingertip Injuries in Children in Singapore
Mala Satku, Mark Edward Puhaindran, Alphonsus Khin Sze Chong
- 415
Audit of Clinical and Functional Outcomes of Arthroscopic Resection of Wrist Ganglions
Sze-Ryn Chung, Shian Chao Tay
- 421
Bone Marrow Derived Mesenchymal Stem Cell Augmentation of Rabbit Flexor Tendon Healing
Min He, Aaron Wei Tat Gan, Aymeric Yu Tang Lim, James Cho Hong Goh, James Hoi Po Hui, Alphonsus Khin Sze Chong
- 430
Supination and Pronation Strength Deficits Persist at 2-4 Years after Treatment of Distal Radius Fractures
Joris Ploegmakers, Bertram The, Allan Wang, Mike Bratty, Tim Ackland
- 435
Simple Trapeziectomy for Arthrosis of the Basal Joint of the Thumb: 49 Thumbs Reviewed After Two Years
Kristine Elvebakk, Ingrid Elisabeth Johnsen, Cecilie Bendiksen Wold, Thomas Finsen, Harald Russwurm, Vilhjalmur Finsen
- 440
Frequency of Scapholunate Ligament Injuries Associated with Distal Radius Shearing Fracture: Correlation of Fracture Patterns and Ligament Tear
Shiro Yoshida, Kenji Yoshida, Kensuke Sakai, Kenjiro Nakama, Naoto Shiba
- 447
One-Per-Mil Tumescant Infiltration Technique for Vascular Malformation Surgery in Hand and Upper Extremity
Theddeus O.H. Prasetyono, Jesslyn Gustin
- Case Report
453
Primary Index Finger Pollicization for Thumb Reconstruction Following Soft Tissue Sarcoma Excision
Velagala Satyanarayana Reddy, Adam Sierakowski, Madhu Periasamy, Shanmuganathan Raja Sabapathy
- 458
Fibro-Osseous Pseudotumour of the Digit: An Illustrative Case and Review of the Literature
Jieyun Zhou, Catriona McLean, Cameron Keating, James Finkemeyer, Adel Morsi
- 463
Thumb Carpometacarpal Joint Stabilization in Ehlers-Danlos Syndrome - Case Report
Anca Nicoleta Breahna, Bryce Maurice Meads
- 466
Post Traumatic Avascular Necrosis of the Proximal Carpal Row - A Case Report
Ruben Manohara, Sandeep Jacob Sebastin, Mark Edward Puhaindran
- 471
Surgical Repair with External Fixation of Epiphyseal Fractures of the Proximal Phalanges of Three Fingers: A Case Report
Yasushi Morisawa, Shinichiro Takayama, Kazuki Sato
- 474
Attrition Rupture of the Flexor Pollicis Longus Tendon after Arthrodesis of the Trapeziometacarpal Joint: A Case Report

Kumiko Kanaya, Kohei Kanaya,
Kousuke Iba, Toshihiko Yamashita

477

A Rare Case of Reverse Oblique Ulnar
Head and Neck Fracture
Li June Tay, Howard Cottam, Jonathan
Compson

479

Cell-Enriched Lipoaspirate
Arthroplasty: A Novel Approach to First
Carpometacarpal Joint Arthritis
Stefan Bohr, Hans Oliver Rennekampff,
Norbert Pallua

482

Bifid Median Nerve - A Case Report
Mohamed Ibrahim, Yasunori Hattori,
Kazuteru Doi, Sotetsu Sakamoto, Tomas
Madura

484

Linear Hand Burn Contracture Release
under Local Anesthesia without
Tourniquet
Theddeus O.H. Prasetyono, Astrid F.
Koswara

488

The Significance of Bone Abrasions
in Fight Bite Injuries: Beware of the
Osteochondral Defect
Dariush Nikkhah, Roshan Vijayan,
Waseem Bhat

JOURNAL OF HAND THERAPY

**VOL 28, ISSUE 3, JULY-
SEPTEMBER 2015**

- Transition thoughts
Joy C. MacDermid
- Conservative treatment of mallet
finger: A systematic review
Kristin Valdes, Nancy Naughton,
Lori Algar
- The diagnostic accuracy
of five tests for diagnosing
partial-thickness tears of the
supraspinatus tendon: A cohort
study
Jorge H. Villafañe, Kristin Valdes,
Fabio Anselmi, Caterina Pirali,
Stefano Negrini
- Clinical Relevance Commentary
in Response to: The diagnostic
accuracy of five tests for
diagnosing partial-thickness tears
of the supraspinatus tendon: A
cohort study
Mike Szekeres
- Factors affecting functional
recovery after surgery and
hand therapy in patients with
Dupuytren's disease
Christina Engstrand, Barbro
Krevers, Joanna Kvist
- How therapists specializing in
hand therapy evaluate the ability of
patients to participate in their daily
lives: An exploratory study
Gwen Weinstock-Zlotnick, Jane
Bear-Lehman

- Forearm amputees' views of
prosthesis use and sensory
feedback
Ulrika Wijk, Ingela Carlsson
- Cross-cultural adaptation,
reliability and validity of the
Turkish version of the Upper Limb
Functional Index (ULFI)
Eda Tonga, Neslihan Durutürk,
Philip C. Gabel, Agah Tekindal
- Greek adaptation and validation
of the Patient-Rated Tennis Elbow
Evaluation (PRTEE)
Dimitrios Stasinopoulos, Costas
Papadopoulos, Maria Antoniadou,
Loutsia Nardi
- Reliability, validity, and
responsiveness of a Canadian
French adaptation of the Western
Ontario Rotator Cuff (WORC) index
Corinne St-Pierre, Clermont E.
Dionne, François Desmeules,
Jean-Sébastien Roy
- The use of occupation-based
assessments and intervention
in the hand therapy setting – A
survey
Kimatha Oxford Grice
- Home-based movement therapy
in neonatal brachial plexus palsy:
A case study
Susan H. Brown, Rachel Napier,
Virginia S. Nelson, Lynda J.-S.
Yang
- A novel treatment tool to address
soft tissue dysfunction
Jim Wagner, Kelly Olson

- Zone III flexor tendon injuries
– A proposed modification to
rehabilitation
Shrikant J. Chinchalkar, Joey G.
Pipicelli, Anne Agur, George S.
Athwal
- Functional orthosis post pectoralis
muscle rupture
Jodi Moore
- Dart-Splint: An innovative
orthosis that can be integrated
into a scapho-lunate and palmar
midcarpal instability re-education
protocol
Federica Braidotti, Andrea Atzei,
Tracy Fairplay

JOURNAL OF HAND SURGERY (EUROPEAN VOLUME)

OCTOBER 2015 VOL 40

- Effect of volar angulation of extra-
articular distal radius fractures on
distal radioulnar joint stability: a
biomechanical study
Y. Bessho,
T. Nakamura,
T. Nagura,
M. Nishiwaki,
K. Sato,
and Y. Toyama
- Surgical treatment of acute distal
radioulnar joint instability associated
with distal radius fractures
H. S. Gong,
H. E. Cho,
J. Kim,
M. B. Kim,

Y. H. Lee,
and G. H. Baek

The value of post-operative
radiographs in clinical management
of AO type A distal radius fractures
S. Huffaker,
B. E. Earp,
and P. E. Blazar

Influence of surgeon, patient and
radiographic factors on distal radius
fracture treatment
V. Neuhaus,
A. G. Bot,
T. G. Guitton,
and D. C. Ring

Mortality after distal radial fractures
in the Medicare population
M. J. Shauver,
L. Zhong,
and K. C. Chung

A less invasive distal osteotomy
of the radius for malunited dorsally
displaced extra-articular fractures
M. W. M. Fok,
D. L. Fernandez,
and Y. L. Hernandez Rivera

The management of clenched fist
fight bite' injuries of the hand
D. J. Shewring,
R. W. Trickett,
K. N. Subramanian,
and R. Hnyda

Treatment of fracture subluxations
of the proximal interphalangeal joint
using a ligamentotaxis device: a
multidisciplinary approach
R. J. MacFarlane,

S. Gillespie,
F. Cashin,
A. Mahmood,
G. Cheung,
and D. J. Brown

Clinical comparison of hook plate
fixation versus extension block
pinning for bony mallet finger: a
retrospective comparison study
M. A. Acar,
Y. Güzel,
A. Güleç,
G. Uzer,
and M. Elmadağ

Corrective osteotomy for malunited
metacarpal fractures: long-term
results of a novel technique
K. Karthik,
R. Tahmassebi,
R. S. Khakha,
and J. Compson

Commentary on Karthik et al.
Corrective osteotomy for malunited
metacarpal fractures: long-term
results of a novel technique. K.
Karthik, R. Tahmassebi, R. S. Khakha
and J. Compson. J Hand Surg Eur.
2015, 40: 840–5
M. F. Langer

Vascularized medial femoral condyle
graft for management of scaphoid
non-union
A. Elgammal and
B. Lukas

One-stage rotational osteotomy for
congenital radioulnar synostosis
J. H. Hwang,
H. W. Kim,
D. H. Lee,

J. H. Chung,
and H. Park

Effective bony mallet reduction using
the principles of Elson's test

A. Salibi and

A. Barabas

An extreme case of transcapitoid-
transcapitate perilunate dislocation
in an adolescent

K. Osman,
P. Momoh,
and A. Ruiz

Ulnar styloid fracture has no
impact on the outcome but
decreases supination strength after
conservative treatment of distal

radial fracture

S. Yilmaz,

D. Cankaya,

and D. Karakus

Complex anterior dislocation of the
metacarpophalangeal joint of the
index finger: The 'reverse-Kaplan'
injury

R. N. Green,
P. R. P. Rushton,
and D. J. Cloke

The treatment of bony mallet
fingers using a triple K-wire fixation
technique

B. Jiang,
P. J. Wang,
and J. J. Zhao

Acute ischemia of a thumb 10 years
after revascularization


J. Couceiro,
E. Moledo,
and M. Sanmartín

Modified dorsal percutaneous screw
fixation through a transtrapezial
approach for scaphoid fractures

T. Kurahashi,
T. Shinohara,
and H. Hirata

Combined tendon avulsion and
fracture in a mallet finger injury in a
juvenile

J. P. A. Bellity and
M. A. Tonkin



38^{ème} CONGRÈS DU GAM
MEETING OF GAM
Group for the Advancement of Microsurgery

PARIS 27-28 MAI 2016
MAY 27-28, 2016
MAISON DE L'AMÉRIQUE LATINE

SUBMIT YOUR ABSTRACT

WWW.GAM-SFM.ORG

Président / President:

Jean-Noël GOUBIER

Secrétaire / Secretary:

Philippe VALENTI



**INSCRIPTION
REGISTRATION**



**SOUMETTEZ
votre abstract**

**SUBMIT
your abstract**

**TÉLÉCHARGER
la 1^{ère} annonce**

**DOWNLOAD
1st announcement**



38^{ème} CONGRÈS DU GAM
MEETING OF GAM
Group for the Advancement of Microsurgery

MAISON DE L'AMÉRIQUE LATINE
PARIS
27-28 MAI 2016
MAY 27-28, 2016

**1^{ère} ANNONCE
1ST ANNOUNCEMENT**

GAM
www.gam-sfm.org

Honorary
Advisory
Secretary
Stil

Honorary
Secretary
Jean-Noël GOUBIER
Philippe VALENTI

Thèmes / Themes

• Table ronde : Reconstruction microchirurgicale de la
face : état de l'art

*Discussion: Facial microsurgical reconstruction: state
of the art*

• Table ronde : Techniques des transfert nerveux dans
la paralysie du plexus brachial

*Discussion: Techniques in nerve transfers in brachial
plexus palsy*

• Conférence d'enseignement : Techniques de base
en microchirurgie

Instructional course: Basic techniques in microsurgery

• Conférence d'enseignement : Enseignement en
microchirurgie : quel avenir ?

*Instructional course: Education in microsurgery : what
the future ?*

• Conférences d'enseignement : Couverture des
membres par lambeau libres


Instructional course: Limb cover with free flaps

• Conférences d'enseignement : Technique avancées
en microchirurgie : le transfert de pulpe digitale

*Instructional course: Advanced technique in
microsurgery : finger pulp reconstruction*

• Communications libres / Free papers

Soumettez votre abstract / Submit your abstract



EWAS LONDON MEETING
10th DECEMBER 2015 at the Royal College of Surgeons in London

Interventional Wrist Arthroscopy: indications, techniques and new developments

[I WISH TO REGISTER](#) [PROGRAM AT A GLANCE](#)

If you have not registered yet but are interested you can [click here](#) for further information or register directly using the link at the top of this letter.

StudioProgress is at your disposal for any further information you may require.

We are looking forward to meeting you in London.
Best regards,

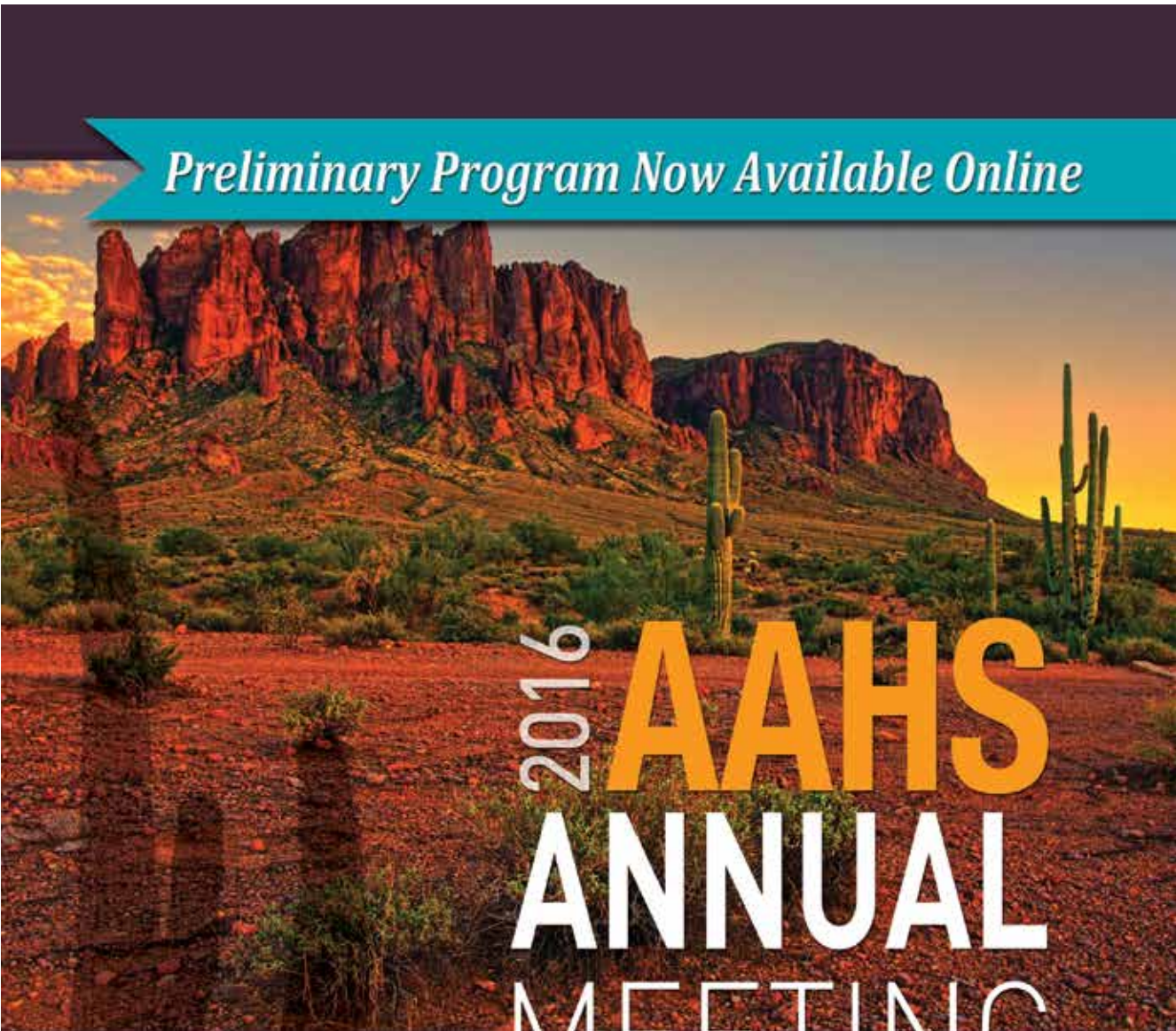
The Organizing Secretariat
StudioProgress Snc
Paola Valerio

StudioProgress snc - Via Cattaneo, 51 25121 Brescia, Italy
Tel: +39(0)30 290326 - Fax: +39(0)30 2809839
E-mail: info@studioprogress.it - Web: www.studioprogress.it




FESSH SANTANDER 2016
22nd - 25th June, 2016 - Santander Exhibition Centre


[Looking forward to welcoming you in Santander!!](#)



Preliminary Program Now Available Online

2016 AAHS ANNUAL MEETING
January 13-16, 2016

 American Association for Hand Surgery

 The German Society for Hand Surgery

www.handsurgery.org Westin Kierland Hotel • Scottsdale, Arizona

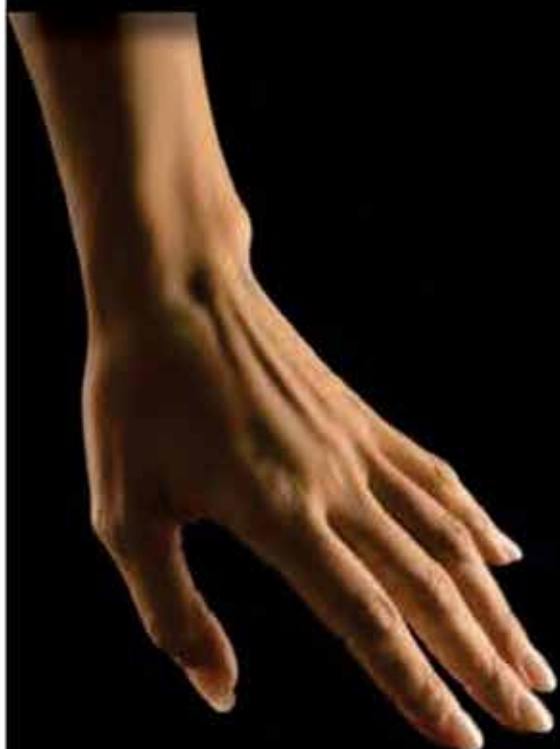BRUSSELS HAND/UPPER LIMB INTERNATIONAL SYMPOSIUM

Genval
Brussels, Belgium
January 29-30, 2016

24th year



**PAIN AND FUNCTIONAL IMPAIRMENT
AFTER HAND/UPPER EXTREMITY
SURGERY – CAUSES, PREVENTION,
MANAGEMENT, AND REHABILITATION**



Call for papers

**JOIN US
NEXT YEAR!!**

www.brusselhandsymposium.eu



Giorgio Brunelli Foundation for the Research on Spinal Cord Injuries NGO

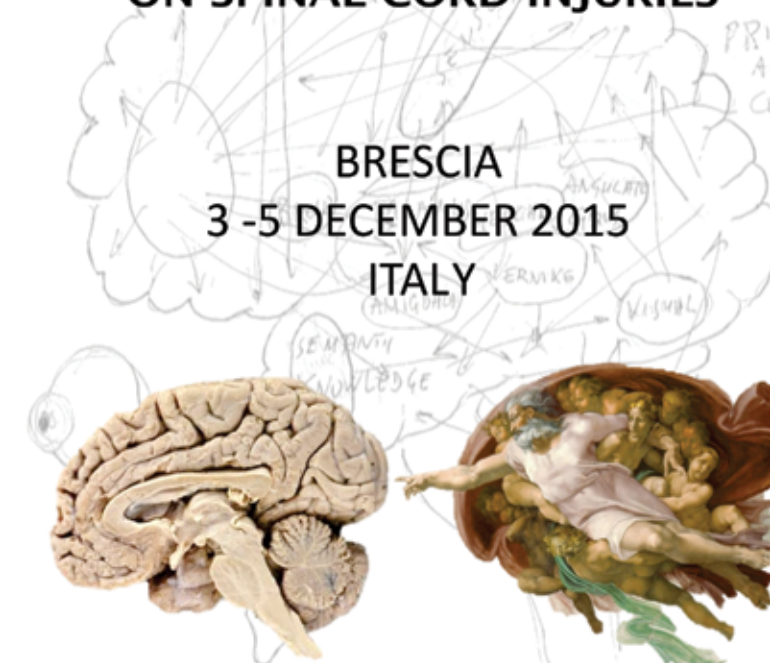

University of Brescia

INVITATION

IX
INTERNATIONAL SYMPOSIUM
ON SPINAL CORD INJURIES

BRESCIA
3 -5 DECEMBER 2015
ITALY



www.midollospinale.com

Organising Secretariat

Giorgio Brunelli Foundation
Località Campiani 77 – 25060 Cellatica (BS)
Phone +39 030 3385141
Fax +39 030 3387595
E-mail: segreteria@midollospinale.com
Website: www.midollospinale.com

Studio Progress S.N.C.
Via C. Cattaneo 51 – 25121 Brescia
Phone +39 030 290326
E-mail: info@studioprogress.it
Website: www.studioprogress.com