

Clinical update

# The future of transcatheter mitral valve interventions: competitive or complementary role of repair vs. replacement?

Francesco Maisano<sup>1\*</sup>, Ottavio Alfieri<sup>2</sup>, Shmuel Banai<sup>3</sup>, Maurice Buchbinder<sup>4</sup>, Antonio Colombo<sup>2</sup>, Volkmar Falk<sup>5</sup>, Ted Feldman<sup>6</sup>, Olaf Franzen<sup>7</sup>, Howard Herrmann<sup>8</sup>, Saibal Kar<sup>9</sup>, Karl-Heinz Kuck<sup>10</sup>, Georg Lutter<sup>11</sup>, Michael Mack<sup>12</sup>, Georg Nickenig<sup>13</sup>, Nicolo Piazza<sup>14</sup>, Mark Reisman<sup>15</sup>, Carlos E. Ruiz<sup>16</sup>, Joachim Schofer<sup>17</sup>, Lars Søndergaard<sup>7</sup>, Gregg W. Stone<sup>18</sup>, Maurizio Taramasso<sup>1</sup>, Martyn Thomas<sup>19</sup>, Alec Vahanian<sup>20</sup>, John Webb<sup>21</sup>, Stephan Windecker<sup>22</sup>, and Martin B. Leon<sup>18</sup>

<sup>1</sup>University Hospital of Zurich, Rämistrasse 100, 8089-CH, Zurich, Switzerland; <sup>2</sup>San Raffaele University Hospital, Milan, Italy; <sup>3</sup>Tel-Aviv Medical Center, Tel-Aviv, Israel; <sup>4</sup>Foundation for Cardiovascular Medicine, San Diego, USA; <sup>5</sup>Deutsches Herzzentrum Berlin, Berlin, Germany; <sup>6</sup>Evanston Hospital, Evanston, USA; <sup>7</sup>Rigshospitalet, Copenhagen, Denmark; <sup>8</sup>Perelman School of Medicine, University of Pennsylvania, Philadelphia, USA; <sup>9</sup>Cedars Sinai Medical Center, Los Angeles, USA; <sup>10</sup>Asklepios Klinik St. Georg, Hamburg, Germany; <sup>11</sup>University of Kiel, Kiel, Germany; <sup>12</sup>The Heart Hospital, Plano, USA; <sup>13</sup>University of Bonn, Bonn, Germany; <sup>14</sup>McGill University Health Centre, Montreal, Canada; <sup>15</sup>University of Washington Medical Center, Washington, USA; <sup>16</sup>Lenox Hill Heart and Vascular Institute of New York, New York, USA; <sup>17</sup>Hamburg University Cardiovascular Center, Hamburg, Germany; <sup>18</sup>Columbia University Medical Center, New York Presbyterian Hospital, New York, USA; <sup>19</sup>Guy's & St Thomas' Hospitals NHS Foundation Trust, London, UK; <sup>20</sup>Bichat Hospital, Paris, France; <sup>21</sup>St. Paul's Hospital, University of British Columbia, Vancouver, Canada; and <sup>22</sup>Bern University Hospital, Bern, Switzerland

Received 13 December 2014; revised 11 March 2015; accepted 23 March 2015; online publish-ahead-of-print 13 April 2015

Transcatheter mitral interventions has been developed to address an unmet clinical need and may be an alternative therapeutic option to surgery with the intent to provide symptomatic and prognostic benefit. Beyond MitraClip therapy, alternative repair technologies are being developed to expand the transcatheter intervention armamentarium. Recently, the feasibility of transcatheter mitral valve implantation in native non-calcified valves has been reported in very high-risk patients. Acknowledging the lack of scientific evidence to date, it is difficult to predict what the ultimate future role of transcatheter mitral valve interventions will be. The purpose of the present report is to review the current state-of-the-art of mitral valve intervention, and to identify the potential future scenarios, which might benefit most from the transcatheter repair and replacement devices under development.

## Keywords

Transcatheter mitral intervention • Transcatheter mitral repair • Transcatheter mitral implantation

## Introduction

Mitral regurgitation (MR) affects almost 10% of individuals over 75 years of age.<sup>1</sup> Open-heart surgery is the gold standard for the treatment of severe MR as excellent outcomes can be achieved in most patients, often adopting minimally invasive approaches. However, in up to 50% of patients with severe MR surgical treatment is not performed owing to increased risk related to comorbidities.<sup>2</sup> Transcatheter mitral interventions may be an alternative therapeutic option,<sup>3,4</sup> Transcatheter edge-to-edge repair with the MitraClip system (Abbott Vascular Inc, Menlo Park, CA, USA) has demonstrated safety and efficacy in different clinical settings.<sup>3,4</sup> Additional repair

and replacement technologies are being developed to expand the transcatheter intervention armamentarium (Tables 1 and 2).<sup>5</sup> Transcatheter mitral valve implantation (TMVI) with transcatheter aortic valve implantation (TAVI) prostheses has been performed in patients with surgical degenerated bioprostheses or with recurrent MR following annuloplasty.<sup>6,7</sup> Recently, few cases of TAVI prostheses implanted in a calcified native valve have been reported.<sup>8,9</sup> The feasibility of TMVI in native non-calcified valves has been recently reported in very high-risk patients, mainly with functional MR (FMR).<sup>10</sup>

Acknowledging the lack of scientific evidence to date, it is difficult to predict what the ultimate future role of transcatheter mitral valve interventions will be. The purpose of the present report is to review

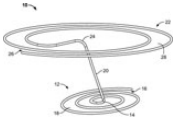
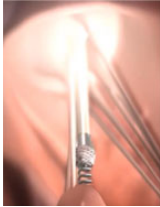
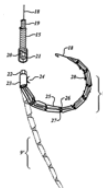


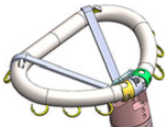

\*Corresponding author. Email: francesco.maisano@usz.ch

**Table 1** Transcatheter mitral valve repair technology under development

Device name and therapy type	Device structure	Status international	Description
MitraClip (Abbot Vascular) Edge-to-edge repair		CE Mark approval gained FDA approved	<ul style="list-style-type: none"> <li>– Percutaneous mitral repair based on Alfieri edge-to-edge surgical approach, designed for both degenerative and FMR.</li> <li>– Features a tiny V-shaped clip.</li> <li>– Indication requested for FDA approval is significant symptomatic DMR in presence of prohibitive risk for mitral valve surgery</li> </ul>
NeoChord (NeoChord DS1000) Chordal repair		CE Mark approval gained	<ul style="list-style-type: none"> <li>– Instrumentation used to enable beating heart, transapical approach, mitral valve repair by artificial chordae implantation</li> <li>– Designed for leaflet prolapse</li> </ul>
V-Chordal-Off Pump (Valtech) Chordal repair		First-in-man study complete	<ul style="list-style-type: none"> <li>– Sutureless implantation of neochordae on the leaflets under direct surgical exposure</li> <li>– Off-pump, the chordal length can be adjusted under live echo guidance, on beating heart</li> </ul>
CARILLON (Cardiac Dimensions) Indirect Annuloplasty		CE Mark approval gained IDE submitted for pivotal study	<ul style="list-style-type: none"> <li>– Implantable mitral annular constraint device percutaneously placed into the coronary sinus and great cardiac vein</li> <li>– Constructed of nitinol wire with distal and proximal anchors connected by an intervening cable</li> <li>– Designed specifically for heart failure patients with significant MR due to mitral annular enlargement</li> </ul>
GDS Accucinch (GDS) Direct Annuloplasty		International feasibility trial underway	<ul style="list-style-type: none"> <li>– Catheter-based delivery of a sub-valvular left ventricular reshaping (ventriculoplasty) system designed to reshape and resize the left ventricular base</li> <li>– Re-establish native mitral valve geometry while preserving native leaflet function, and restore leaflet coaptation</li> </ul>
Mitralign Bident (Mitralign) Direct annuloplasty		CE Mark trial completed US feasibility trial planned	<ul style="list-style-type: none"> <li>– Transcatheter annuloplasty for mitral repair</li> <li>– Involves delivery of polyester pledgets via LV through posterior mitral annulus</li> <li>– Pledgets are plicated and locked directly on the annulus</li> </ul>
Cardioband TF (Valtech) Direct annuloplasty		CE Mark trial underway	<ul style="list-style-type: none"> <li>– An adjustable, sutureless posterior annuloplasty band implanted through transfemoral transeptal route</li> <li>– Designed to reduce the septo-lateral annular diameter</li> </ul>
Millipede Ring (Millipede) Direct annuloplasty		Preclinical underway	Nitinol ring designed for tricuspid or mitral valve repair
Cardica Mitral Repair (Cardica) Edge-to-edge repair		Intellectual property developed	Catheter-based treatment for MR featuring a clip that holds together the leaflets of the mitral valve

Continued

**Table 1 Continued**

Device name and therapy type	Device structure	Status international	Description
MISTRAL (Mitratrix) Chordal repair		Preclinicals underway	<ul style="list-style-type: none"> <li>– Transseptally delivered (12 Fr catheter) implant (3D Nitinol spiral-shaped atraumatic wire) for mitral valve repair via chord grasping</li> <li>– This is Mitratrix's 1st product</li> </ul>
V-Chordal-Transfemoral (Valtech) Chordal repair		Preclinicals underway	<ul style="list-style-type: none"> <li>– Transfemoral chord repair performed via transfemoral approach that is off-pump on a beating heart</li> </ul>
Kardium MR (Kardium) Direct annuloplasty		Intellectual property developed	<ul style="list-style-type: none"> <li>– Kardium is developing a percutaneous device for treating mitral valve regurgitation</li> </ul>
PS3 (MVRx) Annuloplasty		First-in-man study underway	<ul style="list-style-type: none"> <li>– Direct leveraged transatrial shortening of the septo-lateral dimension of the mitral valve by providing two anchor points that are tensioned together</li> </ul>
MitraFlex (TransCardiac) Edge-to-edge		Preclinicals underway	<ul style="list-style-type: none"> <li>– Instruments for minimally invasive transapical mitral valve repairs</li> </ul>
ValCare MV Repair (ValCare) Direct annuloplasty		Preclinicals underway	<ul style="list-style-type: none"> <li>– A rigid, 'D-shape' annuloplasty ring that is delivered in a transcatheter approach to reduce MR and stabilize the mitral annulus for functional and degenerative MR</li> </ul>
Mitra-Spacer-Transapical (Cardiosolutions) Enhanced coaptation		First-in-man study underway	<ul style="list-style-type: none"> <li>– Catheter-based mitral valve spacer to reduce MR improving leaflet coaptation</li> <li>– Implanted through transapical approach</li> </ul>

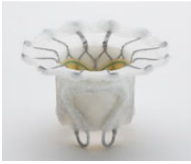



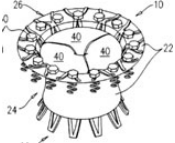
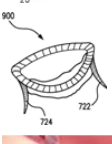




the current state-of-the-art of mitral valve intervention, and to identify the potential future scenarios, which might benefit most from the transcatheter repair and replacement devices under development.

### Transcatheter mitral valve implantation vs. repair: two philosophies

Whereas mitral valve repair is currently the most widely used approach for transcatheter interventions for MR, TMVI offers several theoretical advantages. Transcatheter mitral valve implantation is



potentially applicable to a greater proportion of patients; there is a hope that TMVI could provide the concept of 'one valve fits all', MR reduction may be more predictable, and the procedure may be less technically demanding and easier to learn. However, due to procedural and design challenges to TMVI, complications may be more catastrophic and less forgiving, while transcatheter mitral valve repair (TMVRep) may be associated with a superior safety profile as it involves a less marked change in valve anatomy and physiology. Repair does not entail a heterologous tissue implant, the related supporting structure does not require anti-coagulation, and it has been a general conclusion in the surgical experience that repair has advantages over valve replacement. The major limitation of TMVRep is

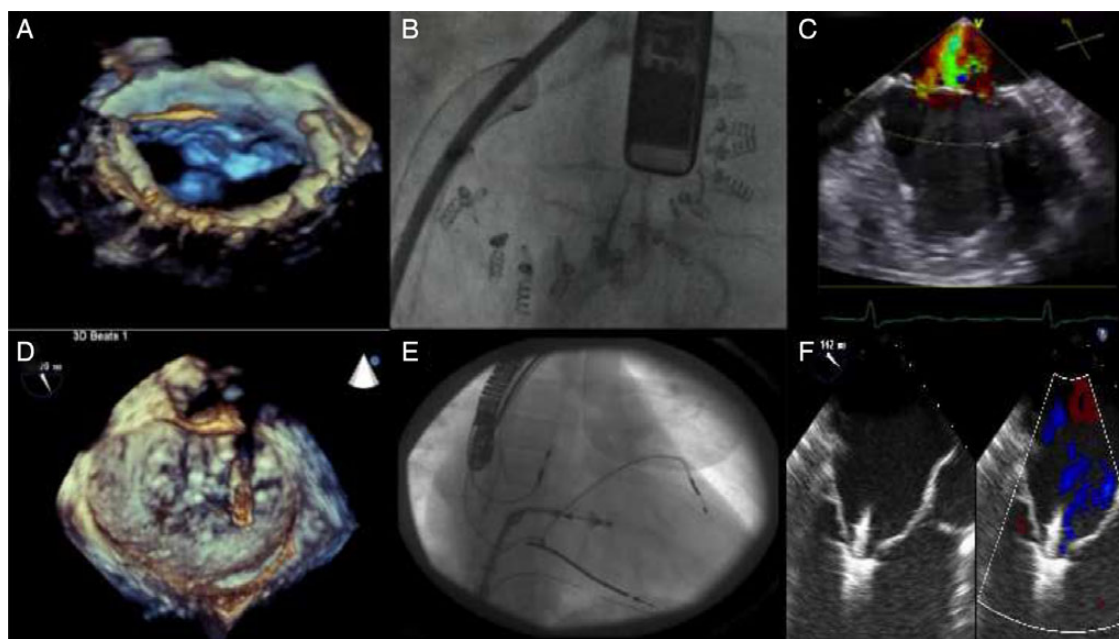
**Table 2** Transcatheter mitral valve implantation technology under development

Device name	Device structure	Status international	Description
Fortis (Edwards Lifesciences)		First-in-man study underway	<ul style="list-style-type: none"> <li>– Mitral valve replacement technology designed to minimize <i>para</i>-valvular leak</li> <li>– Initial version being studied in first-in-man has a transapical delivery system</li> </ul>
Tiara (Neovasc)		First-in-man study underway	<ul style="list-style-type: none"> <li>– Self-expanding bovine pericardial, D-shaped trileaflet mitral valve implanted using a transapical delivery system</li> <li>– It is anchored to the mitral annulus</li> <li>– A transfemoral delivery system is also in development</li> </ul>
TMVI-TA (CardiAQ)		First-in-man study completed	<ul style="list-style-type: none"> <li>– Self-positioning, self-anchoring, and self-conforming system for transcatheter mitral valve implantation through transapical approach</li> </ul>
TMVI-TF (CardiAQ)		First-in-man study completed	<ul style="list-style-type: none"> <li>– Self-positioning, self-anchoring, and self-conforming system for transcatheter mitral valve implantation</li> <li>– 2nd-generation device has been developed; this profile covers transfemoral version</li> </ul>
Caisson TMVR (Caisson)		Preclinical studies underway	<ul style="list-style-type: none"> <li>– Mitral valve replacement system with a transfemoral delivery system</li> </ul>
MitraCath (Emory University)		In development	<ul style="list-style-type: none"> <li>– Technology that enables the placement of a stent-mounted bioprosthetic heart valve in the mitral position</li> </ul>
HighLife Mitral Valve Replacement (HighLife)		Preclinical studies underway	<ul style="list-style-type: none"> <li>– Percutaneous mitral valve replacement technology with a transatrial delivery system</li> </ul>
Medtronic TMVR (Medtronic)		Preclinical studies underway	<ul style="list-style-type: none"> <li>– Self-expanding nitinol scaffold and a bovine pericardium valve with three cusps</li> <li>– Designed for fixation with the native mitral annulus</li> </ul>
MitrAssist Valve (MitrAssist)		Preclinical studies underway	<ul style="list-style-type: none"> <li>– A mitral valve that fits into the existing mitral valve</li> <li>– Delivered through a small-diameter catheter</li> <li>– For all forms of mitral regurgitation</li> </ul>
Navigate TMVR (NCSI)		Clinical implants have occurred	<ul style="list-style-type: none"> <li>– Self-expandable mitral valve replacement device featuring a nitinol stent and dehydrated tissue for treatment of functional mitral regurgitation</li> <li>– Transatrial, transapical, and transeptal versions are also in development</li> </ul>

Continued

**Table 2 Continued**

Device name	Device structure	Status international	Description
Tendyne/Lutter TMVR (Tendyne)		First-in-man study underway	<ul style="list-style-type: none"> <li>Self-expanding, transapical approach to mitral valve replacement</li> <li>System involves neochords with left ventricular apical tethering for fixation</li> </ul>
Cardiovalve (Valtech)		Preclinical studies underway	<ul style="list-style-type: none"> <li>Mitral valve replacement system that can be delivered using a transfemoral delivery system in a two-step replacement procedure</li> </ul>



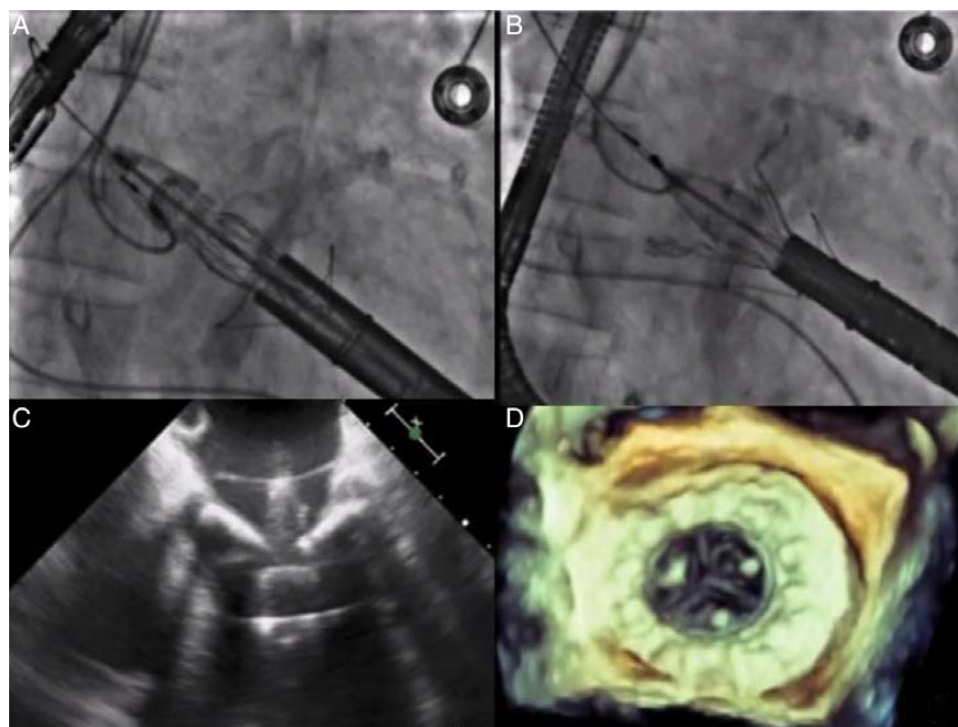
**Figure 1** Fluoroscopic and echocardiographic imaging guidance of transcatheter mitral repair procedures. Most transcatheter mitral repair procedures are technically demanding and require advanced integrated 3D echocardiographic guidance. (A, B, and C) The three-dimensional echocardiography, the fluoroscopic view, and the intercommissural two-dimensional echocardiography views of a direct annuloplasty procedure with the Cardioband, respectively. (D, E, and F) Three-dimensional echocardiography, the fluoroscopic view, and two-dimensional colour-comparing echocardiography views of during MitraClip implantation.

that MR reduction is less predictable and MR may persist or reoccur. Recurrence could be greater in FMR, due to further remodelling<sup>11</sup> or to poor patient selection. In addition, operators may need to master multiple transcatheter repair techniques to manage the wide variability of mitral disease, and the need to combine different devices in some patients to approximate a complete surgical repair (Figures 1 and 2).

Given the advantages and disadvantages of these two approaches, a patient-specific decision-making algorithm for the optimal device choice will likely be required.

### Mitral valve apparatus physiology: the valve as an integrated component of the left ventricle

The mitral valve is not simply just a valve, it is rather a complex apparatus integrated in the left ventricle (LV), including the annulus, the leaflets, the chordae, the papillary muscles, and the ventricle itself. Beyond its obvious haemodynamic function to ensure forward cardiac output, the mitral apparatus plays a fundamental role in the



**Figure 2** Fluoroscopic and echocardiographic imaging guidance of transcatheter mitral valve implantation with the Fortis bioprosthesis (Edwards Lifesciences). When compared with transcatheter mitral valve repair, reproducibility of transcatheter mitral valve implantation may be higher and the learning curve may be shorter. (A and B) Two steps of the Fortis valve deployment under fluoroscopic guidance; (C) The phase of leaflet capture at bidimensional echocardiography; (D) The final implantation at three-dimensional echocardiography.

structural and functional integrity of the LV. Discontinuation of the mitral-ventricular continuity results in maladaptive remodelling and impaired LV performance.<sup>12</sup> In patients with FMR and severely depressed LV function, contractility of the base of the LV is a key contributor to cardiac output; as a consequence, in patients with prosthetic mitral valve, the fixation of the prosthesis to the annulus may lead to a global reduction in contractility.<sup>13</sup>

The mitral valve plays a fundamental role in the demarcation of the inflow–outflow ventricular tracts, and regulates the flow pattern within the LV. Its fluid-dynamic function prevents energy loss and optimizes fluid–structure interaction.<sup>14</sup> The anterior leaflet of the mitral valve acts as a rudder during the cardiac cycle to redirect flow towards the outflow tract in systole and towards the lateral wall in diastole,<sup>15</sup> generating a virtuous fluid vortex.<sup>16</sup> Loss of the vortex-like circulation is associated with loss of energy, increased LV stress and less efficient work.<sup>17–19</sup> Preservation of anterior leaflet mobility and asymmetric flow may be associated with better LV performance and may partially explain the loss of ventricular function following replacement.

## Mitral repair vs. replacement: lessons learned from surgical experience

A direct translation of the surgical experience to the transcatheter procedures is not always appropriate; however, lessons learned

from >50 years of surgery should not be neglected in the development of these new technologies.

Before extracorporeal circulation was available, several off-pump mitral repair techniques were attempted. With the introduction of cardiopulmonary bypass, an open-heart direct access approach and the development of mechanical prostheses, early repair was used progressively less often. Surgeons opted for valve replacement because it was easier to perform and more predictable. Soon the downsides of valve replacement became obvious: the need for anti-coagulation, risk of thromboembolism, prosthetic endocarditis, and impaired LV-function to name a few. Therefore, valve repair re-emerged as the preferred surgical treatment for degenerative MR (DMR) due to improved outcomes.<sup>20–22</sup>

In current surgical practice, replacement and repair are complementary rather than competitive. According to guidelines, surgical repair should be performed whenever feasible and early intervention is warranted when durability is predicted.<sup>23,24</sup> Conversely, valve replacement may be considered as replacing one disease state (native valve MR) with another (prosthesis), since the ideal prosthesis has not been developed (Table 3). The advantages of repair over replacement are more evident in patients with DMR: in these patients timely surgical repair restores life-expectancy and provides quality of life similar to an age-matched general population,<sup>20,21</sup> results that are not realized with a prosthesis,<sup>25</sup> even in elderly and high-risk patients.<sup>26,27</sup>

In this regard, although mitral valve repair may be more respectful of the innate physiology, and avoids prosthesis-related complications,

**Table 3** The ideal prosthetic valve

The (non-existing) ideal valve prosthesis
Simple and reproducible implant (high immediate success rate with absent MR)
Absence of transvalvular gradient
Absence of peri-valvular regurgitation
No LVOT, coronary sinus, or LCX obstruction
Preservation of LV contractility, haemodynamics, and blood flow pattern
Non-thrombogenic (no need for chronic anti-coagulation)
Low infection rates
No acute or delayed embolization
Durable
Ability to grow (in paediatric patients)

MR, mitral regurgitation; LVOT, left ventricle outflow tract; LCX, left circumflex coronary artery; LV, left ventricle.

careful patient selection (and operator experience) plays a key role in achieving ideal initial and sustained outcomes.

Conversely, the benefits of surgical repair in patients with FMR are less clear: in secondary MR prognosis is dominated by the underlying LV dysfunction rather than the type of intervention.<sup>28,29</sup> Surgical replacement has traditionally been associated with higher early mortality due to less efficient preservation of LV function. However, these data arose from retrospective observational studies that were confounded by patient selection and other factors, including surgical expertise and technique.<sup>28,30,31</sup> In a large multicentre randomized trial comparing valve repair to chordal-sparing valve replacement in ischaemic FMR patients, Acker *et al.*<sup>11</sup> did not observe significant differences in LV reverse remodelling or survival at 1 year. Mitral valve replacement compared with repair provided a more durable correction of MR, although this was not associated with a substantial difference in clinical outcomes. An important limitation of the trial is that well established negative predictors for recurrence of MR after repair in the setting of FMR were not acknowledged. This outcome underlines the importance of patient selection to achieve durable results after TMVRep in FMR.<sup>32,33</sup> Although the study was not powered for mortality, peri-operative mortality favoured repair (1.6 vs. 4.0% 30-day mortality,  $P = 0.26$ ), consistent with a recent meta-analysis comparing replacement and repair in patients with ischaemic MR.<sup>34</sup>

## Unsolved technical issues with transcatheter mitral valve implantation and transcatheter mitral valve repair

From a pure technical standpoint, transcatheter repair and valve implantation have distinct challenges and advantages (Table 4).

In patients with chronic MR, the annulus is usually dilated, requiring large devices to obtain adequate fixation and sealing and large delivery systems, typically  $\geq 24F$ . Transfemoral retrograde and transseptal

**Table 4** Comparison of transcatheter mitral valve implantation and transcatheter mitral valve repair

TMVI	TMVRep
Advantages	
Simplicity	More natural haemodynamics
Versatility	No need for long-term anti-coagulation
Predictable results	Favourable safety profile
Challenges	
Dynamic mitral structure	Need for advanced imaging
Asymmetric anatomy	Variability of disease/need for multiple devices
Deliverability (profile, rigidity)	Possible need for combined therapies
Fixation (not relying on radial force)	Steeper learning curve
Need for chronic oral anti-coagulation (?)	Residual/recurrent regurgitation
Risk of LVOT, CS, and LCX obstruction	
Risk of <i>para</i> -valvular leak	

TMVI, transcatheter mitral valve implantation; TMVRep, transcatheter mitral valve repair; LVOT, left ventricle outflow tract; CS, coronary sinus; LCX, left circumflex coronary artery.

(transfemoral or transjugular) approaches for TMVI delivery may be challenging given the angulation involved and the dimensions and inflexibility of the devices. A direct transatrial approach is a possible alternative.<sup>35</sup> This approach, however, has been essentially abandoned because of sub-optimal coaxial alignment. The transapical approach assures optimal coaxial alignment; however, the LV wall in heart failure patients with FMR is thin, and the LV dilated, dysfunctional, and arrhythmogenic. Dedicated transapical closure devices are under development and may facilitate TMVI. Finally, patients with severely depressed LV systolic function may not tolerate prolonged deployment time or rapid pacing impairing haemodynamic stability.

Stable anchorage of the prosthesis to prevent displacement or migration while enduring continuous cyclical movements of the mitral annulus and the base of the LV as well as of the pressure gradients between the left atrium and LV is of extreme importance. Reliable fixation of the prosthesis is challenging; given the lack of heavy annular calcification in most patients, fixation methods relying solely on radial force are unlikely to be successful. Radial force also risks compression and damage of adjacent structures such as the LV outflow tract (LVOT), the conduction system, the coronary sinus, the left circumflex artery, and aortic root. Additional fixation elements are thus required to ensure proper fixation to the LV or to other components of the sub-valvular apparatus. Since *para*-valvular regurgitation may be less tolerable in the mitral position, the design of the transcatheter mitral prosthesis must aim at complete sealing.

The wide spectrum of anatomical variations underlying MR introduces further challenges for prosthesis fixation, delivery and sealing; not only are DMR and FMR anatomies different, but DMR includes a

wide spectrum of pathological derangements, ranging from Barlow's disease (in which the extreme excess of tissue may prevent optimal fixation) to fibroelastic deficiency with isolated segmental prolapse (in which the lack of tissue may not assure an adequate landing zone). The level of implantation and configuration of the bioprosthesis is crucial to minimize the risk of LVOT obstruction (with impaired outflow fluid dynamics), and left atrial protrusion (with impaired inflow fluid dynamics). The potential for erosion and device-related thrombus formation have yet to be defined.

Transcatheter mitral valve repair has its own series of challenges. Rarely, with current devices, TMVRep eliminates MR. The degree of MR reduction to achieve a substantial clinical benefit is still matter of concern, but it is obvious that the potential of TMVI for complete and predictable abolition of MR is appealing. However, in patients with FMR, a mild degree of residual MR after repair may mitigate the acute rise in overload and serve to decompress the LV, making the procedure safer for those with severe LV dysfunction. Further studies are necessary to examine this possibility.

Due to the wide anatomical variability of MR, physicians dedicated to transcatheter mitral interventions will likely need to develop expertise with more than one device. Most TMVRep approaches will require advanced imaging and specific skills,<sup>36,37</sup> which may limit their uptake, when compared with TMVI. Learning curve is longer in repair, similar to surgery,<sup>38,39</sup> and outcomes can be less predictable in the early operator/centre experience.

These challenges are counterbalanced by an inclination of TMVRep to be tolerable (as for MitraClip therapy), and associated to fast recovery. This may be especially important in heart failure patients with FMR.

Ultimately, it is most probably that, like with surgery, TMVRep and TMVI will be both complementary and competitive.

## Additional considerations: durability and need for anti-coagulation

Design constraints for transcatheter delivery may have an impact on tissue degeneration of TMVI. Durability of mitral tissue prostheses is a concern in surgery, especially in younger patients.<sup>40,41</sup> If transcatheter procedures aim to become a realistic alternative to surgery with expanded indications to treat a lower risk population, durability could become a major priority.

Durability is also an important issue for percutaneous mitral repair. In the EVEREST II trial, when acute procedural results were optimal, repair with the MitraClip was durable for 5 years.<sup>42</sup> However, with sub-optimal MR repair or MR recurrence, patient outcomes are poor.<sup>43–47</sup> In this regard, successful acute reduction of MR is necessary to provide durable results of TMVRep, suggesting that patients eligible for reconstructive procedures should be treated preferably in experienced centres, similar as for mitral surgery.<sup>48</sup>

A second unknown issue is whether TMVI patients will need or benefit from chronic anti-coagulation. Chronic anti-coagulation is associated with increased risk of haemorrhagic and thrombotic events.<sup>49,50</sup> If chronic anti-coagulation is required, TMVI may be less attractive for low-risk cohorts, if not otherwise indicated.

## Safety is key for an 'early indication' with transcatheter mitral procedures

Transcatheter mitral interventions are the natural evolution of modern mitral valve surgery; in the future, the indications may continue to move from a palliative target (improving symptoms, treating advanced and end-stage disease), towards the aim of improving prognosis. Early repair can restore life expectancy in DMR patients and lead to reverse remodelling in FMR patients.<sup>21,43,51</sup> Outcomes tend to be poor if mitral valve surgery is excessively delayed, and it is likely that transcatheter mitral procedures may similarly be unable to impact the prognosis if unduly postponed.<sup>52,53</sup>

In patients with severe MR and little or no symptoms, an excellent safety profile is mandatory if early repair is to be considered. Under these circumstances, like in surgery, a percutaneous repair may be favoured over TMVI due to potential disadvantages of a permanent implant. In this regard, there are numerous examples of therapies where safety has a dominant role over efficacy. For example, cardiac resynchronization therapy (CRT) in heart-failure patients is widely accepted given its excellent safety record. Even if clinical efficacy is achieved only in 60–70% of cases,<sup>54</sup> patients are still referred for CRT because the chance of improvement is associated with minimal risk.

## Conclusions: The future of transcatheter mitral interventions

At the moment, given the rapid evolution in device development, the complementary role of TMVRep and TMVI must be considered speculative. In general terms, TMVI is likely to be technically simpler and more reproducible in terms of MR reduction. However, durability, safety and disruption of adjacent cardiac structures remain important concerns. Transcatheter mitral valve repair is more complex and likely carries a steeper learning curve, and individual device may be applicable only in selected patients with less predictable MR reduction. Of note, the safety profile of TMVRep is generally excellent, and durability is likely to be robust in most patients when acute procedural success is achieved and the impact of TMVRep on physiology is minimal. Therefore, TMVRep may in the future aspire to an early treatment option, aiming at a prognostic approach, if randomized trials can demonstrate equipoise in long-term outcomes when compared with minimally invasive mitral valve repair.

In low-risk DMR patients, surgical repair will remain the standard of care for many years, with TMVRep and TMVI playing a role in high-risk or inoperable patients, who are not amenable for minimally invasive surgical mitral valve repair or eventually for TMVRep.

In patients with severe FMR, the role of surgery is less well established in patients who are not candidates for CABG, and most patients are treated medically. Transcatheter mitral valve repair may be a safe, palliative approach for such patients, and several large-scale randomized ongoing trials investigate the effectiveness of the MitraClip in this scenario. Transcatheter mitral valve implantation may potentially be a therapeutic option for patients with more advanced disease and severe anatomical and functional abnormalities, who are not eligible for valve repair.



In the future, careful patient selection will play a fundamental role in identifying specific patients most likely to benefit from TMVI vs. TMVRep vs. mitral valve surgery. Pre-procedural imaging will play a leading role to guide the complex process of patient selection. Some procedures may become complementary (i.e. surgical mitral annuloplasty and subsequent TMVI, or a combination of different TMVRep approaches in the same patients with staged procedures). As an example, the addition of transcatheter annuloplasty to MitraClip therapy may improve acute efficacy and long-term durability. However timing, indications and sequence of procedures is speculative at the moment. Conversely, certain procedures may preclude others (i.e. following TMVI there are no options for further repair, and a transcatheter edge-to-edge repair may preclude future TMVI). The role of LV remodelling approaches has yet to be defined.

The development of TMVRep techniques has already taken 15 years, and transcatheter valve implantation technology will likely require more time until the devices and implant procedure are optimized. In the meantime, there may be room for both surgery and current TMVRep devices.

In the future, focus should be placed in designing and testing new devices, improving imaging guidance, and then carefully evaluate the risks and benefits of each promising approach in individual patients in varying clinical settings, ultimately relying on randomized trial evidence to guide clinical decision-making of the heart team.

**Conflict of interest:** F. Maisano is Consultant for Abbott Vascular, ValtechCardio, Medtronic, Edwards Lifesciences, St Jude, Apica, Founde rof 4Tech, receives royalties from Edwards Lifesciences; O. Alfieri received research grants from Valtech Cardio; S. Banai is Medical Director of Neovasc Inc.; M. Buchbinder declares financial relationships with Abbott Vascular, Medtronic, BSC, MValve, Micardia; A. Colombo is Minor shareholder of Direct Flow Inc.; V. Falk received research grants from Valtech Cardio; T. Feldman received grant support from Abbott,Vascular, BSC, Edwards, WL Gore and is Consultant for : Abbott Vascular, BSC, Coherex, Edwards, Jena-Valve, DaiichiSankyo-Lilly, WL Gore; O. Franzen received speakers fee from Abbott Vascular, St. Jude, Medtronic, Astra Zeneca, Boston Scientific, Gore, Edwards, and research grant from Abbott Vascular, St. Jude, Medtronic; H. Herrmann is a consultant for and has equity in Micro Interventional Devices; S. Kar declares financial relationships with Abbott Vascular, Atritech, AGA Medical, St Jude Medical, Circulite, Coherex, Gore; KH Kuck declares financial relationships with Biosense Webster, Stereotaxis, Medtronic, St. Jude, Cardiofocus, Abbott Vascular, Edwards, Mitralign, BMDSys, ACT, Maya, Apama, Topera, Recor, Endosense, SynapticMed, CardiacImplants, Biotronik; G. Lutter is a consultant for Tendyne Inc.; M. Mack ave received travel reimbursements from Edwards Lifesciences; G. Nickenig declares financial relationships with AGA, AstraZeneca, Bayer, Berlin Chemie, Biotronic, BMS, Boehringer Ingelheim, Daiichi Sankyo, Cordis, Medtronic, Novartis, Pfizer, Sanofi Aventis, Abbott Vascular; N. Piazza declares relationships with Medtronic, CardiaQ, HighLife, St. Jude Medical; M. Reisman declares relationships with Boston Scientific, Biostar Ventures; CE Ruiz declare relationships with Philips, Valtech, St.JudeMedical, Sorin, Gore, Vascular Therapies, MitrAssist, Entourage, BioInspire; J. Schofer is Consultant for Guided Delivery System, Cardiac Dimension, Mitralign; L. Søndergaard is a consultant for CardiaQ; G. Stone

declares relationships with Micardia and Guided Delivery Systems; M. Thomas declares relationships with Edwards Lifesciences, Boston Scientific; A. Vahanian is Consultant for Edwards, Medtronic, Abbott Vascular ,Valtech Cardio; J. Webb is Consultant for Neovasc Inc.; MB Leon declares relationships with Abbott Vascular, Boston Scientific, Edwards Lifescience, Medtronic, Meril Lifescience, Micell, Laret, Elixir, GDS, Medinol, Mitralign, and Valve Medical.

## References

1. Nkomo VT, Gardin JM, Skelton TN, Gottdiener JS, Scott CG, Enriquez-Sarano M. Burden of valvular heart diseases: a population-based study. *Lancet* 2006;**368**: 1005–1011.
2. Mirabel M, lung B, Baron G, Messika-Zeitoun D, Detaint D, Vanoverschelde JL, Butchart EG, Ravaud P, Vahanian A. What are the characteristics of patients with severe, symptomatic, mitral regurgitation who are denied surgery? *Eur Heart J* 2007;**28**:1358–1365.
3. Maisano F, Franzen O, Baldus S, Schafer U, Hausleiter J, Butter C, Ussia GP, Sievert H, Richardt G, Widder JD, Moccetti T, Schillinger W. Percutaneous mitral valve interventions in the real world: early and 1-year results from the ACCESS-EU, a prospective, multicenter, nonrandomized post-approval study of the MitraClip therapy in Europe. *J Am Coll Cardiol* 2013;**62**:1052–1061.
4. Lim DS, Reynolds MR, Feldman T, Kar S, Herrmann HC, Wang A, Whitlow PL, Gray WA, Grayburn P, Mack MJ, Glower D. Improved functional status and quality of life in prohibitive surgical risk patients with degenerative mitral regurgitation following transcatheter mitral valve repair with the MitraClip(R) system. *J Am Coll Cardiol* 2014;**64**:182–192.
5. Maisano F, Buzzatti N, Taramasso M, Alfieri O. Mitral transcatheter technologies. *Rambam Maimonides Med J* 2013;**4**:e0015.
6. Descoutures F, Himbert D, Maisano F, Casselman F, de Weger A, Bodea O, Van der Kley F, Colombo A, Giannini C, Rein KA, De Bruyne B, Petronio AS, Dahle G, Alfieri O, Vahanian A. Transcatheter valve-in-ring implantation after failure of surgical mitral repair. *Eur J Cardiothorac Surg* 2013;**44**:e8–e15.
7. Cheung A, Al-Lawati A. Transcatheter mitral valve-in-valve implantation: current experience and review of literature. *Curr Opin Cardiol* 2013;**28**:181–186.
8. Fassa AA, Himbert D, Brochet E, Depoix JP, Cheong AP, Alkholder S, Nataf P, Vahanian A. Transseptal transcatheter mitral valve implantation for severely calcified mitral stenosis. *JACC Cardiovasc Interv* 2014;**7**:696–697.
9. Hasan R, Mahadevan VS, Schneider H, Clarke B. First in human transapical implantation of an inverted transcatheter aortic valve prosthesis to treat native mitral valve stenosis. *Circulation* 2013;**128**:e74–e76.
10. De Backer O, Piazza N, Banai S, Lutter G, Maisano F, Herrmann HC, Franzen OW, Søndergaard L. Percutaneous transcatheter mitral valve replacement: an overview of devices in preclinical and early clinical evaluation. *Circ Cardiovasc Interv* 2014;**7**: 400–409.
11. Acker MA, Parides MK, Perrault LP, Moskowitz AJ, Gelijs AC, Voisine P, Smith PK, Hung JW, Blackstone EH, Puskas JD, Argenziano M, Gammie JS, Mack M, Ascheim DD, Bagiella E, Moquete EG, Ferguson TB, Horvath KA, Geller NL, Miller MA, Woo YJ, D'Alessandro DA, Ailawadi G, Dagenais F, Gardner TJ, O'Gara PT, Michler RE, Kron IL, Ctsn. Mitral-valve repair versus replacement for severe ischemic mitral regurgitation. *N Engl J Med* 2014;**370**:23–32.
12. Sarris GE, Fann JI, Niczyporuk MA, Derby GC, Handen CE, Miller DC. Global and regional left ventricular systolic performance in the in situ ejecting canine heart. Importance of the Mitral Apparatus. *Circulation* 1989;**80**(3 Pt 1):124–142.
13. Candan O, Ozdemir N, Aung SM, Bakal RB, Gecmen C, Akpinar SH, Cem D, Onur O, Kaymaz C. Effect of mitral valve repair versus replacement on left ventricular rotational deformation: a study with speckle tracking echocardiography. *J Heart Valve Dis* 2013;**22**:651–659.
14. Yacoub MH, Cohn LH. Novel approaches to cardiac valve repair: from structure to function: Part I. *Circulation* 2004;**109**:942–950.
15. Kilner PJ, Yang GZ, Wilkes AJ, Mohiaddin RH, Firmin DN, Yacoub MH. Asymmetric redirection of flow through the heart. *Nature* 2000;**404**:759–761.
16. Charonko JJ, Kumar R, Stewart K, Little WC, Vlachos PP. Vortices formed on the mitral valve tips aid normal left ventricular filling. *Ann Biomed Eng* 2013;**41**: 1049–1061.
17. Machler H, Reiter G, Perthel M, Reiter U, Bergmann P, Zink M, Rienmuller R, Laas J. Influence of a tilting prosthetic mitral valve orientation on the left ventricular flow – an experimental in vivo magnetic resonance imaging study. *Eur J Cardiothorac Surg* 2007;**32**:102–107.
18. Kim WY, Walker PG, Pedersen EM, Poulsen JK, Oyre S, Houliand K, Yoganathan AP. Left ventricular blood flow patterns in normal subjects: a quantitative analysis by three-dimensional magnetic resonance velocity mapping. *J Am Coll Cardiol* 1995; **26**:224–238.

19. Pedrizzetti G, La Canna G, Alfieri O, Tonti G. The vortex—an early predictor of cardiovascular outcome? *Nat Rev Cardiol* 2014;**11**:545–553.
20. Ling LH, Enriquez-Sarano M, Seward JB, Orszulak TA, Schaff HV, Bailey KR, Tajik AJ, Frye RL. Early surgery in patients with mitral regurgitation due to flail leaflets: a long-term outcome study. *Circulation* 1997;**96**:1819–1825.
21. Detaint D, Sundt TM, Nkomo VT, Scott CG, Tajik AJ, Schaff HV, Enriquez-Sarano M. Surgical correction of mitral regurgitation in the elderly: outcomes and recent improvements. *Circulation* 2006;**114**:265–272.
22. Yun KL, Miller DC. Mitral valve repair versus replacement. *Cardiol Clin* 1991;**9**:315–327.
23. Joint Task Force on the Management of Valvular Heart Disease of the European Society of C, European Association for Cardio-Thoracic S, Vahanian A, Alfieri O, Andreotti F, Antunes MJ, Baron-Esquiva G, Baumgartner H, Borger MA, Carrel TP, De Bonis M, Evangelista A, Falk V, lung B, Lancellotti P, Pierard L, Price S, Schafers HJ, Schuler G, Stepinska J, Swedberg K, Takkenberg J, Von Oppell UO, Windecker S, Zamorano JL, Zembala M. Guidelines on the management of valvular heart disease (version 2012). *Eur Heart J* 2012;**33**:2451–2496.
24. Nishimura RA, Otto CM, Bonow RO, Carabello BA, Erwin JP 3rd, Guyton RA, O’Gara PT, Ruiz CE, Skubas NJ, Sorajja P, Sundt TM 3rd, Thomas JD. 2014 AHA/ACC guideline for the management of patients with valvular heart disease: executive summary: a report of the American College of Cardiology/American Heart Association Task Force on Practice Guidelines. *J Am Coll Cardiol* 2014;**63**:2438–2488.
25. Puvimanasinghe P, Steyerberg EW, Takkenberg JJ, Eijkemans MJ, van Herwerden LA, Bogers AJ, Habbema JD. Prognosis after aortic valve replacement with a bioprosthesis: predictions based on meta-analysis and microsimulation. *Circulation* 2001;**103**:1535–1541.
26. Gaur P, Kaneko T, McGurk S, Rawn JD, Maloney A, Cohn LH. Mitral valve repair versus replacement in the elderly: short-term and long-term outcomes. *J Thorac Cardiovasc Surg* 2014;**148**:1400–1406.
27. Vassileva CM, Ghazanfari N, Markwell S, Boley T, Hazelrigg S. Preoperative heart failure in the Medicare population undergoing mitral valve repair and replacement: an opportunity for improvement. *J Thorac Cardiovasc Surg* 2014.
28. Gillinov AM, Wierup PN, Blackstone EH, Bishay ES, Cosgrove DM, White J, Lytle BW, McCarthy PM. Is repair preferable to replacement for ischemic mitral regurgitation? *J Thorac Cardiovasc Surg* 2001;**122**:1125–1141.
29. Smith PK, Puskas JD, Ascheim DD, Voisine P, Gelijns AC, Moskowitz AJ, Hung JW, Parides MK, Ailawadi G, Perrault LP, Acker MA, Argenziano M, Thourani V, Gammie JS, Miller MA, Page P, Overbey JR, Bagiella E, Dagenais F, Blackstone EH, Kron IL, Goldstein DJ, Rose EA, Moquette EG, Jeffries N, Gardner TJ, O’Gara PT, Alexander JH, Michler RE. Surgical treatment of moderate ischemic mitral regurgitation. *N Engl J Med* 2014;**371**:2178–2188.
30. De Bonis M, Ferrara D, Taramasso M, Calabrese MC, Verzini A, Buzzatti N, Alfieri O. Mitral replacement or repair for functional mitral regurgitation in dilated and ischemic cardiomyopathy: is it really the same? *Ann Thorac Surg* 2012;**94**:44–51.
31. Lorusso R, Gelsomino S, Vizzardi E, D’Aloia A, De Cicco G, Luca F, Parise O, Gensini GF, Stefano P, Livi U, Vendramin I, Pacini D, Di Bartolomeo R, Miceli A, Varone E, Glauber M, Parolari A, Giuseppe Arlati F, Alamanni F, Serraino F, Renzulli A, Messina A, Troise G, Mariscalco G, Cottini M, Beghi C, Nicolini F, Gherli T, Borghetti V, Pardini A, Caimmi PP, Micalizzi E, Fino C, Ferrazzi P, Di Mauro M, Calafiore AM. Mitral valve repair or replacement for ischemic mitral regurgitation? The Italian Study on the Treatment of Ischemic Mitral Regurgitation (ISTIMIR). *J Thorac Cardiovasc Surg* 2013;**145**:128–139; discussion 137–138.
32. Taramasso M, Buzzatti N, La Canna G, Colombo A, Alfieri O, Maisano F. Interventional vs. surgical mitral valve therapy. Which technique for which patient? *Herz* 2013;**38**:460–466.
33. Magne J, Senechal M, Dumesnil JG, Pibarot P. Ischemic mitral regurgitation: a complex multifaceted disease. *Cardiology* 2009;**112**:244–259.
34. Dayan V, Soca G, Cura L, Mestres CA. Similar survival after mitral valve replacement or repair for ischemic mitral regurgitation: a meta-analysis. *Ann Thorac Surg* 2014;**97**:758–765.
35. Kempfert J, Blumenstein J, Chu MW, Pritzwald-Stegmann P, Kobilke T, Falk V, Mohr FW, Walther T. Minimally invasive off-pump valve-in-a-ring implantation: the atrial transcatheter approach for re-operative mitral valve replacement after failed repair. *Eur J Cardiothorac Surg* 2009;**35**:965–969; discussion 969.
36. Maisano F, Vanermen H, Seeburger J, Mack M, Falk V, Denti P, Taramasso M, Alfieri O. Direct access transcatheter mitral annuloplasty with a sutureless and adjustable device: preclinical experience. *Eur J Cardiothorac Surg* 2012;**42**:524–529.
37. Siminiak T, Dankowski R, Baszko A, Lee C, Firek L, Kalmucki P, Szyszka A, Groothuis A. Percutaneous direct mitral annuloplasty using the MitraClip Bident system: description of the method and a case report. *Kardiol Pol* 2013;**71**:1287–1292.
38. Antunes MJ, Colsen PR, Kinsley RH. Mitral valvuloplasty: a learning curve. *Circulation* 1983;**68**(3 Pt 2):1170–1175.
39. Schillinger W, Athanasiou T, Weicken N, Berg L, Tichelbacker T, Puls M, Hunlich M, Wachter R, Helms HJ, Seipelt R, Schondube FA, Hasenfuss G. Impact of the learning curve on outcomes after percutaneous mitral valve repair with MitraClip and lessons learned after the first 75 consecutive patients. *Eur J Heart Fail* 2011;**13**:1331–1339.
40. Hammermeister K, Sethi GK, Henderson WG, Grover FL, Oprian C, Rahimtoola SH. Outcomes 15 years after valve replacement with a mechanical versus a bioprosthetic valve: final report of the Veterans Affairs randomized trial. *J Am Coll Cardiol* 2000;**36**:1152–1158.
41. Kaneko T, Aranki S, Javed Q, McGurk S, Shekar P, Davidson M, Cohn L. Mechanical versus bioprosthetic mitral valve replacement in patients <math>\geq 65</math> years old. *J Thorac Cardiovasc Surg* 2014;**147**:117–126.
42. Glower DD, Kar S, Trento A, Lim DS, Bajwa T, Quesada R, Whitlow PL, Rinaldi MJ, Grayburn P, Mack MJ, Mauri L, McCarthy PM, Feldman T. Percutaneous mitral valve repair for mitral regurgitation in high-risk patients: results of the EVEREST II study. *J Am Coll Cardiol* 2014;**64**:172–181.
43. De Bonis M, Lapenna E, Verzini A, La Canna G, Grimaldi A, Torracca L, Maisano F, Alfieri O. Recurrence of mitral regurgitation parallels the absence of left ventricular reverse remodeling after mitral repair in advanced dilated cardiomyopathy. *Ann Thorac Surg* 2008;**85**:932–939.
44. Crabtree TD, Bailey MS, Moon MR, Munfakh N, Pasque MK, Lawton JS, Moazami N, Aubuchon KA, Al-Dadah AS, Damiano RJ Jr. Recurrent mitral regurgitation and risk factors for early and late mortality after mitral valve repair for functional ischemic mitral regurgitation. *Ann Thorac Surg* 2008;**85**:1537–1542; discussion 1542–3.
45. Grayburn PA, Foster E, Sangli C, Weissman NJ, Massaro J, Glower DG, Feldman T, Mauri L. Relationship between the magnitude of reduction in mitral regurgitation severity and left ventricular and left atrial reverse remodeling after MitraClip therapy. *Circulation* 2013;**128**:1667–1674.
46. Paranskaya L, D’Ancona G, Bozdogan-Turan I, Akin I, Kische S, Turan GR, Rehders T, Ortak J, Nienaber CA, Ince H. Residual mitral valve regurgitation after percutaneous mitral valve repair with the MitraClip(R) system is a risk factor for adverse one-year outcome. *Catheter Cardiovasc Interv* 2013;**81**:609–617.
47. Mauri L, Foster E, Glower DD, Apruzzese P, Massaro JM, Herrmann HC, Hermiller J, Gray W, Wang A, Pedersen WR, Bajwa T, Lasala J, Low R, Grayburn P, Feldman T, Investigators E. 4-year results of a randomized controlled trial of percutaneous repair versus surgery for mitral regurgitation. *J Am Coll Cardiol* 2013;**62**:317–328.
48. Gammie JS, O’Brien SM, Griffith BP, Ferguson TB, Peterson ED. Influence of hospital procedural volume on care process and mortality for patients undergoing elective surgery for mitral regurgitation. *Circulation* 2007;**115**:881–887.
49. Pibarot P, Dumesnil JG. Prosthetic heart valves: selection of the optimal prosthesis and long-term management. *Circulation* 2009;**119**:1034–1048.
50. Vesey JM, Otto CM. Complications of prosthetic heart valves. *Curr Cardiol Rep* 2004;**6**:106–111.
51. Suri RM, Vanoverschelde JL, Grigioni F, Schaff HV, Tribouilloy C, Avierinos JF, Barbieri A, Pasquet A, Huebner M, Rusinaru D, Russo A, Michelena HI, Enriquez-Sarano M. Association between early surgical intervention vs watchful waiting and outcomes for mitral regurgitation due to flail mitral valve leaflets. *JAMA* 2013;**310**:609–616.
52. Neuss M, Schau T, Schoepp M, Seifert M, Holschermann F, Meyhofer J, Butter C. Patient selection criteria and midterm clinical outcome for MitraClip therapy in patients with severe mitral regurgitation and severe congestive heart failure. *Eur J Heart Fail* 2013;**15**:786–795.
53. Taramasso M, Maisano F, Latib A, Denti P, Buzzatti N, Cioni M, La Canna G, Colombo A, Alfieri O. Clinical outcomes of MitraClip for the treatment of functional mitral regurgitation. *EuroIntervention* 2014;**10**:746–752.
54. Auricchio A, Prinzen FW. Non-responders to cardiac resynchronization therapy: the magnitude of the problem and the issues. *Circ J* 2011;**75**:521–527.