

Canakinumab in adults with steroid-refractory pyoderma gangrenosum

A.G.A. Kolios,^{1,2} J.-T. Maul,¹ B. Meier,¹ K. Kerl,¹ C. Traidl-Hoffmann,³ M. Hertl,⁴ D. Zillikens,⁵ M. Röcken,⁶ J. Ring,³ A. Facchiano,⁷ C. Mondino,⁸ N. Yawalkar,⁹ E. Contassot,¹ A.A. Navarini¹ and L.E. French¹

¹Department of Dermatology and ²Department of Immunology, Zürich University Hospital, Gloriastraße 31, 8091 Zürich, Switzerland

³Department of Dermatology and Allergy Biederstein, Technische Universität München, Munich, Germany

⁴Departments of Dermatology and Allergology, Philipps University Marburg, Marburg, Germany

⁵Department of Dermatology, University of Lübeck, Lübeck, Germany

⁶Department of Dermatology, Eberhard Karls University of Tübingen, Tübingen, Germany

⁷Istituto Dermatologico dell'Immacolata, IDI-IRCCS, Rome, Italy

⁸Ospedale Regionale di Bellinzona e Valli, Bellinzona, Switzerland

⁹Department of Dermatology, Bern University Hospital, Bern, Switzerland

Linked Comment: Costanzo, *Br J Dermatol* 2015; **173**: 1124

Summary

Correspondence

Lars E. French.

E-mail: lars.french@usz.ch

Accepted for publication

8 July 2015

Funding sources

This study was supported by the Swiss National Science Foundation 31003A-135465 to L.E.F. and the University of Zurich Matching Funds (to A.A.N.). This study was supported by Novartis Pharma Schweiz AG.

Conflicts of interest

None declared.

A.G.A.K., J.T.M. and B.M. contributed equally to this article and should be considered joint first authors.

DOI 10.1111/bjd.14037

Background Pyoderma gangrenosum (PG) is a rare, neutrophilic, ulcerative skin disease that is difficult to treat, especially when unresponsive to steroids.

Objectives To determine whether canakinumab is an effective and safe treatment in PG.

Methods Five adult patients with clinically and histologically confirmed steroid-refractory PG were enrolled in this prospective open-label study. They received canakinumab 150 mg subcutaneously at week 0 with an optional 150 mg at week 2 in case of an inadequate response [Physician's Global Assessment (PGA) ≥ 2], and an optional 150–300 mg at week 8 depending on PGA. The primary clinical end point was clinical improvement (PGA at least -1 from baseline) and/or complete remission (PGA 0 or 1) at week 16. Real-time quantitative polymerase chain reaction was performed on skin samples to quantify cytokine mRNA levels.

Results Interleukin (IL)-1 β and its known target genes IL6, CXCL8 and IL36A were significantly increased in lesional skin of PG. Under canakinumab therapy, four of five patients showed a decrease in target-lesion size, PGA and Dermatology Life Quality Index (DLQI), and three of five achieved complete remission. The mean diameter of target lesions decreased from 4.32 ± 2.6 cm at visit 1 to 0.78 ± 1.3 cm at visit 7 ($P = 0.03$). Mean DLQI decreased from 15 ± 5 at visit 1 to 8 ± 4 by visit 7 ($P = 0.01$). Adverse effects were reported in two patients: fatigue in one and worsening of disease at a nontarget lesion in the other.

Conclusions Our data indicate that IL-1 β plays a key pathogenic role in PG and canakinumab may represent a therapeutic option for steroid-refractory PG.

What's already known about this topic?

- Pyoderma gangrenosum is a rare, difficult-to-treat neutrophilic ulcerative skin disease frequently associated with systemic disease, and treatment can be challenging.
- The successful use of canakinumab in pyoderma gangrenosum has been reported in the context of PAPA syndrome (pyogenic arthritis, pyoderma gangrenosum and acne), a recently characterized rare autosomal dominant autoinflammatory disease of early onset.

What does this study add?

- The proinflammatory cytokine interleukin (IL)-1 β is abundant in its active form in human pyoderma gangrenosum skin lesions.
- Blockade of IL-1 β with the monoclonal antibody canakinumab can improve steroid-resistant pyoderma gangrenosum.
- This provides novel evidence that IL-1 β plays a role in the pathogenesis of pyoderma gangrenosum.

Pyoderma gangrenosum (PG) is a rare noninfectious neutrophilic dermatosis. It is characterized by sterile pustular skin lesions that rapidly evolve into tender skin ulcers with undermined borders of varying size and depth, sometimes exposing underlying tendons or muscles.^{1,2} PG is frequently associated with systemic disease, most commonly inflammatory bowel disease (65–93%), arthritis (16%) and lymphoproliferative disorders (12%).^{3–6} The clinical course of PG can be mild, aggressive, chronic or relapsing. Severe courses have been reported, with multiple skin lesions, genital involvement and extracutaneous manifestations including pulmonary involvement.^{7–10}

Only one prospective randomized controlled trial and a few large case studies on PG have been reported to date.^{1,11–14} Treatment is usually directed towards inhibiting inflammation, disease progression and pain. Systemic steroids are considered the first-line therapy, although not all cases of PG are responsive.¹⁵ Cyclosporin and tumour necrosis factor (TNF)- α inhibitors have proved useful as second- and third-line therapies, but resistance and worsening of disease have been reported.^{15–17} Immunosuppressive mono- or polytherapy is required in up to 71% of cases and has been associated with persisting disease (mean 8 years) and a mortality of up to 23%.^{6,18–20} In responders to conventional therapy, on average 16 months were required to achieve remission.²¹

Overactivation of the innate immune system is assumed to elicit PG, and high levels of interleukin (IL)-8 and TNF- α are associated with the typical overwhelming neutrophilic infiltration found in PG.²² Interestingly, in PAPA syndrome (pyogenic arthritis, pyoderma gangrenosum and acne)^{23,24} – a recently characterized rare autosomal dominant autoinflammatory disease of early onset – and another PG-associated syndrome,²⁵ mutations in proline–serine–threonine phosphatase-interacting protein 1 (PSTPIP1/CD2BP1) were identified. These lead to activation of the cytosolic multimeric inflammasome protein complex that promotes the maturation of the inflammatory cytokines IL-1 β and IL-18.

Transgenic mice carrying a mutation in the inflammasome gene *Nlrp3* (NLR family, pyrin domain containing 3) spontaneously develop neutrophil-rich skin lesions. This is equivalent to the human mutation associated with the cryopyrin-associated periodic syndrome Muckle–Wells syndrome,²⁶ which involves increased IL-1 β production. Intriguingly, an imbalance in the adaptive immune system was recently shown with

polarization in favour of T helper (Th)1/Th17 cells and downregulation of Th2 cells or a reduced regulatory T cell/Th17 ratio.^{27,28} Overexpression of IL-1 β and IL-8 in PG has been reported previously,²⁹ and the successful use of canakinumab in PG in the context of PAPA syndrome has been reported.^{30–32} Therefore we considered that IL-1 β may be directly driving the development of PG and may be an attractive therapeutic target.

In this work we show that the proinflammatory cytokine IL-1 β is abundant in its active form in human PG skin lesions, and that blockade of IL-1 β with the monoclonal antibody canakinumab can improve steroid-resistant PG, providing novel evidence that IL-1 β plays a role in the pathogenesis of PG.

Materials and methods

Patients

Five adult patients (age > 18 years) with clinically and histologically investigator-initiated confirmed PG were enrolled in this prospective open-label study, having fulfilled the inclusion criteria (Appendix S1; see Supporting Information) and provided their written informed consent. All five patients had idiopathic PG without associated systemic disease, and had failed one or more systemic therapy including systemic steroids. The characteristics of these patients are shown in Table 1.

Their mean age was 52.3 ± 19.5 years, and all patients were white. The mean body weight was 87.3 kg and the mean body mass index was 27.4 ± 3.4 kg m⁻². The number of PG lesions ranged from one to six with a mean of 2.8 ± 1.8 . The mean time between first symptoms and the study start was 4.7 ± 4.1 years.

Treatment

Canakinumab 150 mg was administered subcutaneously to all patients at week 0, and a further 150 mg was administered subcutaneously at week 2 in case of Physician's Global Assessment (PGA) > 2. At week 8 in case of PGA 0, canakinumab 150 mg was administered subcutaneously; in case of PGA 1–3 the cumulative dose of canakinumab administered so far (150 or 300 mg) was administered subcutaneously; in case of PGA

Table 1 Characteristics of the patients with pyoderma gangrenosum (PG)

Patient number	1	2	3	4	5
Sex	Male	Male	Male	Male	Female
Age at study inclusion (years)	66	42	73	19	61
Duration of PG prior to study inclusion (years)	4.1	4.0	12.4	0.2	2.7
Age at time of primary manifestation of PG (years)	62	38	60	19	58
Body mass index (kg m ⁻²)	29.5	28.4	32.1	24.5	22.6
Target lesion	Abdominal right	Mammary left	Abdominal right	Right leg	Inguinal left
Total lesion count	3	6	3	1	1
Prior treatments	Systemic steroids, dapsone	Systemic steroids, ciclosporin A, etanercept, infliximab, cyclophosphamide, intravenous immunoglobulin	Systemic steroids, ciclosporin A, azathioprine, mycophenolate mofetil, etanercept, cyclophosphamide, dapsone	Systemic steroids, doxycycline	Systemic steroids, ciclosporin A, dapsone

4 no further study drug was administered (Fig. S1; see Supporting Information). The detailed study protocol is available in Appendix S1.

At each visit during the treatment (weeks 0–8) and during the follow-up period (weeks 9–16) physical examinations were performed, including vital signs, examination of the target lesion, PGA, Dermatology Life Quality Index (DLQI) and digital photographic documentation. At weeks –1, 8 and 16 a complete blood count and measurements of C-reactive protein and renal and liver function were performed. The surface area and diameter of target lesions were calculated from digital photographs – taken at the above study visits with a ruler next to the lesion to enable a reference of scale – using digital calculation software (Universal Desktop Ruler; AVPSoft, Voronezh, Russia).

The primary clinical end point was induction of clinical improvement by canakinumab (PGA score at least –1 from baseline) and/or complete clinical remission (PGA 0 or 1) as measured by PGA at week 16. Secondary end points were the percentage of patients with complete clinical remission and the percentage of patients with partial clinical improvement at weeks 2, 4, 8 and 12; the change in target-lesion diameter

and area compared with baseline; and the quality of life measured by DLQI.

The study protocol (NCT01302795) was approved by the clinical research ethics committee of Kanton Zurich (KEK-ZH-Nr. 2010-0212/5) and Swissmedic.

Cytokine expression analysis

Real-time quantitative polymerase chain reaction

Formalin-fixed paraffin-embedded skin samples were deparaffinized, RNA was extracted, cDNA synthesized by reverse transcription, and real-time quantitative polymerase chain reaction (qPCR) performed with primers for IL-1 α , IL-1 β , IL-6, CXCL8 (IL-8), IL-12 β , IL-36 α , IL36 γ , IFN γ and TNF- α to quantify tissue mRNA levels in patients with PG.

Interleukin-1 β detection in skin-biopsy specimens

Formalin-fixed paraffin-embedded skin samples were sectioned (5 μ m), deparaffinized and immunostained with the use of rabbit antihuman mature IL-1 β (ab53175; Abcam, Cambridge,

Fig 1. Enhanced levels of interleukin (IL)-1 β in lesional skin of patients with pyoderma gangrenosum (PG). (a) mRNA levels for the proinflammatory cytokines IL-1 α , IL-1 β , IL-6, IL-8, IL-12, IL-36 α , IL-36 γ , tumour necrosis factor (TNF)- α and interferon (IFN)- γ in historical lesional skin-biopsy samples from patients with PG ($n = 7$) and healthy human skin ($n = 6$) as assessed by quantitative polymerase chain reaction (qPCR). (b) mRNA levels for IL-1 β in historical lesional skin-biopsy samples of patients with PG ($n = 7$) compared with lesional skin-biopsy samples of patients with eczema ($n = 5$) as assessed by qPCR. (c) Levels of IL-1 β mRNA detected by qPCR in lesional skin samples of biopsied patients with PG at the time of inclusion in the clinical trial (visit 1). Study patient 5 declined to have a skin biopsy at study inclusion (N.A.). (d) IL-1 β protein levels as detected by immunohistochemistry (anti-IL-1 β , red staining) in a lesional skin biopsy taken from patient number 4 at the time of study inclusion. For comparison, IL-1 β immunostaining in a biopsy of severe eczema is shown. The haematoxylin and eosin stain (H&E) of the lesional skin biopsy from patient 4 shows an abundant neutrophilic inflammatory infiltrate in the dermis. Sections incubated with an unspecific antibody of the same isotype as the primary anti-IL-1 β antibody (isotype) were included as a control for antibody specificity. (e) Quantification of the intensity of IL-1 β immunostaining within the epidermis and dermal inflammatory infiltrate (dermis) of healthy skin ($n = 4$), eczema ($n = 6$) and PG ($n = 7$). Differences between groups were assessed using an unpaired Student's *t*-test with subsequent Bonferroni correction. n.s. (not significant) indicates a *P*-value > 0.05 . **P* ≤ 0.05 , ***P* ≤ 0.01 .

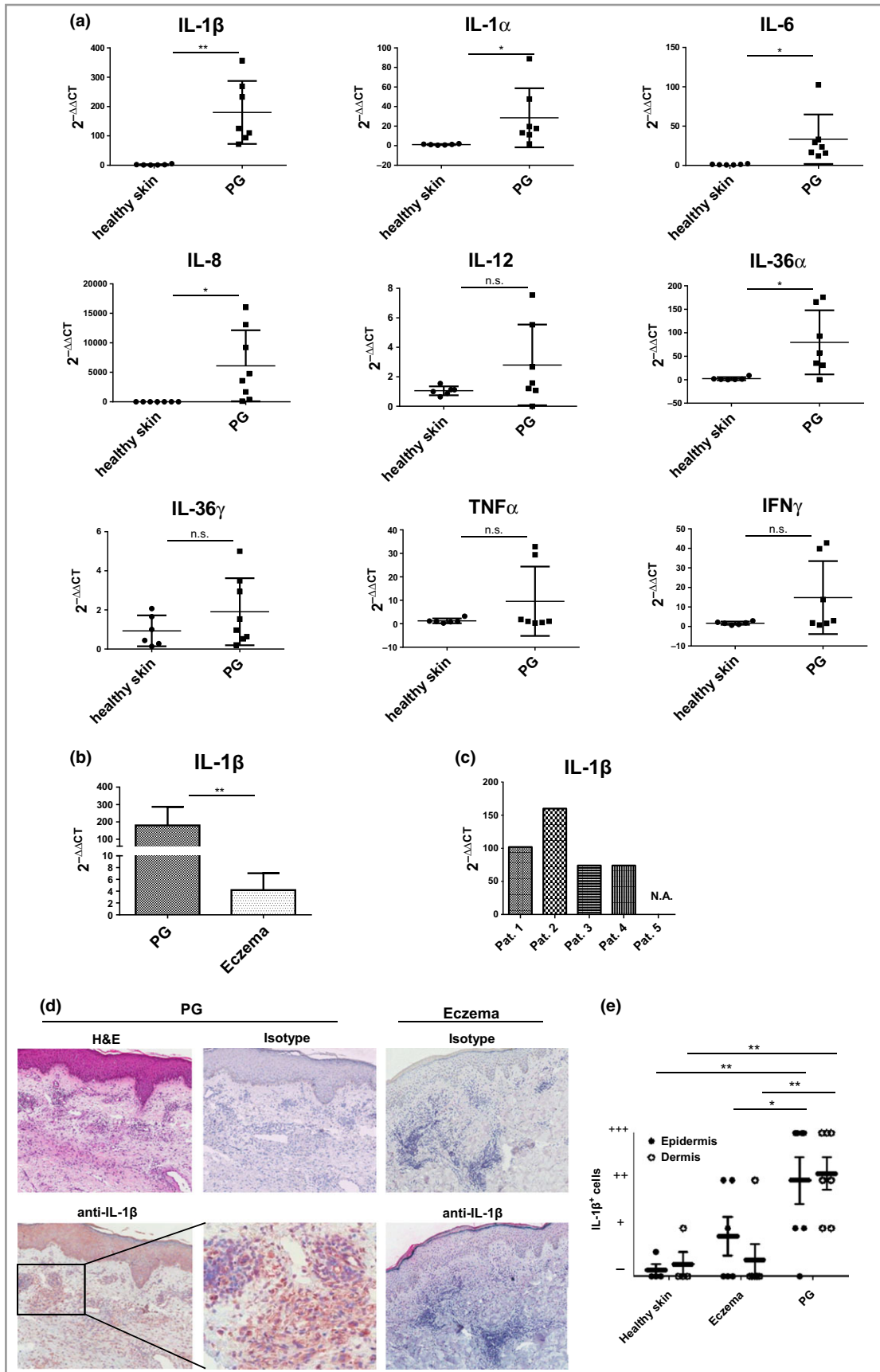


Fig 2. Clinical response of pyoderma gangrenosum (PG) to canakinumab therapy. (a) Target-lesion diameter (PG diameter), target-lesion area (PG area), Physician's Global Assessment (PGA) score and Dermatology Life Quality Index (DLQI) as recorded in study patients 1–5 at study visits 1 (week –1), 2 (week 0), 3 (week 2), 4 (week 4), 5 (week 8), 6 (week 12) and 7 (week 16) are depicted graphically for each study patient separately. (b) The evolution of the mean target-lesion diameter (PG diameter), target-lesion area (PG area), PGA score and DLQI for study patients 1–5 between study visits 1 and 7. Mean values are shown with SEM. (c) Photographic illustration of the target lesion of study patient 4 at visits 1, 3 and 7.

U.K.) antibody or isotype control antibody (ab27478; Abcam) in patients with PG.

To increase our sample numbers for real-time qPCR and IL-1 β detection, biopsies from historical cases of PG were analysed, in addition to biopsies from patients with the inflammatory disease eczema and control biopsies from healthy individuals. Further details are provided in Appendix S2 (see Supporting Information).

For statistical analysis a t-test with subsequent Bonferroni correction was performed.

Results

Inflammatory cytokine expression

Gene expression analysis of selected proinflammatory cytokines, assessed in historical lesional skin biopsies of patients with PG, showed significantly increased expression of the genes encoding IL-1 α , IL-1 β , IL-6, IL-8 and IL-36 α when compared with skin of healthy controls (Fig. 1a). Expression levels of TNF- α , interferon- γ , IL-36 γ and IL-12 were not significantly increased. Levels of IL-1 β mRNA in PG lesions from historical cases were also significantly increased when compared with levels observed in patients with eczema (Fig. 1b). In all steroid-resistant patients with PG selected for this clinical trial who consented to a skin biopsy, analysis of IL-1 β mRNA levels in lesional skin performed upon screening also revealed high levels of IL-1 β (Fig. 1c). In these five patients, as well as in a retrospective series of seven lesional skin biopsies from patients with PG, semiquantitative evaluation by immunohistochemistry indicated that IL-1 β was significantly more abundant at the protein level in the epidermal and dermal compartments of skin lesions from patients with PG than in patients with eczema and healthy controls (Fig. 1d, e).

Response to canakinumab

All patients received canakinumab 150 mg subcutaneously at week 0 and at week 2, and patients 3–5 also received 300 mg subcutaneously at week 8, as their PGA was between 1 and 3. Patient 1 did not get another injection of canakinumab according to protocol as the PGA was 4, and patient 2 dropped out at week 8. The response of each of the five patients to treatment with canakinumab is shown in Figure 2.

The primary clinical end point was induction of clinical improvement with canakinumab (PGA score at least –1 from baseline) and/or complete clinical remission (PGA 0 or 1) as measured by PGA at week 16. Three of the five patients

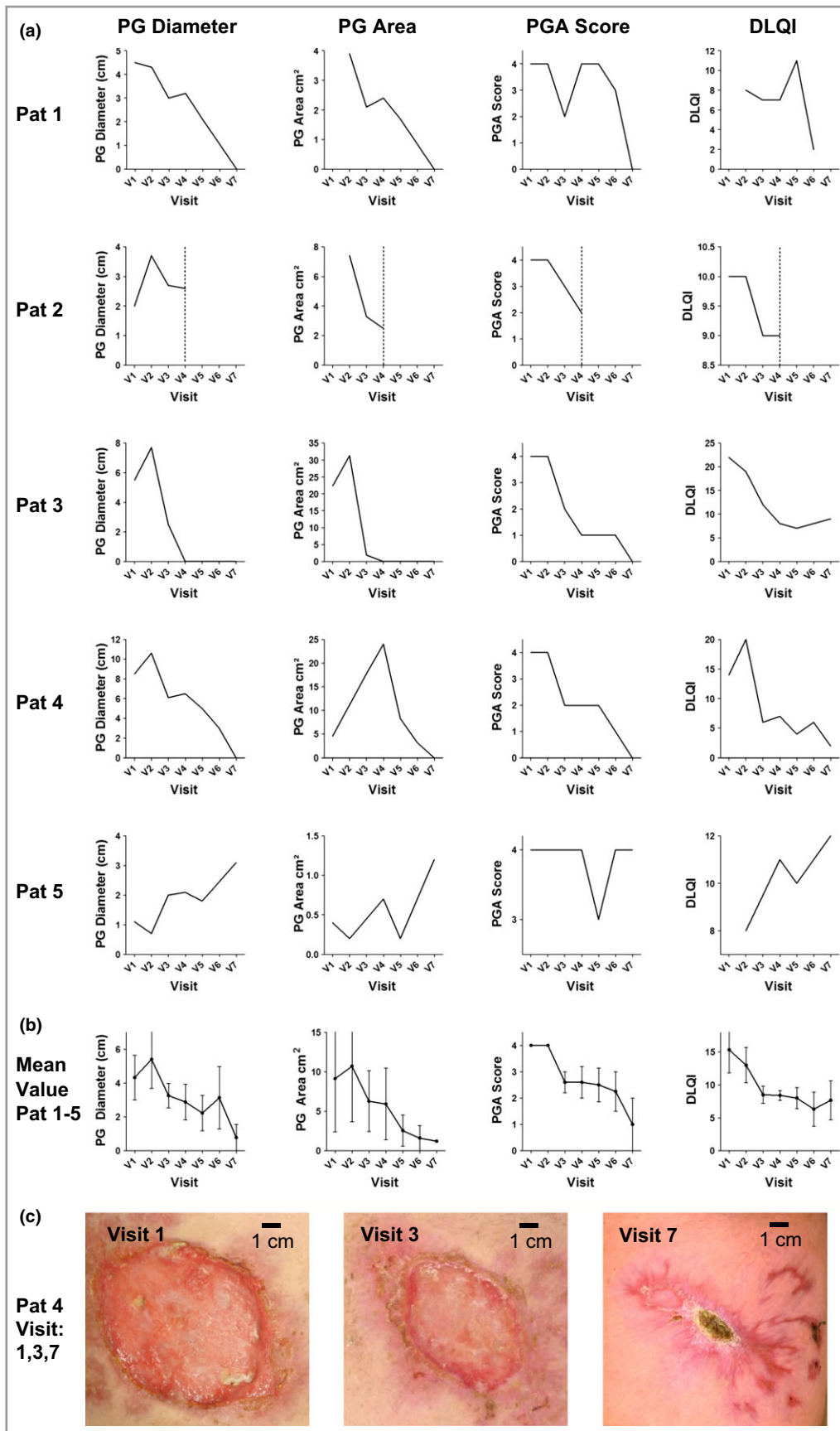
(60%, patients 1, 3 and 4) showed complete resolution of clinical signs of inflammation and complete healing of the target lesion at week 16, and one patient (20%, patient 2 at visit 4 before dropout) had a PGA score improvement of 2 (Fig. 2a).

Secondary end points were the percentage of patients with complete clinical remission and the percentage of patients with partial clinical improvement at weeks 2, 4, 8 and 12; the change in target-lesion diameter and area compared with baseline; and the quality of life measured by DLQI. Three of five patients (60%) showed complete healing with a decrease of PG target-lesion diameter and area to zero, whereas one of the five patients (20%) showed a reduction in PG target-lesion area but not diameter (patient 2). Four of five patients showed a reduction in DLQI between study visits 1 and 7 (Fig. 2a).

The mean diameter of all five patients' target lesions significantly decreased, from 4.32 ± 2.6 cm at visit 1 to 0.78 ± 1.3 cm at visit 7 ($P = 0.03$, Fig. 2b). The mean area of all five patients' target lesions also decreased – but without reaching significance – from 9.1 ± 9.5 cm² at visit 1 to 0.3 ± 0.5 cm² at visit 7 ($P = 0.09$, Fig. 2b). Assessment of the DLQI showed a significant mean decrease from 15 ± 5 at visit 1 to 8 ± 4 at visit 7 ($P = 0.01$, Fig. 2b).

Taken together, at 16 weeks after canakinumab initiation, four of five patients (80%) had reached the primary clinical end point of clinical improvement (PGA score at least –1 from baseline), and complete clinical remission (PGA 0 or 1) was achieved in three patients (60%). The clinical course of patient 4 is shown in Figure 2c and that of the other patients in Figure S2 (see Supporting Information).

Adverse effects were reported in two of the five patients (40%). One patient reported fatigue after receiving canakinumab, without any other objective clinical or laboratory anomalies. The second patient (patient number 2), a 42-year-old man with a 6-year history of chronic relapsing PG previously treated with numerous immunosuppressive regimens (Table 1), suddenly developed three new small scrotal ulcers after study visit 4. He was hospitalized abroad on suspicion of rapidly progressive infectious genital ulcers during immunosuppression, leading to registration of a serious adverse event (SAE) and dropout from the study. However, the target lesion of this patient that had improved already by the time of the SAE had healed completely by week 16 and did not relapse. Clinical work-up after hospital admission eventually ruled out infectious skin disease, thus suggesting a relapse of PG at a distant location under canakinumab treatment in this patient. No patient was on concomitant systemic therapy during the study.



Discussion

The management of PG unresponsive to conventional immunosuppressive therapy is challenging.³³ Although systemic steroids with or without associated ciclosporin are widely considered to be the first-line therapy, cases unresponsive to this regimen are common. Little evidence exists from clinical studies concerning the frequency of severe steroid-resistant PG, the mortality associated with PG or the optimal therapeutic regimen for steroid-resistant PG. The most comprehensive analysis published to date is a retrospective chart review performed between 2000 and 2007 on patient data from the Research Patient Data Repository of the Brigham and Women's Hospital and Massachusetts General Hospital.³ In that study 103 patients with PG were analysed by the most frequently reported multimodal therapy regimen, and the mortality during the 8-year study period was 16%.

Saracino *et al.*³⁴ reported the therapy and outcome of 26 cases of PG requiring inpatient management. In their case series, prednisolone then ciclosporin were the most commonly prescribed systemic therapies, with 50% of patients showing complete ulcer healing at the 6-month follow-up, and a reported mortality of 27%.³⁴ The only randomized controlled study published to date compared infliximab with placebo, showing significant clinical improvement in 46% of patients (six of 13) at week 2 in the infliximab group compared with 6% (one of 17) in the placebo group.¹³ Overall 69% of patients (20 of 29) demonstrated a beneficial clinical response to infliximab after 6 weeks, and 31% of patients failed to respond. These studies highlight the severity of PG, the need for aggressive therapy and the high overall morbidity and mortality of the disease.

Canakinumab is a human monoclonal antibody that selectively blocks IL-1 β and has no known cross-reactivity with other IL-1 family members.³⁵ Canakinumab is approved for the treatment of cryopyrin-associated periodic syndromes, a group of monogenic autoinflammatory syndromes including familial cold autoinflammatory syndrome, Muckle-Wells syndrome and neonatal-onset multisystem inflammatory disease, which are characterized by mutations in the NLRP3 gene leading to overproduction of IL-1 β and systemic inflammation.³⁶ Recently, clinical reports have suggested a therapeutic effect of drugs targeting IL-1 signalling in patients with complex autoinflammatory syndromes involving PG as a clinical element, namely in PAPA and PASH syndrome (pyoderma, acne and suppurative hidradenitis).^{30,37,38}

Our data show that idiopathic PG is characterized by overproduction of IL-1 β , as demonstrated by increased IL-1 β mRNA and protein within skin lesions of PG when compared with eczematous skin and healthy controls. Using canakinumab, we successfully induced complete (60% of patients) or partial (20% of patients) remission in patients with steroid-refractory PG within the 16-week study period. This study was not limited to patients in the inflammatory phase, as patient 5 had a chronic crusted lesion with a plasma-cell-rich

inflammatory border. In sharp contrast to the other patients, no response was observed in this patient.

Although PG impairs the quality of life of patients, this parameter has rarely been specifically analysed.³⁹ In our patients, who had a mean DLQI of 15 indicative of a severe impairment in their quality of life at study initiation, the DLQI decreased significantly to a mean of 8 upon treatment with canakinumab.

Limitations of this study are the small sample size and the open-label study design. Also, clinical scores used for the evaluation of efficacy are known to be susceptible to inter- and intrarater variations. However, in an effort to minimize this limitation we applied a software-based analysis of the ulcer size (surface area and diameter) using standardized digital photographs of the target lesion taken at each study visit.⁴⁰ Another limitation is that the planned analysis of histological parameters – such as neutrophil and lymphocyte numbers in the responder, partial responder and nonresponder patients at week 16 compared with baseline – could not be performed, as most patients refused a biopsy at week 16 in fear of a possible pathergy phenomenon and relapse/flare of their PG (patient 5 declined a biopsy at study inclusion but had a histologically proven PG).

Taken together, our investigator-initiated study suggests that despite the above limitations, canakinumab may be an effective and well-tolerated treatment for idiopathic, steroid-refractory PG. Our clinical and biological data indicate that the proinflammatory cytokine IL-1 β very likely plays a key pathogenic role in PG and offers a rationale for further clinical trials evaluating canakinumab or IL-1 β -blocking agents for the treatment of PG.

Acknowledgments

We thank Tatiana Proust and Ines Kleiber-Schaaf for technical assistance.

References

- Wollina U, Haroske G. Pyoderma gangraenosum. *Curr Opin Rheumatol* 2011; **23**:50–6.
- Ruocco E, Sangiuliano S, Gravina AG *et al.* Pyoderma gangrenosum: an updated review. *J Eur Acad Dermatol Venereol* 2009; **23**:1008–17.
- Binus AM, Qureshi AA, Li VW, Winterfield LS. Pyoderma gangrenosum: a retrospective review of patient characteristics, comorbidities and therapy in 103 patients. *Br J Dermatol* 2011; **165**:1244–50.
- Shahi V, Wetter DA. Pyoderma gangrenosum associated with solid organ malignancies. *Int J Dermatol* 2015; **54**:e351–7.
- DeFilippis EM, Feldman SR, Huang WW. The genetics of pyoderma gangrenosum and implications for treatment: a systematic review. *Br J Dermatol* 2015; **172**:1487–97.
- Weizman AV, Huang B, Targan S *et al.* Pyoderma gangrenosum among patients with inflammatory bowel disease: a descriptive cohort study. *J Cutan Med Surg* 2014; **18**:361.
- Gade M, Studstrup F, Andersen AK *et al.* Pulmonary manifestations of pyoderma gangrenosum: 2 cases and a review of the literature. *Respir Med* 2015; **109**:443–50.

- 8 Sakata KK, Penupolu S, Colby TV *et al.* Pulmonary pyoderma gangrenosum without cutaneous manifestations. *Clin Respir J* 2014; DOI: 10.1111/crj.12240.
- 9 Mercer JM, Kuzel P, Mahmood MN, Brassard A. Fatal case of vulvar pyoderma gangrenosum with pulmonary involvement: case presentation and literature review. *J Cutan Med Surg* 2014; **18**:424–9.
- 10 Satoh M, Yamamoto T. Genital pyoderma gangrenosum: report of two cases and published work review of Japanese cases. *J Dermatol* 2013; **40**:840–3.
- 11 Bouchaud G, Gehrke S, Krieg C *et al.* Epidermal IL-15R α acts as an endogenous antagonist of psoriasiform inflammation in mouse and man. *J Exp Med* 2013; **210**:2105–17.
- 12 Craig FF, Thomas KS, Mitchell EJ *et al.* UK Dermatology Clinical Trials Network's STOP GAP trial (a multicentre trial of prednisolone vs. ciclosporin for pyoderma gangrenosum): protocol for a randomised controlled trial. *Trials* 2012; **13**:51.
- 13 Brooklyn TN, Dunnill MG, Shetty A *et al.* Infliximab for the treatment of pyoderma gangrenosum: a randomised, double blind, placebo controlled trial. *Gut* 2006; **55**:505–9.
- 14 Miller J, Yentzer BA, Clark A *et al.* Pyoderma gangrenosum: a review and update on new therapies. *J Am Acad Dermatol* 2010; **62**:646–54.
- 15 Wollina U. Pyoderma gangrenosum – a review. *Orphanet J Rare Dis* 2007; **2**:19.
- 16 D'Inca R, Fagioli S, Sturmiolo GC. Tacrolimus to treat pyoderma gangrenosum resistant to cyclosporine. *Ann Intern Med* 1998; **128**:783–4.
- 17 Sinagra E, Orlando A, Renna S *et al.* Multifocal pyoderma gangrenosum resistant to infliximab in active ulcerative colitis: don't forget the role of cyclosporin. *Inflamm Bowel Dis* 2012; **18**:E1594–5.
- 18 Langan SM, Groves RW, Card TR, Gulliford MC. Incidence, mortality, and disease associations of pyoderma gangrenosum in the United Kingdom: a retrospective cohort study. *J Invest Dermatol* 2012; **132**:2166–70.
- 19 Al Ghazal P, Dissemmond J. Therapy of pyoderma gangrenosum in Germany: results of a survey among wound experts. *J Dtsch Dermatol Ges* 2015; **13**:317–24.
- 20 Ye MJ, Ye JM. Pyoderma gangrenosum: a review of clinical features and outcomes of 23 cases requiring inpatient management. *Dermatol Res Pract* 2014; **2014**:461467.
- 21 Hasselmann DO, Bens G, Tilgen W, Reichrath J. Pyoderma gangrenosum: clinical presentation and outcome in 18 cases and review of the literature. *J Dtsch Dermatol Ges* 2007; **5**:560–4.
- 22 Wolff K, Goldsmith LA, Katz SI. *Fitzpatrick's Dermatology in General Medicine*. New York: McGraw-Hill, 2010.
- 23 Yu JW, Fernandes-Alnemri T, Datta P *et al.* Pypyrin activates the ASC pyroptosome in response to engagement by autoinflammatory PSTPIP1 mutants. *Mol Cell* 2007; **28**:214–27.
- 24 Yu JW, Farias A, Hwang I *et al.* Ribotoxic stress through p38 mitogen-activated protein kinase activates *in vitro* the human pypyrin inflammasome. *J Biol Chem* 2013; **288**:11378–83.
- 25 Zeeli T, Padalon-Brauch G, Ellenbogen E *et al.* Pyoderma gangrenosum, acne and ulcerative colitis in a patient with a novel mutation in the PSTPIP1 gene. *Clin Exp Dermatol* 2015; **40**:367–72.
- 26 Meng G, Zhang F, Fuss I *et al.* A mutation in the Nlrp3 gene causing inflammasome hyperactivation potentiates Th17 cell-dominant immune responses. *Immunity* 2009; **30**:860–74.
- 27 Quaglino P, Fava P, Caproni M *et al.* Phenotypical characterization of circulating cell subsets in pyoderma gangrenosum patients: the experience of the Italian immuno-pathology group. *J Eur Acad Dermatol Venereol* 2015; DOI: 10.1111/jdv.13100.
- 28 Caproni M, Antiga E, Volpi W *et al.* The Treg/Th17 cell ratio is reduced in the skin lesions of patients with pyoderma gangrenosum. *Br J Dermatol* 2015; **173**:275–8.
- 29 Marzano AV, Fanoni D, Antiga E *et al.* Expression of cytokines, chemokines and other effector molecules in two prototypic autoinflammatory skin diseases, pyoderma gangrenosum and Sweet's syndrome. *Clin Exp Immunol* 2014; **178**:48–56.
- 30 Jaeger T, Andres C, Grosber M *et al.* Pyoderma gangrenosum and concomitant hidradenitis suppurativa – rapid response to canakinumab (anti-IL-1 β). *Eur J Dermatol* 2013; **23**:408–10.
- 31 Geusau A, Mothes-Luksch N, Nahavandi H *et al.* Identification of a homozygous PSTPIP1 mutation in a patient with a PAPA-like syndrome responding to canakinumab treatment. *JAMA Dermatol* 2013; **149**:209–15.
- 32 Ter Haar N, Lachmann H, Ozen S *et al.* Treatment of autoinflammatory diseases: results from the Eurofever Registry and a literature review. *Ann Rheum Dis* 2013; **72**:678–85.
- 33 Ahronowitz I, Harp J, Shinkai K. Etiology and management of pyoderma gangrenosum: a comprehensive review. *Am J Clin Dermatol* 2012; **13**:191–211.
- 34 Saracino A, Kelly R, Liew D, Chong A. Pyoderma gangrenosum requiring inpatient management: a report of 26 cases with follow up. *Australas J Dermatol* 2011; **52**:218–21.
- 35 Dinarello CA, Simon A, van der Meer JW. Treating inflammation by blocking interleukin-1 in a broad spectrum of diseases. *Nat Rev Drug Discov* 2012; **11**:633–52.
- 36 Lachmann HJ, Kone-Paut I, Kuemmerle-Deschner JB *et al.* Use of canakinumab in the cryopyrin-associated periodic syndrome. *N Engl J Med* 2009; **360**:2416–25.
- 37 Brenner M, Ruzicka T, Plewig G *et al.* Targeted treatment of pyoderma gangrenosum in PAPA (pyogenic arthritis, pyoderma gangrenosum and acne) syndrome with the recombinant human interleukin-1 receptor antagonist anakinra. *Br J Dermatol* 2009; **161**:1199–201.
- 38 Braun-Falco M, Kovnerystyy O, Lohse P, Ruzicka T. Pyoderma gangrenosum, acne, and suppurative hidradenitis (PASH) – a new autoinflammatory syndrome distinct from PAPA syndrome. *J Am Acad Dermatol* 2012; **66**:409–15.
- 39 Gerard AJ, Feldman SR, Strowd L. Quality of life of patients with pyoderma gangrenosum and hidradenitis suppurativa. *J Cutan Med Surg* 2015; **19**:391–6.
- 40 Puzenat E, Bronsard V, Prey S *et al.* What are the best outcome measures for assessing plaque psoriasis severity? A systematic review of the literature. *J Eur Acad Dermatol Venereol* 2010; **24**(Suppl. 2):10–16.

Supporting Information

Additional Supporting Information may be found in the online version of this article at the publisher's website:

Fig S1. Overview of the study regimen.

Fig S2. Clinical response of patients 1, 2, 3 and 5.

Appendix S1. Clinical study protocol.

Appendix S2. Supplementary methods.