Original Paper

Ophthalmologica

Ophthalmologica 2012;228:53–58
DOI: 10.1159/000336908

Received: August 5, 2011
Accepted after revision: January 17, 2012
Published online: April 4, 2012

Prospective Study of Foveal Thickness Alterations after Cataract Surgery Assessed by Optical Coherence Tomography

Miltiadis Tsilimbaris[a] Vasilios F. Diakonis[a, b] George D. Kymionis[a, b]
Maria I. Eleftheriadou[a] Sofia Fragkiskou[a] Joanna Moschandreas[b]
Beatrice E. Frueh[c] Daniel Epstein[d] Aristophanis I. Pallikaris[b]

[a]Department of Ophthalmology, University Hospital of Crete, and [b]Department of Medicine, Institute of Vision and Optics, University of Crete, Heraklion, Greece; [c]Department of Ophthalmology, University Hospital, Bern, and [d]Department of Ophthalmology, University Hospital, Zurich, Switzerland

Downloaded from http://karger.com/oph/article-pdf/228/1/53/3354175/000336908.pdf by Universitätsbibliothek Bern user on 21 September 2023

source: https://doi.org/10.48350/8128 | downloaded: 12.10.2024

Key Words
Cataract surgery · Foveal thickness · Optical coherence tomography · Diabetes mellitus · Glaucoma · Epiretinal membrane

Abstract
Background/Aims: To evaluate the alterations of mean foveal thickness (MFT) and visual acuity (VA) outcomes after uncomplicated cataract surgery in different groups of patients. ***Methods:*** This study included eyes of consecutive patients who underwent cataract surgery between November 2007 and June 2009. The patients included in the study were divided into 4 groups, as follows: history-free patients, patients with diabetes mellitus without macular involvement at baseline, patients with glaucoma, and patients with epiretinal membrane (ERM). Preoperatively and at 1, 3 and 6 months postoperatively, patients were evaluated for MFT by optical coherence tomography at the central 1-mm macular zone and for logarithm of the minimum angle of resolution best spectacle-corrected VA (BSCVA). ***Results:*** A total of 202 eyes were included in the study. MFT values demonstrated a statistically significant increase ($p < 0.01$) after cataract surgery in all groups at the first and third postoperative month. The history-free ($p = 0.09$) and glaucoma ($p = 0.19$) groups did not demonstrate a statistically significant difference in MFT values between the preoperative and 6-month measurements. MFT values 6 months after cataract surgery in the diabetes and ERM groups remained significantly higher ($p < 0.01$). Despite these findings, VA increased significantly ($p < 0.01$) in all groups at all postoperative follow-ups. ***Conclusions:*** MFT values increased significantly in all groups at the first and third months after cataract surgery. At 6 months, MFT values returned to preoperative levels in the history-free and glaucoma patients, while they remained significantly higher in the diabetic and ERM patients. Despite these macular alterations, BSCVA improved significantly after cataract surgery in all groups at all postoperative follow-ups.

Copyright © 2012 S. Karger AG, Basel

Introduction

Postoperative macular structural alterations mainly consist of macular thickening, which is a result of postsurgical inflammatory cascades [1, 2]. The final common

KARGER
Fax +41 61 306 12 34
E-Mail karger@karger.ch
www.karger.com

© 2012 S. Karger AG, Basel
0030–3755/12/2281–0053$38.00/0

Accessible online at:
www.karger.com/oph

Vasilios F. Diakonis, MD
Department of Medicine
Institute of Vision and Optics, University of Crete
GR–71305 Heraklion (Greece)
E-Mail diakonis@gmail.com

pathway of inflammation after ocular procedures appears to be the increased perifoveal capillary permeability and breakdown of the blood-retina barrier, resulting in accumulation of fluid in the outer plexiform and inner nuclear layers of the retina [3]. This condition is referred to as cystoid macular edema (CME) or Irvine-Gass syndrome [4–6].

Postoperative CME can occur as a complication of a variety of surgical procedures. The incidence of CME with subsequent visual loss following uncomplicated phacoemulsification with an intact posterior capsule has been reported to be 0–2% [7, 8]. The condition may be identified and described using different diagnostic techniques such as ophthalmoscopy, fluorescein angiography and optical coherence tomography (OCT).

Time domain OCT delivers a series of indices that can be used for the assessment of macular thickness, with the most important being mean foveal thickness (MFT). MFT as a means of evaluating macular thickness offers an objective and reliable value and demonstrates satisfactory repeatability [9–11]. The MFT measurement is based on 512 data points, rather than the 6 data points from 6 scan lines from which the mean minimal foveal thickness is calculated. Accordingly, it is less sensitive to decentration [10].

The risk of CME after cataract surgery may increase in the presence of ocular or systemic diseases such as epiretinal membrane (ERM) or diabetes mellitus [12, 13]. The aim of the present study was to assess OCT changes (MFT) and visual acuity (VA) over a 6-month period in different groups of patients (history-free patients and patients with glaucoma, diabetes mellitus or ERM) undergoing cataract surgery. To the best of our knowledge, this is the first prospective study comparing postcataract macular thickness alterations and visual outcomes in different groups of patients.

Patients and Methods

Patient Population

This prospective study included consecutive patients scheduled to undergo cataract surgery at the University Hospital of Heraklion, Greece, between November 2007 and June 2009. All eyes were analyzed by OCT for changes in MFT and by logarithm of the minimum angle of resolution (logMAR) best spectacle-corrected VA (BSCVA) measurements at 4 time points: preoperatively and 1, 3 and 6 months after surgery.

Patients were divided into 4 groups, as follows: history-free patients (patients free of any ocular and systemic disease with ophthalmic involvement); patients with diabetes; patients with glaucoma, and patients with an ERM. All patients were informed of the risks and benefits prior to cataract surgery, and they gave their written informed consent in accordance with institutional guidelines and the Declaration of Helsinki for human research. Study approval was obtained from the postgraduate committee of the University of Crete, Faculty of Medicine.

Of the 214 patients enrolled in the study, a total of 202 eyes of 202 patients were finally included; 101 patients (50%) were male and 101 (50%) were female, and the mean patient age was 65.95 ± 11.68 years (range 30–86). As can be seen in table 1, 127 patients (62.87%) did not have any known preexisting ocular condition, 27 patients (13.36%) had diabetes mellitus, 24 (11.88%) had glaucoma and 24 (11.88%) had ERM.

Cataract Surgery Technique

After topical anesthesia, a clear corneal incision, capsulorhexis and phacoemulsification were performed in all eyes. The intraocular lens was placed in the capsular bag. Postoperatively, all patients received the same treatment, namely a combination of steroid-antibiotic eye drops (TobraDex, Alcon Laboratories, Hellas AEBE, Greece) starting at 4 times daily and tapering by 1 drop every week for the next 4 weeks. In patients with glaucoma, preoperative topical glaucoma medications were maintained after cataract surgery.

Patient Assessment

BSCVA, complete slit-lamp examination and OCT were performed in all patients before surgery and 1, 3 and 6 months after surgery. Preoperative OCT was performed no more than 1 week before surgery. Ophthalmological and systemic history, preoperative OCT findings and perioperative data were recorded in order to identify possible risk factors.

Inclusion and Exclusion Criteria

The patients included in the study either had an unremarkable ocular and systemic history (history-free patients were considered those without any ocular and systemic disease with ophthalmic involvement) or presented with glaucoma, diabetes or ERM. The patients with glaucoma, diabetes or ERM demonstrated only one of these conditions; i.e., no patient with two or more pathologies was included. For patients with diabetes mellitus, proliferative diabetic retinopathy as well as background retinopathy with macular involvement were exclusion criteria. Patients with ERM and glaucoma had no other ocular pathology. Patients with inadequate quality of preoperative OCT images and patients unable to attend more than one postoperative examination were also excluded. Patients who were initially included in the study but who experienced complications such as posterior capsule rupture were excluded. Patients with glaucoma receiving prostaglandin analogs as topical treatment and who had had previous antiglaucoma surgery were also excluded from the study.

OCT Imaging

OCT images were obtained with an OCT3 (Stratus OCT, Carl Zeiss Ophthalmic Systems, Dublin, Calif., USA). For the OCT examination, the pupils were dilated with tropicamide 0.5% and phenylephrine 5%. The macular thickness scan protocol was selected to obtain 6 consecutive 6-mm radial scans centered on the macula. OCT images were analyzed using retinal thickness analysis software. The analysis of each radial scan showed the macular anatomy and possible macular abnormalities. The retinal thickness

Downloaded from http://karger.com/oph/article-pdf/228/1/53/3354175/000336908.pdf by Universitätsbibliothek Bern user on 21 September 2023

analyzer protocol also provided a 6-mm-diameter topographic retinal map with a central zone of 1 mm, an eccentric zone of 3 mm and another eccentric zone of 6 mm, based on the 6 consecutive scans. To evaluate macular thickness, the MFT in the central 1-mm zone was used. MFT was defined as the average thickness of the central sector with a 1,000-μm diameter (512 data points).

Statistical Analysis

Repeated-measurements ANOVA was performed for the 4 time points documented as well as for the 4 patient groups. The same statistical analysis was used to assess VA. The statistical package JMP (software version 5, SAS Institute Inc., Cary, N.C., USA) was used. A p value lower than 0.05 was considered statically significant. Power calculation was carried out using the approach described by D'Amico et al. [14]. Based on this approach, all tests provided a power of greater than 80% at the 0.05 level.

Results

Means, standard deviations and ranges of MFT and logMAR VA for all groups at all time points are shown in table 1.

OCT Outcomes

Preoperatively, MFT values in the history-free, diabetes and glaucoma groups were on average 203, 207 and 205 μm, respectively. Preoperative MFT for the ERM group was 225 μm, which was significantly higher than all other groups ($p < 0.01$).

All groups demonstrated a statistically significant increase in MFT at the first and third postoperative months ($p < 0.05$ for all 4 groups). MFT reached maximum values 1 month after cataract surgery in all groups. A gradual regression 3 and 6 months after surgery was seen in all groups. The evolution of average MFT values followed the same pattern in all groups. However, at the last postoperative examination, the ERM group (MFT increased from 225.1 to 231.5 μm; $p < 0.05$) and the diabetes patients (MFT increased from 206.6 to 223.2 μm; $p < 0.05$) showed a statistically significantly higher MFT when compared with preoperative values. In contrast, the history-free patients (MFT increased from 202.8 to 206.9 μm; $p = 0.09$) and the glaucoma group (MFT increased from 205.4 to 206.7 μm; $p = 0.19$) did not display significantly different changes in MFT (table 1; fig. 1). The difference between the last postoperative and preoperative mean MFT values was 4.09, 16.59, 1.34 and 6.44 μm for history-free, diabetic, glaucoma and ERM patients, respectively. The group of diabetic patients presented the greatest difference in MFT value when compared with all other groups.

Table 1. Patient demographics, MFT and logMAR VA for each group at each examination point

Group	Number of eyes	MFT, μm				VA, logMAR			
		preoperative	1 month	3 months	6 months	preoperative	1 month	3 months	6 months
History free	127	202.8 ± 25.79 (144–293)	213.5 ± 41.55 (144–293)	207.28 ± 30.52 (144–417)	206.89 ± 37.97 (142–530)	0.55 ± 0.18 (1–0.1)	0.08 ± 0.12 (0.52 to –0.2)	0.05 ± 0.10 (0.49 to –0.18)	0.03 ± 0.10 (0.52 to –0.18)
Diabetes mellitus	27	206.6 ± 21.47 (162–249)	241.89 ± 76.2 (164–525)	226.69 ± 39.08 (159–338)	223.19 ± 27.86 (170–294)	0.66 ± 0.25 (1.22–0.25)	0.14 ± 0.18 (0.82 to –0.08)	0.12 ± 0.14 (0.7 to –0.04)	0.07 ± 0.10 (0.32 to –0.08)
Glaucoma	24	205.36 ± 19.0 (170–235)	214.41 ± 28.2 (172–276)	212.50 ± 25.1 (173–264)	206.70 ± 29.43 (159–264)	0.53 ± 0.2 (1–0.15)	0.14 ± 0.13 (0.4–0.0)	0.09 ± 0.11 (0.47 to –0.01)	0.09 ± 0.11 (0.52 to –0.02)
ERM	24	225.08 ± 53.7 (170–432)	250.04 ± 76.2 (182–487)	234.82 ± 53.12 (187–436)	231.52 ± 51.59 (176–428)	0.57 ± 0.15 (1–0.27)	0.14 ± 0.10 (0.4 to –0.02)	0.12 ± 0.11 (0.32 to –0.12)	0.09 ± 0.09 (0.3 to –0.11)

Values are presented as means ± standard deviation and range in parentheses.

Downloaded from http://karger.com/oph/article-pdf/228/1/53/3354175/000336908.pdf by Universitätsbibliothek Bern user on 21 September 2023

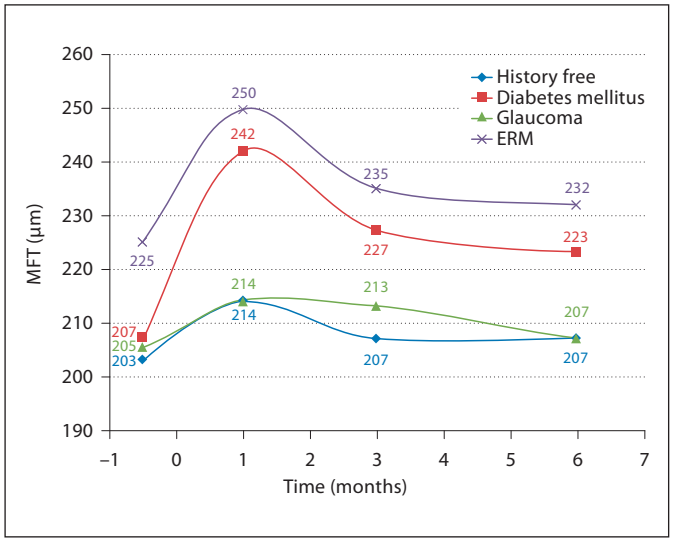

Fig. 1. MFT of each group at all examination time points.

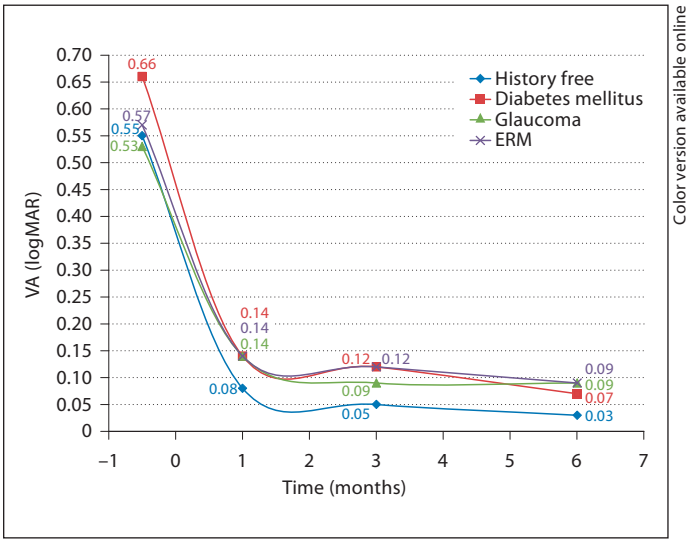

Fig. 2. logMAR VA of each group at all examination time points.

VA Outcomes

VA improved significantly in all groups after cataract surgery. Mean logMAR VA improved from a preoperative value of 0.55 to 0.03 at 6 months postoperatively ($p < 0.05$) in the history-free group, from 0.66 to 0.07 ($p < 0.05$) in the diabetes group, from 0.53 to 0.09 ($p < 0.05$) in the glaucoma group and from 0.57 to 0.09 ($p < 0.05$) in the ERM group. Postoperative BSCVA was not correlated with preoperative VA measurements in any of the eyes ($p = 0.88$). VA improvement was independent of preexisting ocular and/or systemic diseases ($p = 0.11$). Furthermore, VA at each postoperative examination was not statistically significantly different when comparing the history-free group with the other 3 groups ($p = 0.08$). A trend for better VA outcomes was seen for the history-free group when compared with the other groups, with VA better on average at all postoperative examinations. The VA values for all groups are shown in table 1 and figure 2.

Discussion

Structural alterations of the macula occur after intraocular surgery or may develop in the presence of ocular or systemic diseases [1, 2, 6]. The pathophysiology is attributed to the induced inflammation, which destabilizes the blood-retina barrier [3]. This causes increased vascular permeability and thus accumulation of fluid within the retinal tissue, resulting in macular thickening (i.e. edema). Macular thickness changes may be quantified by OCT but are not always linked to a decrease in VA (subclinical or clinically insignificant macular alterations).

In the present study, we prospectively examined macular thickness alterations using MFT and BSCVA outcomes after uneventful cataract surgery in four distinct groups of patients. All groups demonstrated a statistically significant increase in MFT (increase in macular pachymetry) at the first and third postoperative month. A regression of MFT was demonstrated in all groups at 3 and 6 months postoperatively. An identical pattern of macular thickness change was noted in all groups, which may indicate that surgically induced inflammation causes early (1 month after surgery) macular changes, which then regress 3–6 months postoperatively as the inflammation subsides (triggering factor). Several other studies have concluded that macular thickening after uneventful cataract surgery does occur, demonstrating statistically significant changes during the first 6 postoperative months [2, 15].

All groups demonstrated their lowest values of postoperative MFT at the 6-month examination. Although the history-free and glaucoma groups did not show a statistically significant MFT change when comparing the preoperative values and the last follow-up, MFT in the diabetes and ERM groups remained statistically significantly different 6 months after surgery. In the diabetic

Downloaded from http://karger.com/oph/article-pdf/228/1/53/3354175/000336908.pdf by Universitätsbibliothek Bern user on 21 September 2023

group, this may be attributable to the systemic disease, which influences vascular permeability (the pathophysiologic basis of macular thickness alteration) [16]. Furthermore, diabetic patients showed the greatest difference between postoperative and preoperative macular thickness (16.59 μm) at 6 months. This may indicate that cataract extraction influences the underlying pathophysiology, leading to delay in postoperative macular fluid absorption or prolonged vascular exudation. However, postoperative VA recovery was not compromised in our diabetic patients, indicating that the changes at the macular level remained subclinical in this group, which did not have macular involvement related to diabetic retinopathy preoperatively.

Eriksson et al. [17] studied a similar group of diabetic patients and compared them with a group of normal patients. They also found increased macular thickness values postoperatively in diabetics, which, however, did not reach a statistically significant level; VA of both diabetics and normals was equally improved in their study [17]. Kim et al. [18] reported a significantly greater difference between preoperative and 3-month postoperative macular thickness in diabetic patients with moderate and severe diabetic retinopathy, which was accompanied by an inverse correlation between visual improvement and macular thickness. In the same study, the OCT-documented macular thickness changes in diabetic patients without retinopathy were significantly smaller, in the range of 14–18 μm. This correlates well with the findings of our study, in which diabetic patients were enrolled only if there was no macular involvement.

Macular ERM causes tractional stress on the retinal tissue, resulting in macular deformational thickening and cystoid space formation with or without traction-induced leakage of macular capillaries. This likely explains the significant preoperative difference in MFT between the ERM patients and the other 3 groups. In the ERM group, the surgically induced blood-retina barrier breakdown (which increases vascular permeability) combined with the ERM-induced tractional stress seem to significantly influence macular alterations even 6 months after cataract surgery [13].

VA improved significantly after cataract surgery in all eyes. Moreover, there was no evidence that the rate of VA improvement differed according to the risk factor status (i.e. VA did not depend on patient group; $p = 0.11$) or that postoperative VA was correlated with preoperative VA measurements ($p = 0.885$).

VA outcomes were not influenced in any eyes that demonstrated significant macular pachymetry increases. Thus, direct correlation between OCT-documented retinal structural changes and VA could not be confirmed. This lack of correlation has been reported by other authors [17].

Kim et al. [18] showed decreased visual improvement in diabetic patients who developed postcataract macular thickening that exceeded the 130-μm value, in comparison with patients who developed thickening of around 15 μm. In our study, the maximum preoperative to postoperative difference in macular thickness at 6 months was found in diabetic patients and reached 16 μm, which may explain the good visual recovery in this group; in this context, we must note again that in this study we enrolled diabetic patients without proliferative diabetic retinopathy or macular involvement at baseline. These findings may suggest that the severity and stage of diabetic retinopathy play a significant role in postcataract visual outcomes.

This study is limited by the relatively small numbers of patients with ocular and systemic diseases. Furthermore, we did not include glaucoma patients who were treated with prostaglandin analogs. An additional group with patients receiving such topical medication would offer further information about prostaglandin-related CME development. Our study followed patients for 6 months after cataract surgery; however, longer follow-up, especially in patients with diabetes, is necessary in order to assess macular thickness changes. Finally, quality of vision (such as measured by contrast sensitivity, for example) was not assessed in this study. Even though VA did not appear to be influenced by macular alterations in this study, the same may not apply for visual quality. Finally, in this work we used time domain OCT for the assessment of the thickness; utilization of spectral domain OCT might have revealed additional information (such us inner/outer segment defects) permitting more accurate correlation of macular morphology with visual function.

We conclude that after uneventful cataract surgery, MFT values demonstrated a statistically significant increase in all groups at the first and third postoperative month. By the sixth postoperative month, MFT values had regressed to preoperative levels in the history-free and glaucoma patients, while they remained significantly higher in ERM and diabetic patients (without macular involvement at baseline). Even though MFT values remained statistically higher at 6 months in these two groups, macular thickness did not reach clinically significant levels. Independent of these subclinical macular alterations, BSCVA demonstrated significant improve-

Downloaded from http://karger.com/opt/article-pdf/228/1/53/3354175/000336908.pdf by Universitätsbibliothek Bern user on 21 September 2023

ment after cataract surgery in all groups. Although patients with ERM and diabetes mellitus warrant closer follow-up after cataract operation, the expected visual outcomes do not seem to be influenced by macular edema development.

Acknowledgement

This research project was supported by a grant from the European Society of Cataract and Refractive Surgeons.

References

1 Biró Z, Balla Z: OCT measurements on the foveal and perifoveal retinal thickness on diabetic patients after phacoemulsification and IOL implantation. Eye (Lond) 2010;24:639–647.
2 Perente I, Utine CA, Ozturker C, Cakir M, Kaya V, Eren H, Kapran Z, Yilmaz OF: Evaluation of macular changes after uncomplicated phacoemulsification surgery by optical coherence tomography. Curr Eye Res 2007;32:241–247.
3 Ursell PG, Spalton DJ, Whitcup SM, Nussenblatt RB: Cystoid macular edema after phacoemulsification: relationship to blood-aqueous barrier damage and visual acuity. J Cataract Refract Surg 1999;25:1492–1497.
4 Irvine AR: Cystoid maculopathy. Surv Ophthalmol 1976;21:1–17.
5 Gass JD, Norton EW: Cystoid macular edema and papilledema following cataract extraction: a flouorescein fundoscopic and angiographic study. Arch Ophthalmol 1996;76:646–661.
6 Tranos PG, Wickremasinghe SS, Stangos NT, Topouzis F, Tsinopoulos I, Pavesio CE: Macular edema. Surv Ophthalmol 2004;49:470–490.
7 Mentes J, Erakgun T, Afrashi F, Kerci G: Incidence of cystoid macular edema after uncomplicated phacoemulsification. Ophthalmologica 2003;217:408–412.
8 Flach AJ: The incidence, pathogenesis and treatment of cystoid macular edema following cataract surgery. Trans Am Ophthalmol Soc 1998;96:557–634.
9 Jagow B, Ohrloff C, Kohnen T: Macular thickness after uneventful cataract surgery determined by optical coherence tomography. Graefes Arch Clin Exp Ophthalmol 2007;245:1765–1771.
10 Chan A, Duker JS, Ko TH, Fujimoto JG, Schuman JS: Normal macular thickness measurements in healthy eyes using Stratus optical coherence tomography. Arch Ophthalmol 2006;124:193–198.
11 Paunescu LA, Schuman JS, Price LL, Stark PC, Beaton S, Ishikawa H, Wollstein G, Fujimoto JG: Reproducibility of nerve fiber thickness, macular thickness, and optic nerve head measurements using Stratus-OCT. Invest Ophthalmol Vis Sci 2004;45:1716–1724.
12 Krepler K, Biowski R, Schrey S, Jandrasits K, Wedrich A: Cataract surgery in patients with diabetic retinopathy: visual outcome, progression of diabetic retinopathy, and incidence of diabetic macular oedema. Graefes Arch Clin Exp Ophthalmol 2002;240:735–738.
13 Henderson BA, Kim JY, Ament CS, Ferrufino-Ponce ZK, Grabowska A, Cremers SL: Clinical pseudophakic cystoid macular edema. Risk factors for development and duration after treatment. J Cataract Refract Surg 2007;33:1550–1558.
14 D'Amico EJ, Neilands TB, Zambarano R: Power analysis for multivariate and repeated measures designs: a flexible approach using the SPSS MANOVA procedure. Behav Res Methods Instrum Comput 2001;33:479–484.
15 Biro Z, Balla Z, Kovacs B: Change of foveal and perifoveal thickness measured by OCT after phacoemulsification and IOL implantation. Eye 2008;22:8–12.
16 Sanchez-Tocino H, Alvarez-Vidal A, Maldonado MJ, Moreno-Montanes J, Garcia-Layana A: Retinal thickness study with optical coherence tomography in patients with diabetes. Invest Ophthalmol Vis Sci 2002;43:1588–1594.
17 Eriksson U, Alm A, Bjärnhall G, Granstam E, Matsson AW: Macular edema and visual outcome following cataract surgery in patients with diabetic retinopathy and controls. Graefes Arch Clin Exp Ophthalmol 2011;249:349–359.
18 Kim SJ, Equi R, Bressler NM: Analysis of macular edema after cataract surgery in patients with diabetes using optical coherence tomography. Ophthalmology 2007;114:881–889.

Downloaded from http://karger.com/oph/article-pdf/228/1/53/3354175/000336908.pdf by Universitätsbibliothek Bern user on 21 September 2023