

RANDOMIZED TRIAL

Is the Sedimentation Sign Associated With Spinal Stenosis Surgical Treatment Effect in SPORT?

Rachel A. Moses, MD,* Wenyan Zhao, PhD,*† Lukas P. Staub, PhD,‡
Markus Melloh, MD, DMedSc, MPH, PhD, MBA,§ Thomas Barz, MD,¶ and Jon D. Lurie, MD, MS*+||

Study Design. Subgroup analysis of the lumbar spinal stenosis (LSS) without degenerative spondylolisthesis diagnostic cohort of the Spine Patient Outcomes Research Trial multicenter randomized clinical trial with a concurrent observational cohort.

Objective. To determine if sedimentation sign on magnetic resonance image can help with LSS treatment decisions.

Summary of Background Data. LSS is one of the most common reasons for surgery in the US elderly, but there is a dearth of reliable diagnostic tools that give a clear indication for surgery. Recent studies have suggested that positive sedimentation sign on magnetic resonance image may be a possible prognostic indicator.

Methods. All patients with LSS in both the randomized and observational cohorts had imaging-confirmed stenosis, were surgical candidates, and had neurogenic claudication for at least 12 weeks prior to enrollment. Patients were categorized as “mild,” “moderate,” or “severe” according to stenosis severity. Of the 654 patients with LSS enrolled in Spine Patient Outcomes Research Trial, complete T2-weighted axial and sagittal digitized images of 115 patients were available for retrospective review. An independent orthopedic spine surgeon evaluated these deidentified Digital Imaging and Communications in Medicine files for the sedimentation sign.

Results. Sixty-six percent (76/115) of patients were found to have a positive sedimentation sign. Those with a positive sedimentation sign were more likely to have stenosis at L2–L3 (33% vs. 10% $P = 0.016$) or L3–L4 (76% vs. 51%, $P = 0.012$), and to have severe (72% vs. 33%, $P < 0.0001$) central stenosis (93% vs. 67% $P < 0.001$) at 2 or more concurrent levels (57% vs. 18%, $P = 0.01$). In multivariate models, the surgical treatment effect was significantly larger in the positive sedimentation sign group for Oswestry Disability Index (-16 vs. -7 ; $P = 0.02$).

Conclusion. A positive sedimentation sign was associated with a small but significantly greater surgical treatment effect for Oswestry Disability Index in patients with symptomatic LSS, after adjusting for other demographic and imaging features. These findings suggest that positive sedimentation sign may potentially be a useful adjunct to help guide an informed treatment choice regarding surgery for LSS.

Key words: lumbar spinal stenosis, sedimentation sign, MRI, shared decision making, surgical treatment.

Level of Evidence: 2

Spine 2015;40:129–136

From the *Department of Orthopaedics, Dartmouth-Hitchcock Medical Center, Lebanon, NH; †The Dartmouth Institute for Health Policy and Clinical Practice, Geisel School of Medicine, Lebanon, NH; ‡Institute for Evaluative Research in Orthopaedic Surgery, University of Bern, Bern, Switzerland; §Centre for Health Sciences, Zurich University of Applied Sciences, Winterthur, Switzerland; ¶Department of Orthopaedic Surgery, Asklepios Klinikum Uckermark, Schwedt, Germany; and ||Department of Medicine, Geisel School of Medicine, Lebanon, NH.

Acknowledgment date: November 13, 2013. First revision date: April 23, 2014. Second revision date: June 27, 2014. Acceptance date: June 29, 2014.

The manuscript submitted does not contain information about medical device(s)/drug(s).

The National Institute of Arthritis and Musculoskeletal and Skin Diseases (U01-AR45444) and the Office of Research on Women's Health, the National Institutes of Health, and the National Institute of Occupational Safety and Health, the Centers for Disease Control and Prevention funds were received in support of this work. Dr Moses is partially funded by NIAMS ARRA supplement to the Ruth L. Kirschstein NRSA (3T32AR049710-07S1). The Multidisciplinary Clinical Research Center in Musculoskeletal Diseases is funded by NIAMS (P60-AR048094 and P60-AR062799).

Relevant financial activities outside the submitted work: consultancy, stocks.

Address correspondence and reprint requests to Jon D. Lurie, MD, MS, Departments of Medicine, Orthopaedics and the Dartmouth Institute, Dartmouth-Hitchcock Medical Center, Lebanon, NH 03756; E-mail: jonathan.d.lurie@hitchcock.org or tamara.s.morgan@dartmouth.edu

DOI: 10.1097/BRS.0000000000000672

Spine

First described by Verbiest in 1947,¹ lumbar spinal stenosis (LSS) has become one of the most common surgically treated ailments affecting our aging population.^{2,3} Despite this fact, there have yet to be clear treatment indications for this disease, partly due to a lack of reliable diagnostic tools.^{4–10} In addition to clinical diagnostic tests,^{11–15} cross-sectional spinal canal narrowing has become a commonly accepted imaging criteria of LSS,^{16,17} yet, several studies have shown that there can be little correlation between anatomical narrowing, clinical symptoms, and treatment outcomes.^{5,11,7,8,15,17–22}

Recently, Barz *et al*²³ introduced the sedimentation sign on magnetic resonance image (MRI) as a possible aid in decision making for LSS. Normally, in the supine position the lumbar nerve roots should settle to the posterior spinal canal due to gravity and the absence of constrictive force. A positive sedimentation sign, however, is evident when a patient lying supine has the absence of posterior nerve root settling.^{1,14,23,24} A previous study by Barz *et al*²³ demonstrated the ability of the sedimentation sign to discriminate between known cases of symptomatic central LSS and controls with nonspecific low back pain. An observational follow-up study by the same

www.spinejournal.com 129

Copyright © 2015 Wolters Kluwer Health, Inc. Unauthorized reproduction of this article is prohibited.

group showed that, in patients treated with decompression surgery, the sign does not seem to predict surgical outcome, whereas in nonoperatively treated patients, a positive sign is associated with more limited improvement.²⁵ This evidence indicates that the sedimentation sign may provide information about prognosis in patients who do not proceed to surgery and/or help to identify patients more likely to benefit from surgery. However, to date no studies have provided unbiased estimates of the relationship between a positive sedimentation sign and treatment outcomes in patients with LSS.

The Spine Patient Outcomes Research Trial (SPORT), a multicenter randomized clinical trial with a concurrent observational cohort, demonstrated better outcomes for patients with LSS treated surgically than those treated nonoperatively; however, 2 years after surgery only 63% report major symptomatic improvement, whereas almost 30% of patients treated nonoperatively report a similar level of improvement.²⁶ Improved ability to identify patients more or less likely to benefit from surgical intervention would be an important aid to clinical decision making. To this end, we performed a subgroup analysis on the SPORT LSS cohort; we used baseline MR images from patients with LSS enrolled in SPORT to evaluate the association between a positive sedimentation sign and surgical treatment effect, defined as the difference between the average change in the surgical group minus the average change in the nonoperative group. In consideration of the observational evidence available, we hypothesized that a positive sedimentation sign may predict poorer outcomes with nonoperative treatment and/or relatively improved outcomes with surgery, thus demonstrating a greater surgical treatment effect. Our analysis focuses on the difference in outcome between the surgical group compared with the nonoperative group, which is the surgical treatment effect, because it is the key parameter in understanding the relative benefit of surgery, which in turn is the crucial piece of information in decision making for a patient weighing the choice between those 2 options.

MATERIALS AND METHODS

SPORT was a multicenter investigation that obtained prospective data from 13 spine clinics contained in 11 states. All included patients had to be surgical candidates, have a history of neurogenic claudication for a period of at least 12 weeks, and have cross-sectional imaging demonstrating stenosis. Stenosis severity was categorized as mild: dural area compromise of 1/3 or more expected; moderate: dural area compromise between 1/3 and 2/3 expected; and severe: a dural area compromise of more than 2/3 expected.²⁷ Patients with lumbar instability and degenerative spondylolisthesis were excluded from this cohort. Standard posterior decompression laminectomy comprised surgical management.²⁸ Nonoperative interventions included prescribed physical activity, counseling, steroid epidural injections, opioids, and nonsteroidal anti-inflammatory drugs.^{28,29}

The study's primary outcome measures included the 36-Item Short Form General Health Survey (SF-36) Physical Function and Bodily Pain scales,^{30,31} the stenosis bothersomeness index (SBI),^{32,33} and the modified Oswestry Disability Index (ODI).³⁴ The SF-36 is scored on a scale of 0 to 100 with larger scores indicating better function and less pain. The SBI scores range from 0 to 24 with lower scores indicating less severe symptoms, and the ODI is scored on a scale of 0 to 100 and similarly, lower scores indicate a better outcome.

A total of 654 patients with LSS were enrolled in SPORT.^{26,27} Of these patients, complete T2-weighted axial and sagittal digitized images of 115 patients were available for retrospective review, which were deidentified and electronically uploaded as Digital Imaging and Communications in Medicine files.²⁷ These images were provided to an independent orthopedic spine surgeon on individual compact discs and eFilm Light software was used to view these images (Merge Technologies, Milwaukee, WI). Each patient's T2-weighted axial images were evaluated for the presence of a positive sedimentation sign. Following the original description by Barz *et al*,²³ "a positive sedimentation sign is defined

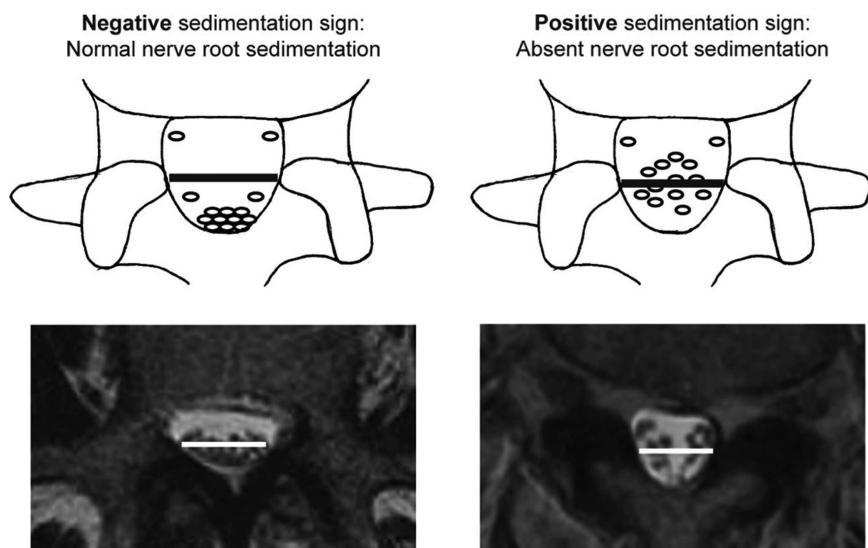


Figure 1. Left: negative sedimentation sign example (normal) and right: positive sedimentation sign (abnormal). Reproduced with permission from the study by Barz *et al*.²³

TABLE 1. Baseline Demographic Characteristics, Comorbidities, and Health Status Measures of the Patients According to Whether the Patient Had Nerve Root Sedimentation Sign

Characteristic	Sedimentation Sign		P
	Negative (n = 39)*	Positive (n = 76)*	
Age, mean (SD), yr	61.4 (11.1)	65.7 (12.9)	0.075
Females, no. (%)	19 (49)	32 (42)	0.63
Ethnicity, non-Hispanic, no. (%)†	34 (87)	70 (92)	0.61
Race, Caucasian, no. (%)†	29 (74)	63 (83)	0.40
Education, at least some college, no. (%)	28 (72)	42 (55)	0.13
Income, under \$50,000	8 (21)	16 (21)	0.86
Married, no. (%)	27 (69)	50 (66)	0.87
Work status, no. (%)			0.41
Full or part time	18 (46)	24 (32)	
Disabled	2 (5)	7 (9)	
Retired	16 (41)	35 (46)	
Other	3 (8)	10 (13)	
Disability compensation, no. (%)‡	3 (8)	3 (4)	0.68
BMI, mean (SD)§	28.3 (4.3)	29.1 (5.5)	0.42
Smoker, no. (%)	8 (21)	10 (13)	0.45
Comorbidities, no. (%)			
Hypertension	14 (36)	40 (53)	0.13
Diabetes	5 (13)	14 (18)	0.62
Osteoporosis	8 (21)	4 (5)	0.027
Heart problem	7 (18)	19 (25)	0.54
Stomach problem	10 (26)	13 (17)	0.40
Bowel or intestinal problem	5 (13)	4 (5)	0.29
Depression	5 (13)	10 (13)	0.81
Joint problem	20 (51)	37 (49)	0.95
Other¶	13 (33)	27 (36)	0.98
Time since most recent episode >6 mo, no. (%)	23 (59)	36 (47)	0.33
SF-36 scores, mean (SD)			
BP	32.7 (18.6)	32.4 (18)	0.95
PF	44.7 (26.4)	36.7 (22.6)	0.091
PCS	51.4 (10.6)	49.5 (12.9)	0.44
MCS	32.1 (8.5)	29.6 (9.3)	0.17
ODI**	42.9 (22.4)	38.9 (18.7)	0.32
Stenosis frequency index (0–24)††	14.2 (6.6)	12.7 (6.3)	0.24

(Continued)

TABLE 1. (Continued)

Characteristic	Sedimentation Sign		P
	Negative (n = 39)*	Positive (n = 76)*	
Stenosis bothersomeness index	13.7 (6.5)	13 (5.9)	0.57
Back pain bothersomeness index §§	3.9 (1.9)	4.1 (1.7)	0.47
Leg pain bothersomeness index ¶¶	4.1 (1.8)	4.1 (1.6)	0.88
Patient very dissatisfied with symptoms, no. (%)	25 (64)	48 (63)	0.92
Patient's self-assessed health trend, no. (%)			0.40
Problem getting better	3 (8)	10 (13)	
Problem staying about the same	10 (26)	24 (32)	
Problem getting worse	26 (67)	40 (53)	
Treatment preference, no. (%)			0.55
Preference for nonsurgical treatment	14 (36)	35 (46)	
Not sure	12 (31)	18 (24)	
Preference for surgery	13 (33)	23 (30)	
Neurogenic claudication, no. (%)	34 (87)	65 (86)	0.97
Pain on straight leg raising or femoral nerve tension sign, no. (%)	7 (18)	7 (9)	0.29
Dermatomal pain radiation, no. (%)	35 (90)	60 (79)	0.24
Any neurological deficit, no. (%)	25 (64)	40 (53)	0.33
Asymmetric depressed reflexes	9 (23)	18 (24)	0.87
Asymmetric decrease in sensory reflexes	15 (38)	17 (22)	0.11
Asymmetric motor weakness	13 (33)	23 (30)	0.90
Stenosis levels, no. (%)			
L2–L3	4 (10)	25 (33)	0.016
L3–L4	20 (51)	58 (76)	0.012
L4–L5	35 (90)	71 (93)	0.74
L5–S1	10 (26)	18 (24)	1
Stenotic levels (moderate/severe)			0.01
None	1 (3)	0 (0)	
1	20 (51)	19 (25)	
2	14 (36)	37 (49)	
3+	4 (10)	20 (26)	

(Continued)

TABLE 1. (Continued)

Characteristic	Sedimentation Sign		P
	Negative (n = 39)*	Positive (n = 76)*	
Stenosis locations, no. (%)			
Central	26 (67)	71 (93)	<0.001
Lateral recess	32 (82)	65 (86)	0.83
Neuroforamen	12 (31)	19 (25)	0.66
Stenosis severity, no. (%)			<0.001
Mild	1 (3)	0 (0)	
Moderate	25 (64)	21 (28)	
Severe	13 (33)	55 (72)	
Spinal instability	0 (0)	0 (0)	...
Underwent surgery***	28 (72)	47 (62)	0.39

*Total 115 patients, who had MRI/information of nerve root sedimentation sign and had at least 1 follow-up through 4 yr, are in the current analysis.

†Race or ethnic group was self-assessed. Caucasians and African Americans could be either Hispanic or non-Hispanic.

‡This category includes patients who were receiving or had applications pending for workers compensation, social security, or other compensation.

§The body mass index is the weight in kilograms divided by the square of the height in meters.

¶Other denotes problems related to stroke, cancer, lung, fibromyalgia, CFS, PTSD, alcohol, drug dependency, liver, kidney, blood vessel, nervous system, migraine, and anxiety.

||The SF-36 scores range from 0 to 100, with higher score indicating less severe symptoms.

**The ODI ranges from 0 to 100, with lower scores indicating less severe symptoms.

††The stenosis frequency index ranges from 0 to 24, with lower scores indicating less severe symptoms.

†††The stenosis bothersomeness index ranges from 0 to 24, with lower scores indicating less severe symptoms.

§§The low back pain bothersomeness index ranges from 0 to 6, with lower scores indicating less severe symptoms.

¶¶The leg pain bothersomeness index ranges from 0 to 6, with lower scores indicating less severe symptoms.

|||Spinal instability is defined as a change of more than 10° of angulation or more than 4 mm of translation of the vertebrae between flexion and extension of the spine.

***Patients who underwent surgery were classified according to whether they underwent surgical treatment during the first 4 yr of enrollment.

BMI indicates body mass index; BP, bodily pain; PF, physical functioning; PCS, physical component summary; MCS, mental component summary; ODI, Oswestry Disability Index; SF-36, 36-Item Short Form General Health Survey; MRI, magnetic resonance imaging; CFS, chronic fatigue syndrome; PTSD, post-traumatic stress disorder.

as the absence of nerve root sedimentation in at least 1 transverse MR image, at a level above or below, disregarding the location of the scan within the level and its proximity to the maximal stenosis” (Figure 1). As a result, the sign is defined as overall positive or negative for a given patient rather than level by level within a patient.

Statistical Analysis

Baseline characteristics of patients with and without a positive sedimentation sign were compared using a χ^2 test for

categorical variables and *t* tests for continuous variables. The primary analysis compared surgical and nonoperative treatments using changes from baseline at each follow-up, with a mixed effects longitudinal regression model including a random individual effect to account for correlation between repeated measurements within individuals. Because of high rates of treatment crossover, analyses were based on treatments actually received in the combined randomized and observational cohorts as described in the previous text.^{26,28}

To adjust for potential confounding, baseline variables that were significantly different between the 2 subgroups (those with and without a positive sedimentation sign) were included as adjusting covariates in the models. In addition, age, sex, and baseline outcome scores (for SF-36, ODI, and SBI) were included in all longitudinal outcome models. Across the 4-year follow-up, overall comparisons of the area under the curve between these subgroups were made using a Wald test. Computations were done using SAS PROC MIXED procedure (SAS version 9.2 Windows XP Pro; SAS Institute Inc., Cary, NC). Statistical significance was defined as $P < 0.05$ based on a 2-sided hypothesis test with no adjustments made for multiple comparisons.

RESULTS

The 115 baseline MRIs were reviewed by an independent reader who was blinded to treatment group and outcome. Sixty-six percent (76/115) of patients were found to have a positive sedimentation sign. Table 1 depicts the comparison of baseline demographics between the 2 subgroups demonstrating that individuals with a positive sedimentation sign were more likely to have stenosis at either L2–L3 (33% vs. 10%, $P = 0.016$) or L3–L4 (76% vs. 51%, $P = 0.012$), central stenosis (93% vs. 67%, $P < 0.001$), severe stenosis (72% vs. 33%, $P < 0.0001$), and have 2 or more concurrent stenotic levels (57% vs. 18%, $P = 0.01$).

Table 2 compares the surgical procedures and complications between the 2 groups. A total of 75 patients in this subgroup analysis underwent surgery, 47 of 76 (62%) of those with a positive sedimentation sign and 28 of 39 (72%) of those with a negative sign. There were no statistically significant differences in operative treatment or complication rates between the 2 subgroups.

The 4-year time-weighted average of outcome measures in the 2 subgroups is summarized in Table 3. In general, the surgical treatment effect was larger in the positive sedimentation sign group for all outcomes. This was statistically significant for ODI (−16 vs. −7; $P = 0.02$); SBI (−5.7 vs. −3.2; $P = 0.09$), SF-36 bodily pain (15.4 vs. 11.5; $P = 0.44$), and SF-36 physical function (17.7 vs. 15.1; $P = 0.61$) were not significantly different. These analyses were controlled for age, sex, baseline outcome score, osteoporosis, stenosis level, stenosis location (central vs. foraminal), and stenosis severity.

DISCUSSION

Determining the optimal treatment intervention for patients with symptomatic LSS can be difficult because the degree and location of anatomical narrowing may not correlate with

TABLE 2. Operative Treatments, Complications and Events, According to Whether the Patient Had Foraminal Stenosis

Characteristic	Sedimentation Sign		P
	Negative (n = 28)*	Positive (n = 47)*	
Procedure			0.67
Decompression only	24 (89)	41 (93)	
Noninstrumented fusion	0 (0)	0 (0)	
Instrumented fusion	3 (11)	3 (7)	
Multilevel fusion	1 (4)	3 (6)	1
Decompression level, no. (%)			
L2–L3	5 (19)	24 (51)	0.012
L3–L4	17 (65)	39 (83)	0.15
L4–L5	24 (92)	45 (96)	0.61
L5–S1	14 (54)	16 (34)	0.14
Levels decompressed, no. (%)			0.026
None	2 (7)	0 (0)	
1	4 (14)	8 (17)	
2	13 (46)	11 (23)	
3+	9 (32)	28 (60)	
Operation time, min, mean (SD)	137.4 (88.1)	151.5 (73.5)	0.46
Blood loss, mL, mean (SD)	480.3 (1001.3)	386.6 (419.8)	0.58
Blood replacement, no. (%)			
Intraoperative replacement	3 (11)	6 (13)	1
Postoperative transfusion	2 (7)	3 (7)	1
Length of hospital stay, d, mean (SD)	3.4 (2.3)	3.2 (1.7)	0.65
Intraoperative complications, no. (%)†			
Dural tear/spinal fluid leak	2 (7)	5 (11)	0.71
None	26 (93)	42 (89)	0.71
Postoperative complications/events, no. (%)‡			
Wound hematoma	1 (4)	0 (0)	0.38
Other	1 (4)	3 (7)	1
None	25 (89)	40 (87)	1
Postoperative mortality (death within 6 wk of surgery), no. (%)	0 (0)	0 (0)	
Postoperative mortality (death within 3 mo of surgery), no. (%)	0 (0)	0 (0)	
Additional surgical procedures (1-yr rate), no. (%)§	1 (4)	0 (0)	0.195

(Continued)

TABLE 2. (Continued)

Characteristic	Sedimentation Sign		P
	Negative (n = 28)*	Positive (n = 47)*	
Additional surgical procedures (2-yr rate), no. (%)§	2 (7)	2 (4)	0.59
Additional surgical procedures (3-yr rate), no. (%)§	2 (7)	3 (6)	0.89
Additional surgical procedures (4-yr rate), no. (%)§	2 (7)	4 (9)	0.84
Recurrent stenosis/progressive listhesis	0	2 (5)	
Pseudarthrosis/fusion exploration	0	0	
Complication or other	1 ¶	0	
New condition	1 ¶	1 ¶	

*Surgical information was available for 28 patients who had nonsedimentation sign and 47 patients who had sedimentation sign. Specific procedure information was available for 27 patients who had nonsedimentation sign and 44 patients who had sedimentation sign.

†None of the following were reported: aspiration, nerve root injury, vascular injury, other complication, and operation at wrong level.

‡Any reported complications up to 8 wk after operation. None of the following were reported: bone graft complication, CSF leak, nerve root injury, paralysis, cauda equina injury, pseudarthrosis, wound infection, and wound dehiscence.

§One-, 2-, 3-, and 4-yr postsurgical reoperation rates are Kaplan Meier estimates. Numbers and percentages are based on the first additional surgery if more than 1 additional surgery. Surgical procedures include any additional spine surgery not just reoperation at the same level.

¶Not estimable.

CSF indicates cerebrospinal fluid; SD, standard deviation.

symptom severity or treatment outcome. This study evaluated the association between the recently described sedimentation sign and treatment outcomes in a cohort of patients enrolled in SPORT with LSS. We found that in these patients, a positive sedimentation sign was more often associated with central stenosis, multilevel stenosis, more proximal stenoses, and more severe degrees of canal narrowing; however, after adjusting for these traditional measures of stenosis severity along with demographic factors, we found that the group with a positive sedimentation sign displayed a somewhat greater surgical treatment effect for ODI. Thus, the sedimentation sign may be a useful adjunct for physicians and patients in making informed treatment choices for LSS. Although both subgroups showed a positive treatment effect from surgery, those with a positive sedimentation sign showed a marginally increased benefit from surgery that was significant for the ODI, although not significantly different for general pain or physical function; thus the presence or absence of the sedimentation sign could potentially help sway the balance of risks and benefits in patients who are uncertain about their preferred treatment choice.

TABLE 3. Adjusted* As-Treated Time-Weighted Average 4-Year Outcomes and Treatment Effects According to Whether the Patient Had Nerve Root Sedimentation Sign

Outcome	Nerve Root Sedimentation Sign	Surgical, Mean (SE)	Nonoperative, Mean (SE)	Treatment Effect† (95% CI)	P
SF-36 bodily pain	Negative sedimentation sign	26.3 (3.9)	14.8 (4.6)	11.5 (3.2–19.9)	0.007
(BP) (0–100)‡	Positive sedimentation sign	26.4 (3)	10.9 (3.1)	15.5 (9.1–21.8)	<0.001
	P	0.98	0.50	0.44	
SF-36 physical function	Negative sedimentation sign	21.1 (4.1)	6 (4.7)	15.1 (6.9–23.3)	<0.001
(PF) (0–100)‡	Positive sedimentation sign	21 (3.1)	3.3 (3.2)	17.7 (11.5–23.8)	<0.001
	P	0.99	0.65	0.61	
Oswestry Disability Index	Negative sedimentation sign	–16.2 (3)	–9.1 (3.5)	–7 (–13.3 to –0.8)	0.028
ODI (0–100)§	Positive sedimentation sign	–20.4 (2.2)	–4.4 (2.4)	–16 (–20.8 to –11.1)	<0.001
	P	0.28	0.28	0.023	
Stenosis bothersomeness index	Negative sedimentation sign	–6.1 (1)	–2.9 (1.2)	–3.2 (–5.6 to –0.8)	0.01
(0–24)¶	Positive sedimentation sign	–7.5 (0.8)	–1.9 (0.8)	–5.7 (–7.6 to –3.7)	<0.001
	P	0.25	0.49	0.094	

*Adjusted for age, sex, baseline outcome score, osteoporosis, L2–L3 stenosis level, L3–L4 stenosis level, central stenosis, and stenosis severity.

†Treatment effect is the difference between the surgical and nonoperative mean change from baseline. Analysis is done using a mixed model with a random subject intercept term. Treatment is a time-varying covariate where a patient's experience prior to surgery is attributed to the nonoperative arm and time is measured from enrollment and his/her postsurgery outcomes are attributed to the surgical arm and time is measured from time of surgery.

‡The SF-36 scores range from 0 to 100, with higher score indicating less severe symptoms.

§The ODI ranges from 0 to 100, with lower scores indicating less severe symptoms.

¶The Stenosis bothersomeness index ranges from 0 to 24, with lower scores indicating less severe symptoms.

ODI indicates Oswestry Disability Index; SF-36, 36-Item Short Form General Health Survey; SE, standard error; PF, physical function; BP, body pain; CI, confidence level.

Several studies have evaluated MRI characteristics that may be associated with LSS severity and treatment effect, most notably, the dural sac cross-sectional area. However, these studies failed to find a significant relationship between anatomical narrowing, clinical severity, and treatment effect.^{5,7,8,11,15,18,19,22} Earlier studies revealed not only a wide range of results for both surgical and nonoperative interventions, but also failed to find a significant predictive characteristic. For example, Amundsen *et al*^{5,6} conducted a prospective study evaluating the imaging characteristics associated with LSS and found no correlation between the degree of dural sac narrowing and clinical disability or treatment effect.

Several other findings of our study are consistent with prior studies. A positive sedimentation sign was strongly associated with central stenosis, whereas the negative sedimentation sign group was more likely to have only lateral recess or neuroforaminal stenosis; similarly, a positive sedimentation sign was associated with multiple stenotic levels (86% *vs.* 46% in the negative sedimentation sign group, $P = 0.01$).^{23,35} Because Barz *et al*²³ only recently introduced the sedimentation sign, there are not many directly comparable studies that evaluated the association between the sedimentation sign and treatment outcomes. The observational study by Barz *et al*²⁵ showed

that the sedimentation sign does not seem to predict surgical outcome, whereas in nonoperatively treated patients a positive sign was associated with a limited treatment outcome.

This study faced several limitations. This was a *post hoc* subgroup analysis from the SPORT study and used an observational, as-treated analysis due to high levels of treatment crossover in the randomized groups. However, we did use longitudinal mixed-models to attempt to control for confounding by any baseline differences between the subgroups. Furthermore, although excluded in the initial study by Barz *et al*,²³ patients who had LSS at L5–S1 were included in this study. However, there were only 4 patients who had only single-level L5–S1 stenosis, and on further analysis, only one of these had a positive sedimentation sign. Although the treatment effect results were consistent for the main outcome measures, they were statistically significant only for ODI and as such must be interpreted cautiously. It is worth noting, however, that the 2 measures (ODI and SBI) with the more suggestive findings were condition-specific outcome measure, which may be more responsive than the more general SF-36 measures. Also, because this was a subgroup analysis using previously collected and archived MRIs, our sample size and thus the power to detect a difference was somewhat limited.

We also cannot be sure that the subgroup for whom complete imaging was available is representative of the overall stenosis cohort; prior studies with this data, however, suggest that measure demographic and imaging characteristics were similar between the groups with and without archived imaging data.²⁷ Furthermore, we relied on clinically obtained images with varying image acquisition protocols, field strength, slice orientation, *etc.* This heterogeneity of imaging characteristics may have limited our ability to fully assess the association between sedimentation sign and treatment outcome.

This study employed an innovative approach by linking the assessment of a new diagnostic test with the evaluation of treatment effects. This type of test evaluation has been referred to as “clinical test validation”^{24,36} providing direct evidence about the clinical meaning of test results, which is far more relevant information for clinicians than measures of test accuracy alone (*e.g.*, test sensitivity and specificity). SPORT offers a unique opportunity to evaluate emerging radiological tests, because the archived MR images can be revisited when new radiological criteria like the sedimentation sign are discovered. It would be desirable if establishing trial-based digital archives of imaging data became standard practice in the conduct of treatment trials to enable test evaluations such as the one presented here.

CONCLUSION

In this preliminary study, we demonstrated that controlling for other demographic and imaging features, a positive sedimentation sign was associated with a somewhat greater surgical treatment effect in patients with symptomatic LSS for ODI, though not for other measured outcomes. These findings suggest that a positive sedimentation sign may be useful as an adjunct to help guide an informed treatment choice regarding surgery for patients with symptomatic LSS. The presence or absence of the sedimentation sign, which seems to help predict the size of the surgical treatment after adjusting for other traditional measures of stenosis severity, may help sway the balance of risks and benefits in patients who are uncertain about their preferred treatment choice.

➤ Key Points

- ❑ LSS is one of the most common reasons for surgery in the US elderly, but there is a dearth of reliable diagnostic tools that give a clear indication for surgery.
- ❑ T2-weighted images of patients with LSS enrolled in SPORT were analyzed by an independent orthopedic surgeon for sedimentation sign.
- ❑ Also, 66% of the 115 patients whose images were analyzed were found to have a positive sedimentation sign.
- ❑ Surgical treatment effects for those patients with positive sedimentation sign were somewhat larger in all outcomes, and significant for ODI (-16 vs. -7 ; $P = 0.02$), after adjusting for other demographic and imaging features.

References

1. Verbiest H. A radicular syndrome from developmental narrowing of the lumbar vertebral canal. 1954. *Clin Orthop Relat Res* 2001;384:3–9.
2. Ciol MA, Deyo RA, Howell E, et al. An assessment of surgery for spinal stenosis: time trends, geographic variations, complications, and reoperations. *J Am Geriatr Soc* 1996;44:285–90.
3. Katz JN, Harris MB. Clinical practice. Lumbar spinal stenosis. *N Engl J Med* 2008;358:818–25.
4. Aalto TJ, Malmivaara A, Kovacs F, et al. Preoperative predictors for postoperative clinical outcome in lumbar spinal stenosis: systematic review. *Spine (Phila Pa 1976)* 2006;31:E648–63.
5. Amundsen T, Weber H, Lilleas F, et al. Lumbar spinal stenosis. Clinical and radiologic features. *Spine (Phila Pa 1976)* 1995;20:1178–86.
6. Amundsen T, Weber H, Nordal HJ, et al. Lumbar spinal stenosis: conservative or surgical management?: A prospective 10-year study. *Spine (Phila Pa 1976)* 2000;25:1424–35; discussion 35–6.
7. Fritz JM, Delitto A, Welch WC, et al. Lumbar spinal stenosis: a review of current concepts in evaluation, management, and outcome measurements. *Arch Phys Med Rehabil* 1998;79:700–8.
8. Herno A, Airaksinen O, Saari T, et al. Lumbar spinal stenosis: a matched-pair study of operated and nonoperated patients. *Br J Neurosurg* 1996;10:461–5.
9. Herno A, Airaksinen O, Saari T, et al. The effect of prior back surgery on surgical outcome in patients operated on for lumbar spinal stenosis. A matched-pair study. *Acta Neurochir (Wien)* 1996;138:357–63.
10. Sirvanci M, Bhatia M, Ganiyusufoglu KA, et al. Degenerative lumbar spinal stenosis: correlation with Oswestry Disability Index and MR imaging. *Eur Spine J* 2008;17:679–85.
11. Barz T, Melloh M, Staub L, et al. The diagnostic value of a treadmill test in predicting lumbar spinal stenosis. *Eur Spine J* 2008;17:686–90.
12. Deen HG, Jr, Zimmerman RS, Lyons MK, et al. Measurement of exercise tolerance on the treadmill in patients with symptomatic lumbar spinal stenosis: a useful indicator of functional status and surgical outcome. *J Neurosurg* 1995;83:27–30.
13. Deen HG, Zimmerman RS, Lyons MK, et al. Use of the exercise treadmill to measure baseline functional status and surgical outcome in patients with severe lumbar spinal stenosis. *Spine (Phila Pa 1976)* 1998;23:244–8.
14. Jane JA, Sr, Jane JA, Jr, Helm GA, et al. Acquired lumbar spinal stenosis. *Clin Neurosurg* 1996;43:275–99.
15. Katz JN, Dalgas M, Stucki G, et al. Degenerative lumbar spinal stenosis. Diagnostic value of the history and physical examination. *Arthritis Rheum* 1995;38:1236–41.
16. Hamanishi C, Matukura N, Fujita M, et al. Cross-sectional area of the stenotic lumbar dural tube measured from the transverse views of magnetic resonance imaging. *J Spinal Disord* 1994;7:388–93.
17. Ogikubo O, Forsberg L, Hansson T. The relationship between the cross-sectional area of the cauda equina and the preoperative symptoms in central lumbar spinal stenosis. *Spine (Phila Pa 1976)* 2007;32:1423–8; discussion 9.
18. Boswell MV, Trescot AM, Datta S, et al. Interventional techniques: evidence-based practice guidelines in the management of chronic spinal pain. *Pain Physician* 2007;10:7–111.
19. Gibson JN, Waddell G. Surgery for degenerative lumbar spondylosis: updated Cochrane Review. *Spine (Phila Pa 1976)* 2005;30:2312–20.
20. Gibson JN, Waddell G. Surgery for degenerative lumbar spondylosis. *Cochrane Database Syst Rev* 2005;30:CD001352.
21. Konno S, Kikuchi S, Tanaka Y, et al. A diagnostic support tool for lumbar spinal stenosis: a self-administered, self-reported history questionnaire. *BMC Musculoskelet Disord* 2007;8:102.
22. Konno S, Hayashino Y, Fukuhara S, et al. Development of a clinical diagnosis support tool to identify patients with lumbar spinal stenosis. *Eur Spine J* 2007;16:1951–7.
23. Barz T, Melloh M, Staub LP, et al. Nerve root sedimentation sign: evaluation of a new radiological sign in lumbar spinal stenosis. *Spine (Phila Pa 1976)* 2010;35:892–7.

24. Staub LP, Barz T, Melloh M, et al. Clinical validation study to measure the performance of the nerve root sedimentation sign for the diagnosis of lumbar spinal stenosis. *Contemp Clin Trials* 2009;32:470-4.
25. Barz T, Staub LP, Melloh M, et al. Clinical validity of the nerve root sedimentation sign in patients with suspected lumbar spinal stenosis. *Spine J* 2013;14:667-74.
26. Weinstein JN, Tosteson TD, Lurie JD, et al. Surgical versus nonsurgical therapy for lumbar spinal stenosis. *N Engl J Med* 2008;358:794-810.
27. Lurie JD, Tosteson AN, Tosteson TD, et al. Reliability of readings of magnetic resonance imaging features of lumbar spinal stenosis. *Spine (Phila Pa 1976)* 2008;33:1605-10.
28. Birkmeyer NJ, Weinstein JN, Tosteson AN, et al. Design of the Spine Patient outcomes Research Trial (SPORT). *Spine (Phila Pa 1976)* 2002;27:1361-72.
29. Cummins J, Lurie JD, Tosteson TD, et al. Descriptive epidemiology and prior healthcare utilization of patients in the Spine Patient Outcomes Research Trial's (SPORT) three observational cohorts: disc herniation, spinal stenosis, and degenerative spondylolisthesis. *Spine (Phila Pa 1976)* 2006;31:806-14.
30. Ware JE, Jr, Sherbourne CD. The MOS 36-Item Short-Form Health Survey (SF-36). I. Conceptual framework and item selection. *Med Care* 1992;30:473-83.
31. McHorney CA, Ware JE, Jr, Lu JF, et al. The MOS 36-Item Short-Form Health Survey (SF-36): III. Tests of data quality, scaling assumptions, and reliability across diverse patient groups. *Med Care* 1994;32:40-66.
32. Patrick DL, Deyo RA, Atlas SJ, et al. Assessing health-related quality of life in patients with sciatica. *Spine (Phila Pa 1976)* 1995;20:1899-908; discussion 909.
33. Atlas SJ, Deyo RA, Keller RB, et al. The Maine Lumbar Spine Study, Part III. 1-year outcomes of surgical and nonsurgical management of lumbar spinal stenosis. *Spine (Phila Pa 1976)* 1996;21:1787-94; discussion 94-5.
34. Fairbank JC, Couper J, Davies JB, et al. The Oswestry Low Back Pain Disability Questionnaire. *Physiotherapy* 1980;66:271-3.
35. Macedo LG, Wang Y, Battie MC. The sedimentation sign for differential diagnosis of lumbar spinal stenosis. *Spine (Phila Pa 1976)* 2012;38:827-31.
36. Reitsma JB, Rutjes AW, Khan KS, et al. A review of solutions for diagnostic accuracy studies with an imperfect or missing reference standard. *J Clin Epidemiol* 2009;62:797-806.