Eur Arch Otorhinolaryngol (2016) 273:3943–3949
DOI 10.1007/s00405-016-4049-7

HEAD AND NECK

Pectoralis major myofascial interposition flap prevents postoperative pharyngocutaneous fistula in salvage total laryngectomy

Lukas Anschütz[1] · Lluís Nisa[1,2,3] · Olgun Elicin[3] · Beat Bojaxhiu[3] · Marco Caversaccio[1] · Roland Giger[1]

Received: 28 February 2015 / Accepted: 12 April 2016 / Published online: 23 April 2016

Abstract Pharyngocutaneous fistula (PCF) is the most cumbersome complication after salvage total laryngectomy (STL) in patients who have been previously irradiated for laryngeal or hypopharyngeal cancer. To assess the fistula rate, risk factors and effects of primary closure with and without pectoralis major myofascial interposition flap (PMMIF) on fistula formation, we conducted a retrospective review. We identified 48 patients from 2004 to 2013 who underwent STL after failure of primary curative (chemo)radiotherapy in laryngeal or hypopharyngeal cancer. Details of risk factors for PCF formation, other postoperative complications and general outcome data were analyzed. Ten (20.8 %) out of 48 patients underwent STL with PMMIF closure. Patient and tumor features were not different between the groups with or without PMMIF closure. PCF rates were 0 and 42.1 % in patients with and without PMMIF, respectively ($p = 0.002$). Other operative complications were similar. We identified prior neck irradiation to be a risk factor for fistula formation ($p = 0.04$). Patients without PCF had a statistically significant reduction of average hospital stay (20 vs. 56 days; $p = 0.001$). Analysis of fistula management revealed 50 % of PCF to be closed secondarily by a pectoralis major myocutaneous flap. Over one-third of fistulae persisted despite attempted surgical closure in some cases. PMMIF is useful to prevent PCF in STL following (chemo)radiotherapy. Neck irradiation during primary treatment is a risk factor for PCF formation.

Keywords Salvage laryngectomy · Salvage surgery · Pectoralis major myofascial interposition flap · Pharyngocutaneous fistula

✉ Roland Giger
roland.giger@insel.ch

[1] Department of Otorhinolaryngology-Head and Neck Surgery, Inselspital, Bern University Hospital, University of Bern, 3010 Bern, Switzerland

[2] Department of Clinical Research, University of Bern, 3010 Bern, Switzerland

[3] Department of Radiation Oncology, Inselspital, Bern University Hospital, University of Bern, 3010 Bern, Switzerland

Introduction

Primary curative (chemo)radiotherapy [(C)RT] is a widely accepted and efficient treatment strategy for laryngeal and hypopharyngeal squamous cell carcinoma (SCC). With the emergence of organ-sparing strategies, the use of primary total laryngectomy in locally advanced cancer has significantly decreased over the last two decades [1–3]. However, the need for salvage treatment for local tumor persistence or recurrence after irradiation is a common issue [4].

Wound healing in a previously irradiated neck region is often impaired because of widespread scarring, fibrotic tissue remodeling and altered perfusion of irradiated tissues [5]. The Radiation Therapy Oncology Group (RTOG) data revealed an incidence of impaired wound healing following salvage total laryngectomy (STL) in as much as 59–64 % of patients [4]. The complication carrying the most significant impact on patients' quality of life and length of hospitalization is the occurrence of pharyngocutaneous fistula (PCF). The estimated incidence is approximately 35 % [10].

Previously reported risk factors for PCF development include preoperative RT, tumor stage, concomitant neck dissection, prior need for tracheotomy, hypoalbuminemia

and low postoperative hemoglobin [4, 10, 21, 23]. Salivary leakage leads to additional wound healing disturbances, as well as delayed oral feeding and, therefore, dependence on feeding tubes. In rare cases, erosion of large neck or mediastinal vessels with a consequent vascular blowout can lead to further deterioration or death [13]. A prolonged hospital stay and subsequent treatments represent an important personal and public health burden.

Different surgical techniques have been described to reduce the risk of PCF and other postoperative complications in STL [15, 16]. The neopharyngeal suture is considered to be the "locus minoris resistenciae" for PCF formation. Among surgical options, the pectoralis major myofascial flap has been proposed to cover the pharyngeal closure, to interpose non-irradiated tissue between the neopharynx and the skin during STL [17, 18]. Nonetheless, the efficacy of this approach is not fully established [15, 19–21].

The aim of this study is to assess the impact of primary closure with pectoralis major myofascial interposition flap (PMMIF) versus primary closure without PMMIF on the occurrence of PCF and other complications in patients undergoing STL after (C)RT. We intend to find pre- and perioperative risk factors that might increase the incidence of fistulae.

Patients and methods

Ethical issues

Our institutional and regional review board (Inselspital, Bern University Hospital, Bern, Switzerland) granted approval to perform the present retrospective study.

Retrospective patient file study

We reviewed the paper- and computer-based records of all patients undergoing STL for laryngeal or hypopharyngeal SCC between 2004 and 2013 at our institution. All patients were initially treated by (C)RT alone with curative intent. Patients who did not complete (C)RT or had up-front neck dissection during initial organ-preservation treatment were excluded. Moreover, we included only patients who underwent either primary closure with or without PMMIF. Patients requiring other types of pharyngeal reconstruction (e.g., free microvascular flap, pectoralis major myocutaneous flap, etc.) resulting from extended pharyngo-laryngeal resections were excluded. Patients with distant metastases at the moment of recurrence were excluded, as were patients with neoplastic fistulae secondary to persistent disease and grossly positive margins. A minimal follow-up of 6 months after surgery was required.

Operative strategy

All STLs were performed by two chief physicians with comparable experience and training or by two experienced consultants who were thoroughly supervised by the formers. No muscular reinforcement was used in STL until 2011. Since 2012, we changed our policy regarding STL and started to perform PMMIF systematically.

In all PMMIF patients, the neopharynx was closed primarily and the muscular flap was laid (interposed) between the pharyngeal closure and the skin. This operative technique is schematically shown in Fig. 1.

Data extraction

We assessed patients' characteristics, initial tumor stage, features of primary treatment (dose distribution, administration of chemotherapy, etc.), type of recurrence (local, regional, loco-regional), time to treatment failure from the end of (C)RT, time to salvage surgery, related complications and length of hospital stay. We reviewed charts for the development of PCF and its management.

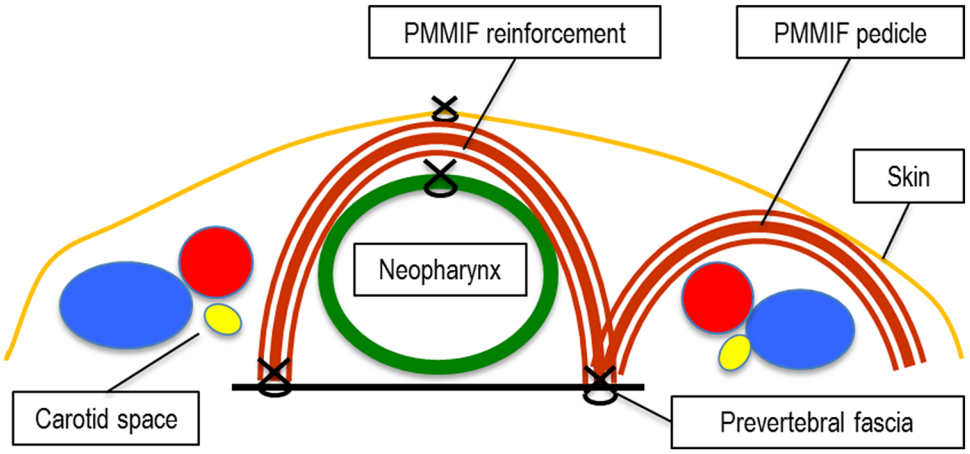

Fig. 1 Schematic illustration of PMMIF reinforcement following salvage total laryngectomy. *PMMIF* pectoralis major myofascial interposition flap

Statistical data analysis

We considered two groups based on the pharyngeal closure technique (primary closure with and without PMMIF technique) at the time of the first or second salvage. Descriptive and inferential statistics were performed to compare both groups. Subgroups were compared by performing Chi square statistics for nominal parameters and by performing Wilcoxon–Mann–Whitney tests for continuous parameters, with the two-tailed alpha set to 0.05. A multivariate analysis by building a nominal logistic regression model was performed to assess the risk factors for PCF formation by including variables with $p < 0.1$ in the univariate analysis, but keeping only variables with a $p < 0.05$ for the final model using backward elimination.

Results

We reviewed 86 total laryngectomies performed between 2004 and 2013. Thirty-eight patients did not fulfill the inclusion criteria. In total, 48 patients undergoing STL with available postoperative clinical follow-up data, to document the occurrence of PCF, were considered. The group with the PMMIF closure technique included 10 patients (20.8 %) and the primary closure group without PMMIF included 38 patients (79.2 %). Patients, disease and initial treatment characteristics are summarized in Table 1.

There were two groups of patients undergoing STL; one group after a first relapse ($n = 37$) and the other group after a second relapse, where patients had already undergone transoral or open partial laryngectomies for the first relapse ($n = 11$). Detailed features of relapse and treatment modalities are summarized in Table 2.

In the present cohort, 16 patients (33.3 %) had documented PCFs. Fistulae were only observed in patients who underwent initial primary closure without PMMIF (42.1 %) compared to patients who had PMMIF onlay (0 %) ($p = 0.002$). The distribution of PCFs according to type of relapse and type of closure is reported in Table 2. Other common postoperative complications shown in Fig. 2 were comparable without significant differences between both groups.

Risk factor analysis for fistula formation is shown in Table 3. In addition to closure technique, we identified previous neck irradiation ($p = 0.04$) as a statistically significant risk factor. None of the other analyzed risk factors were identified as significant. Importantly, the lack of events (i.e., PCF) in the PMMIF group raises questions about the validity of PMMIF as a risk factor. Nevertheless, our analysis revealed a trend worth mentioning regarding neck treatment; we found the curative nodal irradiation dose to the neck (≥70 Gy) to present a tendency towards higher PCF incidence ($p = 0.07$).

Average hospital stay was 56 days (range 15–141) and 20 days (range 15–76) in patients with and without PCF, respectively ($p = 0.001$). With respect to type of closure, patients with primary closure without PMMIF had an average stay of 21 days (range 15–141) in comparison with 19 days (range 15–29) in patients with PMMIF ($p = 0.08$).

Regarding management of the 16 PCFs, approaches were divided into conservative treatment only, primary fistula closure and closure by loco-regional flaps as shown in Fig. 3. In eight cases (50 %), a pectoralis major myocutaneous flap was used to close the fistula. For six patients, an expectant conservative treatment was chosen and two cases underwent PCF suturing without any flap insertion. Finally, in 6 patients, the fistula could not be closed and persisted until the end of follow-up.

Discussion

Postoperative PCF remains a significant problem after STL, carrying a high risk of postoperative infection, wound breakdown and subsequent damage to nearby tissue and blood vessels, including potential carotid artery blowout [13]. Subjects with a history of RT are particularly susceptible to such wound complications [5]. The required use of medical, personal and psychological resources causes a considerable problem in the already difficult setting of recurrent laryngeal and hypopharyngeal cancers [7, 11].

Several surgical strategies to minimize PCF development following STL have been explored. Among those, the transfer of non-irradiated tissue to the surgical field is suitable to minimize major complications, such as fistula formation and the need for surgical revision [6]. The idea behind this concept is to reinforce the fragile suture of the neopharynx after STL to reduce the risk of PCF formation. PMMIF is used to cover the previously irradiated soft tissue and mucosa of the neopharynx with non-irradiated, well-vascularized tissue. It is then fixed to the parapharyngeal soft tissue and the prevertebral fascia on both sides to separate the neopharynx from the carotid space (Fig. 1).

A number of studies have previously assessed the potential usefulness of PMMIF in STL. Righini et al. identified a trend towards PCF reduction using PMMIF, describing a PCF incidence of 23 % with PMMIF and 50 % when no flap was used ($p = 0.06$) [20]. Patel and Keni described PMMIF to be a useful strategy to reduce PCF (57 vs. 0 % $p = 0.015$) in primary ($n = 26$) and salvage ($n = 17$) total laryngectomy [22]. Oosthuizen et al. described identical PCF rates (25 %) with or without PMMIF reinforcement but showed a significant reduction in the mean duration until fistula closure in the PMMIF

Table 1 Patients, disease and initial treatment characteristics

Characteristics	Whole cohort $n = 48$	PMMIF $n = 10$	No PMMIF $n = 38$	p value
Gender (f/m)	2/46	1/9	1/37	0.35
Mean age at initial diagnosis; years (range)	62.7 (38–80)	62.5 (49–79)	62.7 (38–80)	0.78
Initial tumor subsite				0.59
Supraglottic	13/27.1 %	1/10 %	12/31.6 %	
Glottic	24/50 %	6/60 %	18/47.4 %	
Subglottic	2/4.2 %	1/10 %	1/2.6 %	
Transglottic	5/10.4 %	1/10 %	4/10.5 %	
Hypopharynx	4/8.3 %	1/10 %	3/7.9 %	
Initial cT-Status				0.31
cT1–2	38/89.1 %	9/90 %	29/76.3 %	
cT3–4	10/20.9 %	1/10 %	9/23.7 %	
Initial cN-status				0.08
cN0	42/87.5 %	8/80 %	34/89.5 %	
cN1	5/10.4 %	1/10 %	4/10.5 %	
cN2	1/2.1 %	1/10 %	0/0 %	
cN3	0/0 %	0/0 %	0/0 %	
Initial clinical stage (UICC)				0.80
Stage I–II	37/77 %	8/80 %	29/76.3 %	
Stage III–IV	11/23 %	2/20 %	9/23.7 %	
Primary treatment				
IMRT[a]	18/37.5 %	7/70 %	11/28.9 %	0.02
Mean total dose to primary tumor; Gy (range)	70.3 (64–72)	70.6 (68–72)	70.3 (64–72)	0.71
Mean total dose to cN+ nodes; Gy (range)	72 (72–72)	72 (72–72)	72 (72–72)	–
Mean total dose to lymphatic basin; Gy (range)	39.5 (0–72)	59.1 (54–72)	31.1 (0–72)	0.93
cCX	20/41.7 %	4/40 %	16/42.1 %	0.90
Type of 1. relapse treated with STL				0.52
Local only	34/91.9 %	7/100 %	27/90 %	
Loco-regional	3/8.1 %	0/0 %	3/10 %	
Type of 2. relapse treated with STL				0.44
Local only	9/81.8 %	2/66.7 %	7/87.5 %	
Loco-regional	2/18.2 %	1/33.3 %	1/12.5 %	

Data are presented as mean values for continuous variables and as number of subjects for categorical variables

cCX concomitant chemotherapy, *f* female, *Gy* Gray, *m* male, *IMRT* intensity-modulated radiotherapy, *no PMMIF/PMMIF* primary closure without/with pectoralis major myofascial interposition flap, *STL* salvage total laryngectomy, *UICC* union for international cancer control

[a] The rest is treated with 3-dimensional conformal radiotherapy technique

group (57.16 vs. 20.5 days) [19]. Gilbert et al. found a reduction of PCF of 44.7 to 9.5 % for primary closure without PMMIF versus closure with PMMIF, respectively [12]. In contrast, Gil et al. showed no benefit from PMMIF in decreasing fistula formation (27 vs. 24 %), but unlike our series, the authors included a heterogeneous cohort with and without prior (C)RT [17].

In a recent multicenter retrospective study with 359 previously irradiated patients, Patel et al. reported a significant reduction of PCF rates when transferring non-irradiated, vascularized tissue into the surgical field [7]. They compared three techniques in STL: primary closure without reinforcement, onlay PMMIF, and free interposed tissue. Fistula formation was significantly reduced with PMMIF (15 %) compared to primary closure without PMMIF (34 %) ($p = 0.02$). In the free interposed tissue group, fistula incidence was also reduced (25 %) but without reaching a level of statistical significance ($p = 0.07$) [7]. The authors also found that fistulae closed faster in the PMMIF group. In a systematic review with pooled data ($n = 591$ patients), Paleri et al. demonstrated a relative risk of 0.63 for PCF in patients with any flap reconstruction following STL compared to primary closure of the neopharynx without flap use [11]. These results

Table 2 Summary of STL according 1st/2nd relapse and PCF formation

Median time to 1st relapse in months (range)	15.5 (2–145)
	***n* (+PMMIF)**
STL for 1st relapse	37 (7)
With ND	35 (7)
Without ND	2 (0)
PCF after STL for 1st relapse: no PMMIF/PMMIF	15/0
Median time to 2nd relapse (from 1st) in months (range)	13.5 (2–98)
	***n* (+PMMIF)**
STL for 2nd relapse	11 (3)
With ND	10 (3)
Without ND	1 (0)
PCF after STL for 2nd relapse: no PMMIF/PMMIF	1/0

n number of patients, *PCF* pharyngocutaneous fistula, *no PMMIF/PMMIF* primary closure without/with pectoralis major myofascial interposition flap, *STL* salvage total laryngectomy, *ND* neck dissection

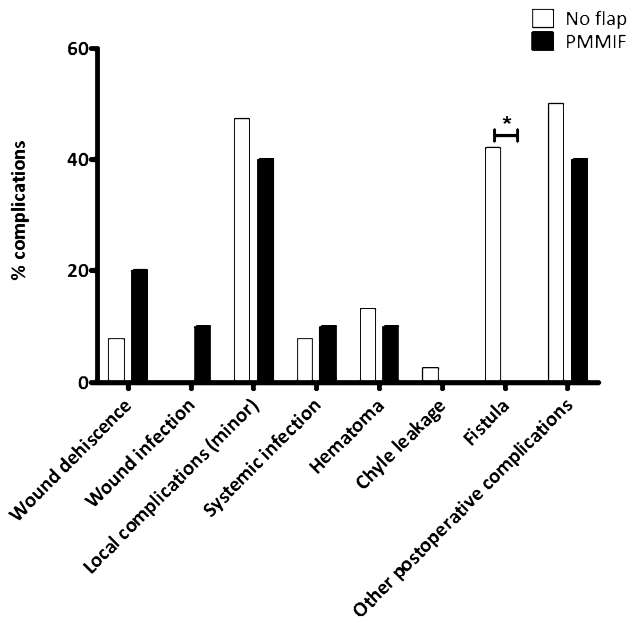

Fig. 2 Postoperative complications following salvage total laryngectomy. The incidence of pharyngocutaneous fistulae is significantly reduced when using PMMIF reinforcement ($p = 0.002$*). Other complications do not differ significantly between primary closure with and without PMMIF. *PMMIF* pectoralis major myofascial interposition flap

strongly stress the utility of transferring non-irradiated tissue in the STL field. Ongoing debate exists regarding optimal strategies for tissue transfer (i.e., free vs. pedicled flaps).

Regarding myocutaneous pectoralis flaps, Khan et al. showed that the use of an integrated pectoralis myocutaneous flap had no beneficial effect on PCF (33.3 %) formation compared to the PMMIF onlay technique (26.3 %) [8]. Gilbert et al. even found that the pectoralis major myocutaneous flap technique has no significant advantage concerning PCF formation (28.6 %) compared to primary pharyngeal closure (44.7 %) [12]. We have to consider that the myocutaneous flaps are used to close the neopharynx when extended resection is necessary for disease control. Therefore, outcome comparisons between insertion and onlay/interposition techniques are not appropriate.

Our study aimed to address the incidence of PCFs relative to closure technique in STL in the specific frame of patients with recurrence of laryngeal or hypopharyngeal cancer after radical (C)RT. Our data, consistent with previous publications, confirm the prevention of PCFs with the PMMIF onlay technique in STL ($p = 0.02$) [6–8, 11, 12, 19, 20, 22].

The present cohort is a very homogeneous patient collective after primary (C)RT for laryngeal and hypopharyngeal cancers. Because of the exclusion of extended pharyngo-laryngeal resections as well as techniques other than primary closure with and without PMMIF, the effect of the PMMIF onlay technique on PCF occurrence could be clearly assessed. The decision to raise a PMMIF or not, was taken on principle; before 2012, no muscular reinforcement was used in STL, and since 2012, all STLs were performed with PMMIF. The two chief physicians performing or supervising all procedures had comparable experience and their operated patients did not show significant different rates of other postoperative complications than PCFs. Raising a PMMIF, compared to microvascular free flaps, is relatively easy and does not need supplementary specialized equipment or cumbersome postoperative flap controls. Correctly performed, it is not associated with major complications and sequelae and requires only minimal extra time in the operation room [9]. However, PMMIF harvesting is not without morbidity and its cervical onlay has subsequent cutbacks in patients' quality of life, such as impaired movement of shoulder and neck, difficulty of swallowing because of the flap thickness and the feel of a cervical mass [9, 14]. The cosmetic impact of PMMIF should be especially considered in younger patients, in which free flaps may be more advantageous in this sense. Nevertheless, one can argue that potential morbidity because of raising and inserting the PMMIF largely outweighs the morbidity of a possible PCF. We also have to consider that rehabilitation of speech and swallowing is only feasible with correct wound healing. As expected, the duration of hospitalization and associated costs were increased by the occurrence of PCF (average 20 vs. 56.5 days, $p = 0.001$).

The relevance of previously reported risk factors for PCF formation in STL such as tumor site and size, concomitant neck dissection, prior need for tracheotomy, preoperative hypoalbuminemia, hypothyroidism and low postoperative

Table 3 Risk factors for PCF formation

	N	PCF incidence (%)	OR (95 % CI)	*p* value
Whole cohort	48	33.3	–	–
Male gender	46	32.6	0.48 (0.02–12.79	0.62
Age >62	23	39.1	1.65 (0.50–5.71)	0.41
PMMIF	10	0	<0.01 (. -<0.01)[a]	**0.002**
Concomitant ND in STL	45	33	1 (0.04–11.26)	1.00
Prior chemotherapy	20	40	1.67 (0.49–5.72)	0.41
Initial IMRT	18	38.9	1.48 (0.43–5.11)	0.53
Neck irradiation before STL	33	42.4	4.79 (1.09–33.86)	**0.04**
Neck node irradiation ≥70 Gy	6	66.7	5 (0.86–39.67)	0.07
Initial tumor stage (≥III)	11	45.5	1.99 (0.48–7.96)	0.34
Hypopharyngeal tumor	4	50	2.14 (0.24–19.40)	0.47
Reirradiation after STL	13	46.2	2.14 (0.57–8.12)	0.26
End of (C)RT and STL >13 months	23	26.1	0.53 (0.15–1.76)	0.31

Bold values indicate statistically significant

CI confidence intervals, *Gy* gray, *IMRT* intensity-modulated radiotherapy, *ND* neck dissection, *PCF* pharyngocutaneous fistula, *PMMIF* primary closure with pectoralis major myofascial interposition flap, *(C)RT* (chemo)radiotherapy, *STL* salvage total laryngectomy

[a] Questionable due to lack of events

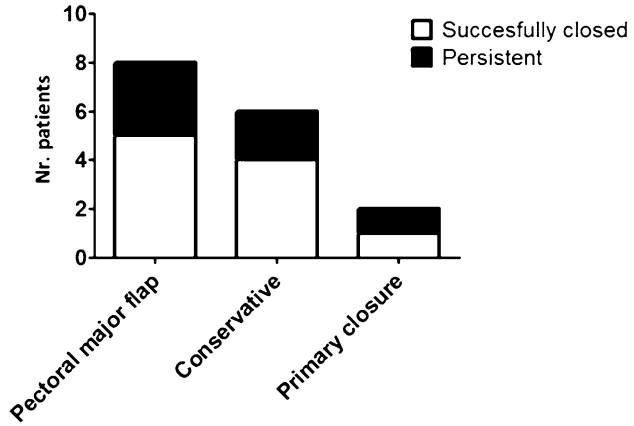

Fig. 3 Management and outcome of pharyngocutaneous fistulae. One-third of the fistulae persisted until the end of follow-up

hemoglobin are currently debated [4, 10, 12, 21, 23]. We examined a number of variables and their association with PCF (Table 3) and only identified neopharyngeal closure type and prior neck irradiation as statistically significant risk factors. In our cohort, the initial cT-status may have a tendency towards smaller tumors in the PMMIF group, although this tendency was not statistically significant.

Our study has the following limitations. It is a retrospective study containing a relatively small sample size; the study has an asymmetry in terms of group size. Next, the 0 % rates of PCF formation in the PMMIF group may be associated with the sample size. Nevertheless, based on our results and the limited evidence so far, the use of PMMIF is efficient in reducing postoperative events of PCF after STL. The fact that 50 % of postoperative PCFs (which represents 21 % of patients with primary closure without PMMIF) needed a pectoralis major myocutaneous flap to repair the fistulae, indicates that the use of PMMIF should be considered as the primary and not as the backup strategy.

Conclusion

PCF is a serious complication of STL following (C)RT for laryngeal or hypopharyngeal cancer. The present retrospective study suggests that the insertion of non-irradiated tissue during STL in the manner of an onlay technique with PMMIF is a useful method to reduce the incidence of PCF. Patients with fistulae have prolonged hospital stays. Neck irradiation is a risk factor for PCF formation. The PMMIF technique in STL should be considered when performing primary closure of the neopharynx to prevent postoperative PCFs.

Compliance with Ethical Standards

Conflict of interest The authors declare no conflict of interest.

Research involving human participants All procedures performed in this study involving human participants were in accordance with the ethical standards of the institutional, regional and national research committee and with the 1964 Declaration of Helsinki and its later amendments or comparable ethical standards.

Informed consent For this type of study, formal consent is not required.

References

1. Forastiere AA, Goepfert H, Maor M et al (2003) Concurrent chemotherapy and radiotherapy for organ preservation in advanced laryngeal cancer. N Engl J Med 349:2091–2098
2. Pfister DG, Spencer S, Brizel DM et al (2014) Head and neck cancers, Version 2.2014. Clinical practice guidelines in oncology. J Natl Compr Cancer Netw 12:1454–1487
3. Wolf G, Hong K, Fisher S, The Department of Veterans Affairs Laryngeal Cancer Study Group et al (1991) Induction chemotherapy plus radiation compared with surgery plus radiation in patients with advanced laryngeal cancer. N Engl J Med 324:1685–1690
4. Weber RS, Berkey BA, Forastiere AA et al (2003) Outcome of salvage total laryngectomy following organ preservation therapy: the Radiation Therapy, Oncology Group trial 91-11. Arch Otolaryngol Head Neck Surg 129:44–49
5. Sassler AM, Esclamado RM, Wolf GT (1995) Surgery after organ preservation therapy: analysis of wound complications. Arch Otolaryngol Head Neck Surg 121:162–165
6. Fung K, Teknos TN, Vandenberg CD et al (2007) Prevention of wound complications following salvage laryngectomy using free vascularized tissue. Head Neck 29:425–430
7. Patel U, Moore B, Wax M et al (2013) Impact of pharyngeal closure technique on fistula after salvage larynectomy. JAMA Otolaryngol Head Neck Surg 139:1156–1162
8. Khan N, Medina J, Sanclement JA, Krempl GA (2014) Fistula rates after salvage laryngectomy: comparing pectoralis myofascial and myocutaneous flaps. Laryngoscope 124:1615–1617
9. Avey CME, Gandhi N, Peel D, Neal CP (2014) Indications and outcomes for 100 patients managed with a pectoralis major flap within a UK maxillofacial unit. Int J Oral Maxillofac Surg 43:546–554
10. Paydarfar JA, Birkmeyer NJ (2006) Complications in head and neck surgery: a meta-analysis of postlaryngectomy pharyngocutaneous fistula. Arch Otolaryngol Head Neck Surg 132:67–72
11. Paleri V et al (2014) Vascularized tissue to reduce fistula following salvage total laryngectomy: a systematic review. Laryngoscope 124:1848–1853
12. Gilbert MR, Sturm JJ, Gooding WE, Johnson JT, Kim S (2014) Pectoralis major myofascial onlay and myocutaneous flaps and pharyngocutaneous fistula in salvage laryngectomy. Laryngoscope 124:2680–2686
13. Myers E (1972) The management of pharyngocutaneous fistula. Arch Otolaryngol 95:10–17
14. Kruse A, Luebbers H, Obwegeser J, Bredell M, Gratz K (2011) Evaluation of the pectoralis major flap for reconstructive head and neck surgery. Head Neck Oncol 3:12
15. Sundaram K, Wasserman J (2009) Prevention of unplanned pharyngocutaneous fistula in salvage laryngectomy. Otolaryngol Head Neck Surg 141:645–647
16. Calli C, Pinar E, Oncel S (2011) Pharyngocutaneous fistula after total laryngectomy: less common with mechanical stapler closure. Ann Otol Rhinol Laryngol 120:339–344
17. Gil Z, Gupta A, Kummer B et al (2009) The role of pectoralis major muscle flap in salvage total laryngectomy. Arch Otolaryngol Head Neck Surg 135:1019–1023
18. McLean J, Nicholas C, Duggal P et al (2012) Surgical management of pharyngocutaneous fistula after total laryngectomy. Ann Plast Surg 68:442–445
19. Oosthuizen J, Leonard D, Kinsella J (2012) The role of pectoralis major myofascial flap in salvage laryngectomy: a single surgeon experience. Acta Otolaryngol 132:1002–1005
20. Righini C, Lequeux T, Cuisnier O, Morel N, Reyt E (2005) The pectoralis myofascial flap in pharyngolaryngeal surgery after radiotherapy. Eur Arch Otorhinolaryngol 262:357–361
21. Basheeth N, O'Leary G, Sheahan P (2014) Pharyngocutaneous fistula after salvage laryngectomy: impact of interval between radiotherapy and surgery, and performance of bilateral neck dissection. Head Neck 36:580–584
22. Patel U, Keni S (2009) Pectoralis myofascial flap during salvage laryngectomy prevents pharyngocutaneous fistula. Otolaryngol Head Neck Surg 141:190–195
23. Aarts M, Rovers M, Grau C, Grolman W, van der Heijden G (2011) Salvage laryngectomy after primary radiotherapy: what are prognostic factors for the development of pharyngocutaneous fistulae? Otolaryngol Head Neck Surg 144:5–9