

Poster No.	PS-14/01
Tipo	EPOSTER SCIENTIFICO
Sezione	ETICA E RADIOL. FORENSE
Autori	LOMBARDO PAOLO - ESTERO (EE) , ZECH WOLF-DIETER , JACKOWSKI CHRISTIAN , SCHWENDENER NICOLE , BRENCICOVA EVA , SCHUSTER FREDERICK

Scopo:

In their daily forensic casework, the authors experienced discrepancies of tracheobronchial content findings between post-mortem computed tomography (PMCT) and autopsy (Figure 1) to an extent previously unnoticed in the literature. The goal of this study was to evaluate such discrepancies in routine forensic cases.

Materiali e metodi:

A total of 327 cases that underwent PMCT prior to routine forensic autopsy were retrospectively evaluated for tracheal and bronchial contents according to PMCT and autopsy findings. Hounsfield unit (HU) values of tracheobronchial contents, causes of death and presence of pulmonary edema were assessed in mismatching and matching cases.

Risultati:

Comparing contents in PMCT and autopsy, in each of the separately evaluated compartments of the respiratory tract sensitivities and negative predictive values were 100 % whereas specificities and positive predictive values were low indicating high discrepancy rates (Table 1). The majority of tracheobronchial contents were viscous stomach contents in matching cases and low radiodensity materials (i.e., HU<30) in mismatching cases. The majority of causes of death were cardiac related in the matching cases and skull / brain trauma in the mismatching cases. In mismatching cases frequency of pulmonary edema was significantly higher than in matching cases.

Conclusioni:

It can be concluded that discrepancies in tracheobronchial contents observed between PMCT and routine forensic autopsy occur in a considerable number of cases. Discrepancies may be explained by the runoff of contents via nose and mouth during external examination (Figure 2A) and the flow back of tracheal and main bronchial contents into the lungs caused by upright movement of the respiratory tract at autopsy (Figure 2B).

Informazioni Personali:

Wolf-Dieter Zech^{1,3}, Christian Jackowski¹, Nicole Schwendener¹, Eva Brencicova¹, Frederick Schuster^{1,2}, Paolo Lombardo^{1,2}

1 Institute of Forensic Medicine Bern, University of Bern, Switzerland

2 Department of Diagnostic, Interventional and Pediatric Radiology, Inselspital, University of Bern, Switzerland

3 Center for Medical Image Science and Visualization (CMIV), University of Linköping, Sweden

Article published online - 23 September 2015 - Int J Legal Med - DOI 10.1007/s00414-015-1264-5

First Prize winner Poster - 5th Congress of the International Society of Forensic Radiology and Imaging (ISFRI) Amsterdam May 12th- 14th2016.

Note Bibliografiche:**Immagini:**

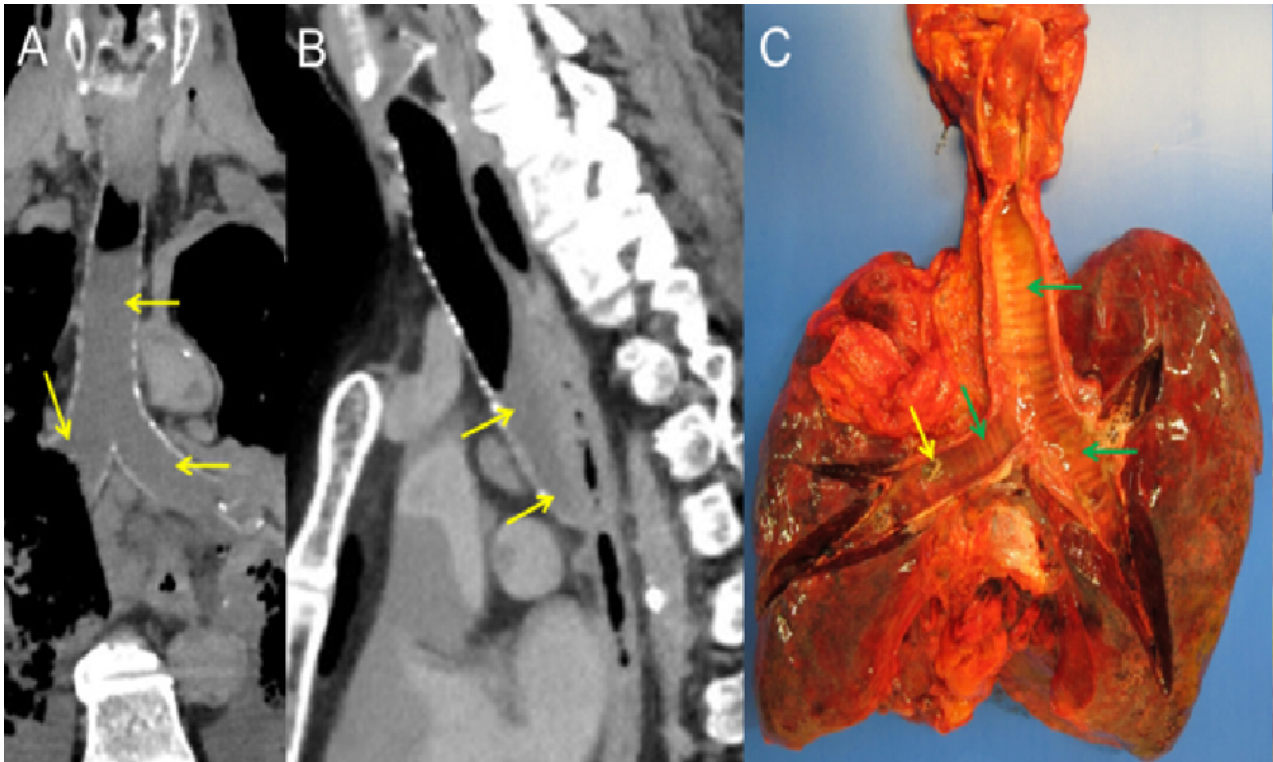


Figure 1: Example of mismatching case of contents at the tracheal and main bronchial level in PMCT compared to autopsy. Note that while there are visible contents (yellow arrows) in the trachea and main bronchi in the coronary and sagittal planes in PMCT images (A and B), there are no contents (green arrows) in the trachea and main bronchi at autopsy of the partially dissected respiratory tract (C). Fluid content is visible in the left superior lobar bronchus (yellow arrow in C).

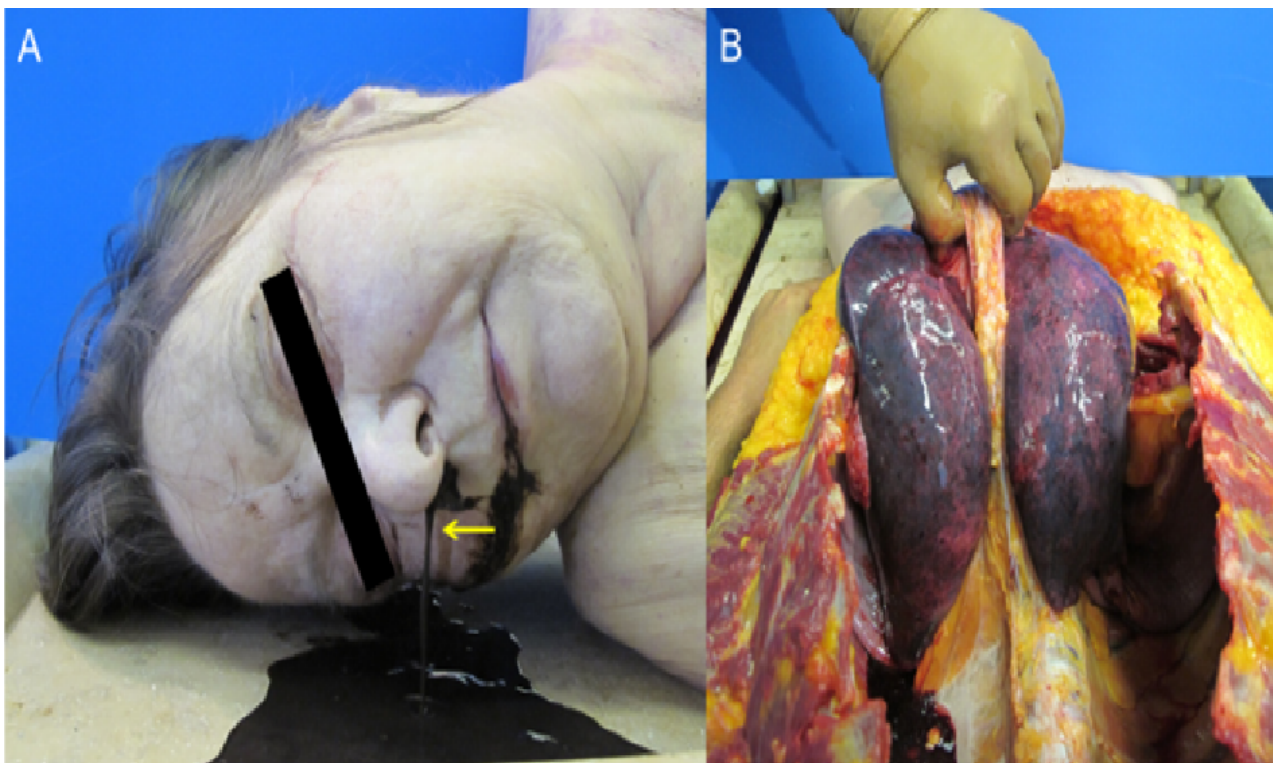


Figure 2: Possible explanations for the mismatches of tracheobronchial contents between PMCT and autopsy may be the loss of contents during movement of the corpse at external examination (yellow arrow, A) and the backflow of low-viscosity material into the lungs at removal of the respiratory tract from the thoracic cavity, which normally includes uplifting the lungs along with the trachea (B).

	TP (match)	FP (no match)	TN (match, no contents)	FN (no match, contents at autopsy only)	Sensitivity as %	Specificity as %	PPV as %	NPV as %
Trachea PMCT (n=152)	58	94	175	0	100	65	38	100
Main Bronchi PMCT (n=185)	74	111	142	0	100	56	40	100
Peripheral Bronchi PMCT (n=204)	141	63	123	0	100	48	59	100

Table 1: Tracheobronchial contents in PMCT compared to autopsy. Evaluation was performed separately for trachea, main bronchi and peripheral bronchi. Autopsy was considered to be gold standard for existence or non existence of tracheobronchial contents. Note the considerable numbers of false positives (FP: no contents at autopsy but in PMCT) and low positive predictive value (PPV) in all investigated compartments of the respiratory tract indicating high discrepancy rates between PMCT and autopsy. TP = true positive; TN = true negative; FN = false negative; NPV = negative predictive value