

Contents lists available at [ScienceDirect](#)

International Journal of Surgery Case Reports

journal homepage: www.casereports.com

Conservative treatment of hepatic portal venous gas consecutive to a complicated diverticulitis: A case report and literature review



Alexandre Moser^{a,*}, Anita Stauffer^a, André Wyss^b, Claudio Schneider^c, Manfred Essig^a, Alexander Radke^d

^a Department of Internal Medicine, Hospital of Zweisimmen, Switzerland

^b Department of Radiology, Hospital of Thun, Switzerland

^c University Clinic for General Internal Medicine, University Hospital of Bern, Switzerland

^d Department of Surgery, Hospital of Zweisimmen, Switzerland

ARTICLE INFO

Article history:

Received 25 March 2016

Received in revised form 26 April 2016

Accepted 26 April 2016

Available online 30 April 2016

Keywords:

Pneumoportogram

Hepatic portal venous gas (HPVG)

Sigmoid diverticulitis

Case report

ABSTRACT

INTRODUCTION AND PRESENTATION OF CASE: Eight days after being diagnosed with multiple small strokes a 71 year old male patient is readmitted with suspicion of a petit mal seizure also complained of diarrhoea and abdominal pain. The patient was stable, not febrile and neurologically intact with a slight tenderness in the left lower quadrant. An ultrasound revealed presence of air in the hepatic portal venous system and a suspicion for sigmoid diverticulitis. A CT-scan confirmed both diagnoses. We proceeded with a conservative regimen under close observation. The clinical course and laboratory results were unremarkable.

DISCUSSION: The review of the literature (PubMed database) triggered 685 items with only one clinical trial establishing a scoring system to detect adult individuals, which need operation.

CONCLUSION: A pneumoportogram (hepatic portal venous gas, HPVG) is a very rare and usually associated with bowel ischemia and from poor prognosis. The last decades saw the emergence of numerous other aetiologies (also benign) with a shift of paradigm from systematic emergency laparotomies to individual patient selection.

© 2016 The Authors. Published by Elsevier Ltd on behalf of IJS Publishing Group Ltd. This is an open access article under the CC BY-NC-ND license (<http://creativecommons.org/licenses/by-nc-nd/4.0/>).

1. Introduction and case presentation

Eight days after being diagnosed with multiple small strokes a 71 year old male patient is readmitted with suspicion of a petit mal seizure. He also complained of diarrhoea and abdominal pain. The patient was hemodynamically stable (HR 66/min, BP 114/71 mmHg), not febrile (36.2 °C), the neurological examination revealed no further symptoms compared with the examination eight days ago. The abdominal examination showed slight tenderness with no guarding in the left lower quadrant.

A follow-up cranial CT-scan showed no further ischemia or bleeding.

The laboratory data presented a normal WBC count of 5.3G/l, a CRP level of 93.5 mg/l with elevated GGT 80 U/l and a normal blood urea nitrogen (BUN).

EKG outcome was a first grade block (PQ 208 ms) and the chest X-ray was unremarkable.

* Corresponding author at: Department of Internal Medicine, Hospital of Zweisimmen, Karl-Haueterstrasse 21, CH-3770 Zweisimmen, Switzerland.
E-mail address: alexandre.moser@ssynn.net (A. Moser).

An ultrasound of the abdomen revealed the presence of massive air in the hepatic portal venous system ([Image 1](#)) and a suspicion for sigmoid diverticulitis. These findings were confirmed by a subsequent CT scan ([Image 2 and 3](#)). The sigmoid diverticulitis was staged as a covered perforation without abscess formation (IIb according to Hansen and Stock).

We treated the patient with iv Piperacillin/Tazobactam (3 × 4.5 g/d) and fluid intake. To rule out a seizure an EEG was performed and showed no epileptical activity but without certain exclusion of a petit mal event.

Due to findings consistent with complicated but mild diverticulitis (no septic findings, no signs of a gangrenous process within the sigmoid colon) and the patients comorbidities we proceeded with the conservative regimen under close observation. After 48 h the patient was allowed on solid food with consecutive return to a light diet. The clinical course and laboratory results were unremarkable with a decline of the CRP and 8 days after admission the patient was discharged. The antibiotic therapy was changed to Amoxicillin and Clavulanic acid po for a total of 21 days since the onset of antibiotics. To rule out a secondary liver abscess or a portal venous thrombosis a CT scan was planned after 2 months or immediately in worsening conditions.

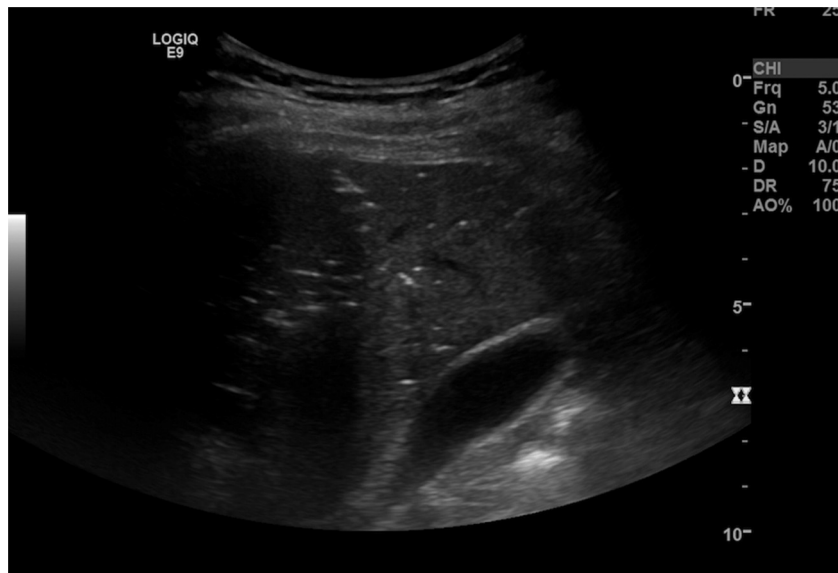


Image 1. sonography with suspicion of HPVG.

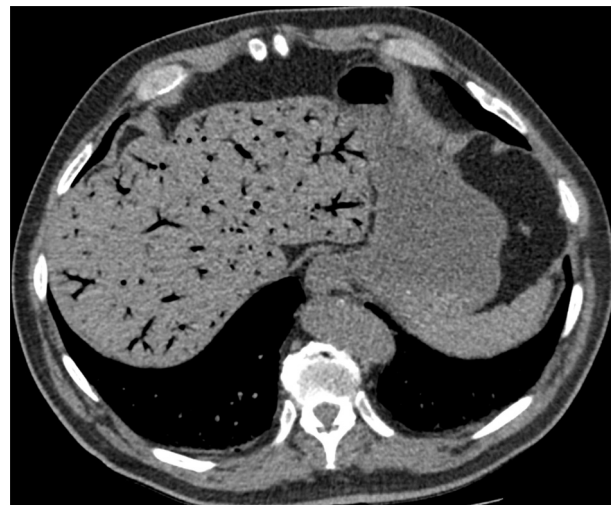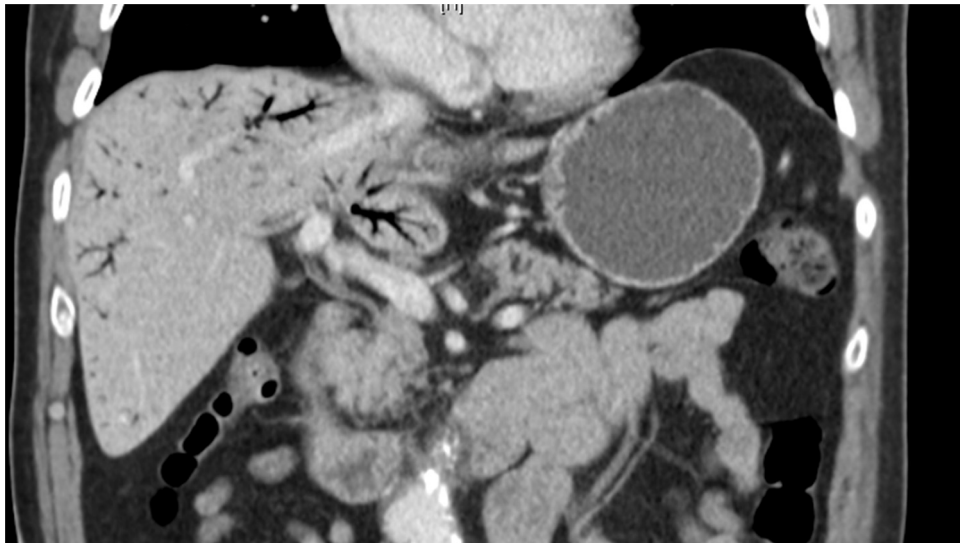


Image 2 and 3. Pneumoportogram in the CT-scan.

To rule out malignancy a colonoscopy was performed 6 weeks after discharge. The subsequent CT-scan revealed no signs of hepatic abscess formation and a resolved diverticulitis.

2. Review of the literature

The utilized search string was ‘portal venous gas’ and was exerted on PubMed database. In total it triggered 685 items. The results were limited to adult patients and clinical settings.

Besides retrospective review of HPVG or pneumatosis intestinalis or both to establish clinical algorithms based on clinical, laboratory and radiographic findings [1] there was only one multicenter clinical trial to detect risk factors for colic ischemia or necrosis if CT findings of pneumatosis intestinalis and portal venous gas were given [2]. Further 35 case reports and reviews were available.

3. Discussion

A pneumoportogram is described as the presence of air in the hepatic portal venous system (hepatic portal venous gas, HPVG), typically at the periphery of the liver in contrast to an aerobilia [3] and was first described in 1955 by Wolfe and Evans [4]. HPVG is a rare condition and can be associated with an overall mortality rate up to 40% [5] coming down from 75% as observed in a literature survey in 1978 [6]. Aetiologies are in most cases an ischemic bowel necrosis (43%), peritonitis or abscess (11%) as may be present in the case of a diverticulitis [7–10]. The mortality risk is highest, if HPVG is present in combination with necrotic bowel (>50%) [6].

Though the presence of HPVG was formerly considered a mandatory indication for urgent exploratory laparotomy since the late 70s and early 80s cases of HPVG without ischemic necrosis were reported and the question arose, if it is still an indication for surgery or if there may be benign courses [2]. The increase of non-fatal and nonsurgical reported conditions associated with HPVG is on the one hand due to the increasing number of CT-scans as diagnostic tool and not any more on left lateral decubitus plain films [4,11–13]. On the other hand sensitivity of gas detection in CT is much higher as with conventional X-ray [14,15]. Thus maybe contributing as a bias to the decreasing mortality rate in contrast to a more restricted indication for surgery as outlined underneath.

Obviously the question of surgery indication would be complicated and probably impossible to be answered by randomized controlled trials. In absence of a larger cohort study parsing out implications of HPVG in series of laparotomies for abdominal catastrophe, remain only case reports and case series to make a therapeutic decision.

According to the fact that the presence of HPVG on CT could be associated with a range of non-surgical pathologies (Table 1), it's sole presence does not mandate surgical exploration and has no proven predictive power. Surgical intervention in all HPVG cases would result in approximately 30% non-therapeutic laparotomies [2,6,10].

A current evidence based indication for surgery is bowel ischemia/necrosis with or without mechanical obstruction. The significant risk factors delineated in a consecutive gathering of 88 cases by Wayne et al. to distinguish the patient towards surgery and develop an algorithm are pain, elevated lactate, presence of small bowel PI and calculated vascular disease score. This algorithm is based only on 70 cases of pneumatosis intestinalis and/or HPVG still with a sensitivity of 89%. Once distinguished into a subgroup the specificity and positive predictive value is 100% [2]. The Algorithm was tested only on a limited number of 14 cases and has to be proven on a larger population.

Table 1
summarizes various reasons for HPVG.

Reason	Author
Diverticulitis	Haak et al. [7] Sellner et al. (2007) [19]
Ileus	Quirke (1995) [20]
Chemotherapy/Enterocolitis	Tan et al. (2015) [21] Kanagushi et al. (2014) [22] Onyeabor et al. (2015) [23] Shinagawa et al. (2015) [24] Mirmanesh et al. (2013) [25]
Tube-ovarian abscess	Kirsch et al. (1990) [26]
Colonoscopy	Mittal et al. (2015) [27]
Viral gastroenteritis	Choi et al. (2014) [28]
Crohn's disease	Vauthey et al. (1992) [29]
Incarcerated diaphragmatic hernia	Slawinski et al. (2015) [30]
Gastroduodenal ulcer	Patel et al. (2015) [31]
Blunt abdominal trauma	Papafraqkou et al.(2012) [32]
Bickerstaff's encephalitis	Park et al. (2007) [33]
Cocaine-induced intestinal ischemia	Hong et al. (1997) [34]
Hydrogen peroxide ingestion	
Acute pancreatitis	
Endoscopic retrograde cholangiopancreatography	
Seizure	Chen et al. (1997) [35]
Cystic fibrosis	Mallens et al. (1995) [36]

Keeping in mind that CT-scans alone are not always satisfactory in revealing bowel ischemia [1,16–18]. Additional factors like older age, peritoneal signs and high BUN were found to be significantly associated with ischemia or necrosis [1].

If ischemia or necrosis is diagnosed the presence of HPVG has a predictive value since an increasing mortality could be observed [6].

According to the algorithm developed by Wayne et al. [2] our patient had a benign HPVG (score <4), supporting our conservative treatment approach with a benign course.

4. Conclusion

HPVG is a very rare condition from poor prognosis when associated with bowel ischemia. The last decades saw the emergence of numerous other aetiologies including benign courses and a shift of paradigm from systematic emergency laparotomies to individual patient selection. Revealing bowel necrosis/ischemia is the most important step towards patient selection for surgery. Developed algorithms can aid the decision making as in our case but unfortunately are based on small populations and present a wide variety of variables. Establishing clinical guidelines by using a register would be desirable.

Conflict of interest

We have no conflict of interest and no source of funding to declare.

Funding

No sources of funding to declare.

Ethical approval

According to the Canton Bern (Switzerland) regulation, this manuscript doesn't require ethical approval.

Consent

Written informed consent was obtained from the patient for publication of this case report and accompanying images. A copy of the written consent is available for review by the Editor-in-Chief of this journal on request (please ask: alexandre.moser@ssvnn.net)

Author contribution

All authors have made significant contribution to the submitted manuscript. Alexandre Moser and Alexander Radke wrote the manuscript and did the literature review. André Wyss made significantly corrections to the script and was responsible for the radiologist point of view. Claudio Schneider and Anita Stauffer realized the US of the patient and participated at the literature review. Manfred ESSIG shared his expert opinion about this case.

Guarantor

Alexandre MOSER and Alexander RADKE.

References

- [1] M. Bani Hani, F. Kamangar, S. Goldberg, J. Greenspon, P. Shah, C. Volpe, et al., Pneumatosis and portal venous gas: do CT findings reassure? *J. Surg. Res.* 185 (December (2)) (2013) 581–586.
- [2] E. Wayne, M. Ough, A. Wu, J. Liao, K.J. Andresen, D. Kuehn, et al., Management algorithm for pneumatosis intestinalis and portal venous gas: treatment and outcome of 88 consecutive cases, *J. Gastrointest. Surg.* 14 (March (3)) (2010) 437–448.
- [3] M. Keller, C. Epp, C. Meyenberger, A. Lauber, M.C. Sulz, Wenn gas in die leber kommt, *Schweiz. Med. Forum* 14 (12) (2014) 262.
- [4] J.N. Wolfe, W.A. Evans, Gas in the portal veins of the liver in infants; a roentgenographic demonstration with postmortem anatomical correlation, *Am. J. Roentgenol. Radium Ther. Nucl. Med.* 74 (September (3)) (1955) 486–488.
- [5] H. Kinoshita, M. Shinozaki, H. Tanimura, Y. Umemoto, S. Sakaguchi, K. Takifuji, et al., Clinical features and management of hepatic portal venous gas: four case reports and cumulative review of the literature, *Arch. Surg.* 136 (December (12)) (1960) 1410–1414.
- [6] A.L. Nelson, T.M. Millington, D. Sahani, R.T. Chung, C. Bauer, M. Hertl, et al., Hepatic portal venous gas: the ABCs of management, *Arch. Surg.* 144 (June (6)) (1960) 575–581 (discussion 581).
- [7] H.R. Haak, M.F. Kooymans-Coutinho, M.E. von Teeffelen, S. Adhin, T.H. Falke, Portal venous gas in a patient with diverticulitis, *Hepatogastroenterology* 37 (5) (1990) 528–529.
- [8] L.W. Traverso, Is hepatic portal venous gas an indication for exploratory laparotomy? *Arch Surg Chic Ill, Arch Surg Chic Ill* 116 (July (7)) (1981) 936–938.
- [9] K. McElvanna, A. Campbell, T. Diamond, Hepatic portal venous gas—three non-fatal cases and review of the literature, *Ulster Med. J.* 81 (May (2)) (2012) 74–78.
- [10] D.A. Iannitti, S.C. Gregg, W.W. Mayo-Smith, R.J. Tomolonis, W.G. Cioffi, V.E. Pricolo, Portal venous gas detected by computed tomography: is surgery imperative? *Dig. Surg.* 20 (4) (2003) 306–315.
- [11] P.R. Liebman, M.T. Patten, J. Manny, J.R. Benfield, H.B. Hechtman, Hepatic-portal venous gas in adults: etiology, pathophysiology and clinical significance, *Ann. Surg.* 187 (March (3)) (1978) 281–287.
- [12] T.V. Berne, H.I. Meyers, A.J. Donovan, Gas in the portal vein of adults with necrotizing enteropathy, *Am. J. Surg.* 120 (August (2)) (1970) 203–209.
- [13] N. Susman, H.R. Senturia, Gas embolization of the portal venous system, *Am. J. Roentgenol. Radium Ther. Nucl. Med.* 83 (May) (1960) 847–850.
- [14] J.P. Earls, A.H. Dachman, E. Colon, M.G. Garrett, M. Molloy, Prevalence and duration of postoperative pneumoperitoneum: sensitivity of CT vs left lateral decubitus radiography, *AJR Am. J. Roentgenol.* 161 (4) (1993) 781–785.
- [15] C.G. Schulze, U. Blum, K. Haag, Hepatic portal venous gas. Imaging modalities and clinical significance, *Acta Radiol Stockh Swed* 36 (July (4)) (1987) 377–380.
- [16] P.A. Shah, S.C. Cunningham, T.A. Morgan, B.D. Daly, Hepatic gas: widening spectrum of causes detected at CT and US in the interventional era, *Radiogr. Rev. Publ. Radiol. Soc. N. Am. Inc.* 31 (5) (2011) 1403–1413.
- [17] S.-K. Hou, C.-H. Chern, C.-K. How, J.-D. Chen, L.-M. Wang, C.-H. Lee, Hepatic portal venous gas: clinical significance of computed tomography findings, *Am. J. Emerg. Med.* 22 (May (3)) (2004) 214–218.
- [18] C. Sebastià, S. Quiroga, E. Espin, R. Boyé, A. Alvarez-Castells, M. Armengol, Portomesenteric vein gas: pathologic mechanisms, CT findings, and prognosis, *Radiogr. Rev. Publ. Radiol. Soc. N. Am. Inc.* 20 (October (5)) (2000) (1213–1224–1226).
- [19] F. Sellner, B. Sobhian, M. Baur, S. Sellner, B. Horvath, M. Mostegel, et al., Intermittent hepatic portal vein gas complicating diverticulitis—a case report and literature review, *Int. J. Colorectal. Dis.* 22 (November (11)) (2007) 1395–1399.
- [20] T.E. Quirke, Hepatic-portal venous gas associated with ileus, *Am. Surg.* 61 (December (12)) (1995) 1084–1086.
- [21] E.W. Tan, M.D. Smith, A rare occurrence of hepatic portal venous gas in a patient with chemotherapy-induced enterocolitis: the rise of benign aetiologies, *J. Surg. Case Rep.* 2015 (2015) 9.
- [22] Y. Kanagushi, T. Fujita, J. Hanaoka, H. Hayashi, A case of hepatic portal venous gas in a patient treated with pemetrexed and carboplatin for lung cancer, *Chemotherapy* 60 (2) (2014) 88–90.
- [23] S. Onyeabor, F. Cason, Chronic tubo-ovarian abscess complicated by hepatic portal venous gas, *J. Surg. Case Rep.* 2015 (2015) 9.
- [24] T. Shinagawa, K. Hata, T. Watanabe, Hepatic portal venous gas after colonoscopy for ulcerative colitis: a case report, *J. Crohns. Colitis.* (2015).
- [25] M. Mirmanesh, Q.-S. Nguyen, A. Markelov, A case of hepatic portal venous gas due to viral gastroenteritis, *Hepatic Med.* 5 (2013) 63–65.
- [26] M. Kirsch, J. Bozdech, D.A. Gardner, Hepatic portal venous gas: an unusual presentation of Crohn's disease, *Am. J. Gastroenterol.* 85 (November (11)) (1990) 1521–1523.
- [27] K. Mittal, K. Anandpara, A.K. Dey, P. Kedar, P. Hira, S. Kale, Left aberrant gastric vein causing isolated left hepatic portal venous gas secondary to an incarcerated diaphragmatic hernia, *Pol. J. Radiol. Pol. Med. Soc. Radiol.* 80 (2015) 364–367.
- [28] Y.J. Choi, W. Moon, S.J. Park, M.I. Park, S.E. Kim, Hepatic portal venous gas associated with hemorrhagic gastroduodenal ulcers, *Turk. J. Gastroenterol.* 25 (Suppl. 1) (2014) 237–238.
- [29] J. Vauthey, C. Matthews, Hepatic portal venous gas identified by computed tomography in a patient with blunt abdominal trauma: a case report, *J. Trauma.* 32 (1) (1992) 120.
- [30] C. Slawinski, E. Parkin, P. Casey, S. Pettit, Hepatic portal venous gas complicating Bickerstaff's encephalitis with Guillain Barré overlap, *BMJ Case Rep.* 2015 (2015).
- [31] H. Patel, H. Shaaban, N. Shah, W. Baddoura, A rare case report of spontaneous resolution of hepatic portal venous gas associated with cocaine-induced intestinal ischemia, *Ann. Med. Health Sci. Res.* 5 (2) (2015) 136–138.
- [32] S. Papafragkou, A. Gasparyan, R. Batista, P. Scott, Treatment of portal venous gas embolism with hyperbaric oxygen after accidental ingestion of hydrogen peroxide: a case report and review of the literature, *J. Emerg. Med.* 43 (1) (2012) e21–e23.
- [33] H.C. Park, W.S. Lee, S.Y. Joo, S.Y. Park, Y.E. Joo, H.S. Kim, et al., Hepatic portal venous gas associated with acute pancreatitis: reports of two cases and review of literature, *Korean J. Gastroenterol.* 50 (2) (2007) 131–135.
- [34] J.J. Hong, D. Gadaleta, P. Rossi, J. Esquivel, J.M. Davis, Portal vein gas, a changing clinical entity. Report of 7 patients and review of the literature, *Arch. Surg.* 132 (10) (1997) 1071–1075.
- [35] K.W. Chen, J.S. Shin, C.H. Chi, L. Cheng, Seizure: a rare and transient cause of portal venous gas, *Am. J. Gastroenterol.* 92 (2) (1997) 351–352.
- [36] W.M. Mallens, R. Schepers-Bok, J.J. Nicolai, F.A. Jacobs, H.G. Heyerman, Portal and systemic venous gas in a patient with cystic fibrosis: CT findings, *AJR Am. J. Roentgenol.* 165 (2) (1995) 338–339.

Open Access

This article is published Open Access at sciendo.com. It is distributed under the [IJSCR Supplemental terms and conditions](#), which permits unrestricted non commercial use, distribution, and reproduction in any medium, provided the original authors and source are credited.