

Optimal Lateral Row Anchor Positioning in Posterior-Superior Transosseous Equivalent Rotator Cuff Repair

A Micro-Computed Tomography Study

Matthias A. Zumstein,^{*†‡} MD, Sumit Raniga,[†] MBChB, FRACS, Agatha Labrinidis,^{‡§||} PhD, Kevin Eng,^{‡§||} FRACS, Gregory I. Bain,^{‡§||} MBBS, FRACS, FA(Ortho)A, PhD, and Beat K. Moor,[†] MD

Investigation performed at Department of Orthopedics and Traumatology, University of Adelaide, South Australia, Australia

Background: The optimal placement of suture anchors in transosseous-equivalent (TOE) double-row rotator cuff repair remains controversial.

Purpose: A 3-dimensional (3D) high-resolution micro-computed tomography (micro-CT) histomorphometric analysis of cadaveric proximal humeral greater tuberosities (GTs) was performed to guide optimal positioning of lateral row anchors in posterior-superior (infraspinus and supraspinatus) TOE rotator cuff repair.

Study Design: Descriptive laboratory study.

Methods: Thirteen fresh-frozen human cadaveric proximal humeri underwent micro-CT analysis. The histomorphometric parameters analyzed in the standardized volumes of interest included cortical thickness, bone volume, and trabecular properties.

Results: Analysis of the cortical thickness of the lateral rows demonstrated that the entire inferior-most lateral row, 15 to 21 mm from the summit of the GT, had the thickest cortical bone (mean, 0.79 mm; $P = .0001$), with the anterior-most part of the GT, 15 to 21 mm below its summit, having the greatest cortical thickness of 1.02 mm ($P = .008$). There was a significantly greater bone volume (BV; posterior, $74.5 \pm 27.4 \text{ mm}^3$; middle, $55.8 \pm 24.9 \text{ mm}^3$; anterior, $56.9 \pm 20.7 \text{ mm}^3$; $P = .001$) and BV as a percentage of total tissue volume (BV/TV; posterior, $7.3\% \pm 2.7\%$, middle, $5.5\% \pm 2.4\%$; anterior, $5.6\% \pm 2.0\%$; $P = .001$) in the posterior third of the GT than in intermediate or anterior thirds. In terms of both BV and BV/TV, the juxta-articular medial row had the greatest value (BV, $87.3 \pm 25.1 \text{ mm}^3$; BV/TV, $8.6\% \pm 2.5\%$; $P = .0001$ for both) followed by the inferior-most lateral row 15 to 21 mm from the summit of the GT (BV, $62.0 \pm 22.7 \text{ mm}^3$; BV/TV, $6.1\% \pm 2.2\%$; $P = .0001$ for both). The juxta-articular medial row had the greatest value for both trabecular number ($0.3 \pm 0.06 \text{ mm}^{-1}$; $P = .0001$) and thickness ($0.3 \pm 0.08 \text{ }\mu\text{m}$; $P = .0001$) with the lowest degree of trabecular separation ($1.3 \pm 0.4 \text{ }\mu\text{m}$; $P = .0001$). The structure model index (SMI) has been shown to strongly correlate with bone strength, and this was greatest at the inferior-most lateral row 15 to 21 mm from the summit of the GT (2.9 ± 0.9 ; $P = .0001$).

Conclusion: The inferior-most lateral row, 15 to 21 mm from the tip of the GT, has good bone stock, the greatest cortical thickness, and the best SMI for lateral row anchor placement. The anterior-most part of the GT 15 to 21 mm below its summit had the greatest cortical thickness of all zones. The posterior third of the GT also has good bone stock parameters, second only to the medial row. The best site for lateral row cortical anchor placement is 15 to 21 mm below the summit of the GT.

Clinical Relevance: Optimal lateral anchor positioning is 15 to 21 mm below the summit of the greater tuberosity in TOE.

Keywords: rotator cuff; shoulder anatomy; surgery; arthroscopy

Arthroscopic transosseous-equivalent (TOE) double-row rotator cuff repair techniques have evolved in the past decade with varying configurations of suture anchor

placement. The mattress tension band technique developed by Boileau et al⁵ positions the anchor much more lateral and distal to the summit of the greater tuberosity (GT), where a higher pullout strength has been demonstrated.²⁹ These repair techniques enhance the biomechanical strength of the repair and increase the surface area of the repaired tendon on the footprint, but their ability to provide

The Orthopaedic Journal of Sports Medicine, 4(11), 2325967116671305
DOI: 10.1177/2325967116671305
© The Author(s) 2016

This open-access article is published and distributed under the Creative Commons Attribution - NonCommercial - No Derivatives License (<http://creativecommons.org/licenses/by-nc-nd/3.0/>), which permits the noncommercial use, distribution, and reproduction of the article in any medium, provided the original author and source are credited. You may not alter, transform, or build upon this article without the permission of the Author(s). For reprints and permission queries, please visit SAGE's Web site at <http://www.sagepub.com/journalsPermissions.nav>.

superior anatomic and functional outcomes remains controversial.

With advances in arthroscopic surgery, the use of suture anchors has become increasingly popular because of the ease and speed of their use and decreased surgical exposure and morbidity.^{2,8,11} Poor fixation of suture anchors due to reduced bone quality of the proximal humerus is a problem in rotator cuff repair.^{1,8,10,12,15,27,28,33} Pullout of suture anchors before tendon healing may result in gap formation between the tendon and the bone, rupture of the rotator cuff repair, and a poor outcome.^{1,12,13,15,33} Recommendations in the literature regarding the optimum region for placement of lateral row suture anchors in rotator cuff repair are controversial.^{7,11,13,29,31}

Surgeons are limited to the region of the GT and the lesser tuberosity when repairing the torn rotator cuff. The site of tendon reattachment is influenced by the size of the rotator cuff tear, the involved rotator cuff tendons, the degree of tendon retraction, and the amount of tendon mobilization achieved as well as the degree of tendon tension during rotator cuff surgery.^{7,11,31} However, within these limitations, the surgeon still has some options regarding suture anchor placement. The literature suggests that juxta-articular bone just medial to the GT is best for medial row anchor fixation.^{2,7,13,17,20} However, other studies have suggested that lateral row suture anchors placed lateral and distal to the summit of the GT have even higher pullout strengths, and they therefore recommend insertion of anchors as far distal from the tip of the GT as possible.^{5,11,29,31} The lateral-distal extent of anchor placement may be limited by the course of the axillary nerve. We hypothesized that greater cortical thickness and better bone microarchitecture may be the reason for this increase in pullout strength.

Micro-computed tomography (micro-CT) is a non-invasive high-resolution imaging modality capable of 2-dimensional (2D) and 3-dimensional (3D) microarchitectural examination of excised bone segments at a level of detection not achievable with conventional CT imaging scanners. Micro-CT has a spatial resolution in the 10 μm range, which is 10 to 100 times better than conventional clinical CT or magnetic resonance imaging (MRI) scanners and can accurately discriminate between trabecular and cortical bone compartments and nonosseous tissues as opposed to conventional clinical CT and MRI imaging.^{22,25,26} Histomorphometric studies have observed differences in the osseous structure of the proximal humerus using quantitative computed tomography (QCT)³² and high-resolution peripheral quantitative computed tomography (HR-pQCT).¹⁷

The aim of this study was to carry out a 3D high-resolution micro-CT histomorphometric analysis of

cadaveric proximal humeral GTs to understand the differences in osseous morphology of various zones that may guide optimal positioning of lateral row anchors in posterior-superior (infraspinatus and supraspinatus) TOE rotator cuff repair.

METHODS

This study was reviewed and supported by the Human Research Ethics Committee at The Queen Elizabeth Hospital, Woodville South, South Australia, Australia. The cadaveric specimens were provided, after completion of body donation consent forms and physical acceptance, as part of The University of Adelaide School of Medical Sciences Body Donation Program. There were no external sources of funding.

Specimens

A total of 13 fresh-frozen human cadaveric proximal humeri from the Ray Last Laboratory, University of Adelaide, were examined. Seven specimens were male and 6 female, with a mean age of 89 years (range, 73-100 years). Six specimens had an intact rotator cuff while 7 had chronic retracted full-thickness tears of the rotator cuff.

Micro-CT Analysis

Each sample was thawed carefully, wrapped in cling wrap, and placed in a desktop high-resolution micro-CT scanner (Skyscan 1076 in vivo micro-CT scanner).²⁵ Scans were performed with a source voltage of 100 kVp, current of 90 mA, and a 1.0-mm-thick aluminum filter for beam hardening reduction, with 34.6-mm pixel size.

Cross-sectional images were reconstructed using a filtered back-projection algorithm (NRecon software, V 1.6.4.7; Skyscan).^{25,26} For each proximal humerus, a total of 1688 2D radiographic images were acquired as TIF files and reconstructed into 8-bit gray-level (bitmap) image files using a cone beam algorithm with a beam hardening setting of 70% and ring artifact reduction of 15. From the reconstructed bitmap datasets, the volume of interest (VOI) was identified.

Setting the VOI for Histomorphometric Analysis

For the evaluation of bone density and the histomorphometric analysis, specific VOIs were defined within the GT. Each volume had a cylindrical shape with a diameter of 7.5 mm and a depth of 15 mm, corresponding to the mean volume of currently used suture anchors.³ To achieve

*Address correspondence to Matthias A. Zumstein, MD, Inselspital, Bern University Hospital, Freiburgstrasse 18, Bern 3010, Switzerland (email: matthias.zumstein@insel.ch).

[†]Department of Orthopaedic Surgery and Traumatology, Inselspital, Bern University Hospital, University of Bern, Bern, Switzerland.

[‡]Department of Orthopedics and Traumatology, University of Adelaide, South Australia, Australia.

[§]Department of Orthopaedics and Trauma, Royal Adelaide Hospital, South Australia, Australia.

^{||}Department of Orthopaedics and Trauma, Modbury Public Hospital, South Australia, Australia.

The authors declared that they have no conflicts of interest in the authorship and publication of this contribution.

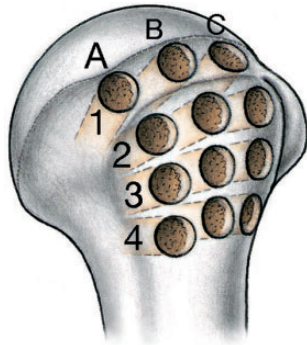


Figure 1. Posterolateral view of the proximal humerus depicting the exact locations of volumes of interest in zonal arrangement. The greater tuberosity is divided into 3 equal zones in the sagittal plane (A, B, C). Four rows were defined in the coronal plane, 1 medial row adjacent to the articular surface (A1, B1, C1) and 3 rows lateral to the summit of the greater tuberosity. Row 2 (A2, B2, C2), 0 to 7 mm below the summit; Row 3 (A3, B3, C3), 8 to 14 mm below; and Row 4 (A4, B4, C4), 15 to 21 mm below.

a maximum comparability to the clinical situation, each volume had been placed at a 45° angle to the GT. This angle had been previously described by Burkhart,⁶ who stated that the anchor’s pullout strength is increased at lower angles. The positions of the VOIs were defined as zones A1 through 4, B1 through 4, and C1 through 4.

The borders of the GT were defined based on anatomical studies by Meier and Meier.¹⁹ It was divided into 3 equal zones in the sagittal plane: (A) posterior, (B) intermediate, and (C) anterior. In the coronal plane, the GT was divided into 4 zones, corresponding to potential anchor sites for TOE rotator cuff repair. Row 1 (A1, B1, C1) was medial to the GT, adjacent to the articular surface, where suture anchors for the medial row are generally placed. Rows 2, 3, and 4 were lateral to the summit of the GT, where lateral anchors are often placed. Row 2 was 0 to 7 mm below the summit, Row 3 was 8 to 14 mm below, and zone 4 was 15 to 21 mm below the summit. For each row (1 to 4), there was a posterior (A), intermediate (B), and anterior (C) volume of interest (ie, A1, B1, and C1). The VOIs are illustrated in Figure 1.

Histomorphometric Analysis

The micro-CT images were segmented using global thresholding, and 3D morphometric parameters were calculated within the cylindrical VOI zones using CT Analyser Software (Skyscan).²⁴ The following histomorphometric properties were analyzed (Table 1):

Cortical thickness

- Cortical thickness was measured in mm at the center of and perpendicular to VOI for zones 2, 3, and 4 (A2, B2, and C2 to A4, B4, and C4)
- The cortical thickness of the juxta-articular medial row was not reported as this area is usually decorticated by many surgeons prior to medial row anchor placement

TABLE 1
Bone Histomorphometric Properties^a

Micro-CT Parameter	Definition
Volumes	
Bone volume (BV), mm ³	Total bone in the volume of interest
Total (tissue) volume (TV), mm ³	Total tissue in the volume of interest
Percentage bone volume (BV/TV), %	Relative volume of calcified tissue in the volume of interest
Trabecular properties	
Trabecular pattern factor (Tb.Pf), mm ⁻¹	3D index that describes reciprocal the trabecular lattices and is a marker of trabecular connectivity. Loss of connectivity has a substantial impact on structural integrity and results in elevated fracture risk. ^{9,14,23}
Structure model index (SMI)	The relative prevalence of rods and plates of trabecular bone in a 3D structure. Strongly correlates with bone strength ²¹
Trabecular thickness (Tb.Th), μm	Thickness of trabeculae in the volume of interest
Trabecular number (Tb.N), mm ⁻¹	Number of trabeculae in the volume of interest
Trabecular separation (Tb.Sp), μm	Separation of trabeculae in the volume of interest

^a3D, 3-dimensional; micro-CT, micro-computed tomography.

Bone volume

- Bone volume (BV; mm³)
- Total (tissue) volume (TV; mm³)
- Bone volume to total (tissue) volume ratio (BV/TV; %), the relative volume of calcified tissue in the selected bone volume of interest

Trabecular properties

- Trabecular connectivity (trabecular pattern factor = Tb.Pf; mm⁻¹), the 3D index that describes the reciprocal trabecular lattices
- Structure model index (SMI), the relative prevalence of rods and plates of trabecular bone in a 3D structure
- Number of trabeculae (Tb.N; mm⁻¹)
- Trabeculae thickness (Tb.Th; μm)
- Trabecular separation (Tb.Sp; μm)

BV/TV was determined by simple voxel counting of the bone and background phases. The mean trabecular dimensions (Tb.Th, Tb.N, and Tb.Sp) were calculated directly using a model-independent sphere-filling technique. The morphometric parameter, SMI, was calculated from the surface convexity of the triangulated bone surface and allowed for quantification of plate- and rod-like geometries of trabecular bone.¹⁶ SMI has been shown to strongly correlate with bone strength.²¹ The stability of trabecular bone depends not only on the amount of bone tissue but also on the 3D orientation and connectedness of trabeculae. The trabecular pattern factor (Tb.Pf) is a 3D index that describes the reciprocal trabecular lattices and is a marker of trabecular connectivity. The loss of

connectivity has a substantial impact on structural integrity and results in elevated fracture risk.^{9,14,23}

Statistical Analysis

Statistical analysis was performed using SPSS statistical software (IBM Corp). Descriptive analysis of the data was performed to report means and standard deviations as well as the range. Differences between the areas were made using univariate analysis with Bonferroni-Dunn correction for the subgroups. Differences between torn and intact tendons were made using *t* test analysis. Statistical significance was defined as $P < .05$.

RESULTS

Specimens

Of the 13 fresh-frozen human cadaveric proximal humeri specimens, 7 were male and 5 female, with a mean age of 89 years (range, 73-100 years). Six specimens had an intact rotator cuff, while 7 had chronic retracted full-thickness tears of the rotator cuff. The rotator cuff was divided into 6 sectors (A, B, C, D, E, or F), and the tears were classified per the Thomazeau et al³⁰ classification modified by Boileau et al.⁴ There were no differences regarding sex or side between the torn and intact groups (Table 2).

Cortical Thickness of Lateral Rows

Analysis of the cortical thickness of the lateral rows demonstrated that the entire inferior-most lateral row, 15 to 21 mm from the summit of the GT (zones 4A, 4B, and 4C), had the thickest cortical bone (mean, 0.79 mm). In all 3 zones (A-C), there was a statistically significant difference between the heights ($P = .001$). In detailed analysis between Rows 3 ($P = .008$) and 4 ($P = .008$) in the anterior and posterior thirds. Zone 4C, which is the anterior-most part of the GT and 15 to 21 mm below its summit, had the greatest cortical thickness at 1.02 mm (Table 3).

Anterior-Posterior Comparison of Bone Histomorphometric Parameters

There was a significantly greater BV and BV/TV in zone A (A1-A4) of the GT than in zones B or C. There was no statistically significant difference in the trabecular properties between the posterior, intermediate, and anterior zones (Table 4).

Superior-Inferior Comparison of Bone Histomorphometric Parameters

There were statistically significant differences in all histomorphometric parameters of bone volume and trabecular properties between the 4 rows from superior to inferior on the GT (Table 5).

TABLE 2
Proximal Humeral Cadaveric Specimen Analysis^a

	Intact Group (n = 6)	Torn Group (n = 7)	P Value
Age, y, n (range)	89 (87-93)	89 (82-100)	ns
Sex, female/male, n	2/4	5/2	ns
Side, left/right, n	3/3	2/4	ns
Tear pattern ^b		3 × C, D, E	
		3 × B, C, D, E	
		1 × B, C, D, E, F	

^ans, not significant.

^bTear pattern according to Thomazeau et al³⁰ and Boileau et al.⁴

In terms of both BV and BV/TV, Row 1 had the greatest value (BV, 87.3 ± 25.1 mm; BV/TV, 8.6% ± 2.5%; $P = .0001$ for both compared with the other 3 rows), followed by Row 4, 15 to 21 mm from the summit of the GT (BV, 62.0 ± 22.7 mm; BV/TV, 6.1% ± 2.2%; $P = .0001$ for both compared with the other 3 rows). Row 2, 0 to 7 mm from the GT, had the lowest BV and BV/TV percentage (BV, 47.4 ± 15.8 mm; BV/TV, 4.7% ± 1.6%; $P = .0001$ for both compared with the other 3 rows).

The trabecular pattern factor (Tb.Pf) is a 3D index that describes the reciprocal trabecular lattices and is a marker of trabecular connectivity.^{9,14,23} This was greatest in the superior-most lateral row, 0 to 7 mm from the GT (8.1 ± 1.8; $P = .0001$). This is the same area that had the lowest BV and BV/TV described above. Tb.Pf was lowest in the medial row and the inferior-most lateral row, where the bone volume parameters were greatest. Trabecular connectivity demonstrated an inverse relationship to BV/TV.

The SMI has been shown to strongly correlate with bone strength.²¹ It is a nonmetric parameter that describes the relative prevalence of rods and plates of trabecular bone in a 3D structure. The SMI was greatest at the inferior-most lateral row, 15 to 21 mm from the summit of the GT, (2.9 ± 0.9; $P = .0001$).

Row 1 had the greatest value for both Tb.N (0.3 ± 0.06 mm⁻¹; $P = .0001$) and Tb.Th (0.3 ± 0.08 μm; $P = .0001$) with the lowest degree of Tb.S (1.3 ± 0.4 μm; $P = .0001$), while Row 4, 15 to 21 mm from the summit of the GT, demonstrated the lowest Tb.N (0.2 ± 0.1 mm⁻¹) and Tb.Th (0.1 ± 0.05 μm) with the highest Tb.S (2.2 ± 1.1 μm).

Bone Histomorphometric Parameters: Torn Versus Intact Tendons

There were statistically significant differences in the histomorphometric parameters between specimens that had torn or intact rotator cuffs. These differences were evident for both BV and some trabecular properties but not SMI. The GTs of specimens with intact rotator cuff tendons had significantly greater BV (61.9 ± 24.1 mm [intact] vs 51.8 ± 21.7 mm [torn]; $P = .018$) as well as BV/TV (6.1% ± 2.4% [intact] vs 5.1% ± 2.1% [torn]; $P = .018$).

TABLE 3
Cortical Thickness of Volumes of Interest in the Lateral Rows^a

	Zone A, Posterior Third of the Greater Tuberosity, mm	Zone B, Middle Third of the Greater Tuberosity, mm	Zone C, Anterior Third of the Greater Tuberosity, mm	Mean Cortical Thickness, mm
Zone 2: lateral row 7 mm from GT	0.42 ± 0.14 (P = .047)	0.42 ± 0.15 (<i>P = .575</i>)	0.32 ± 0.06 (<i>P = .930</i>)	0.39 ± 0.14 (<i>P = .405</i>)
Zone 3: lateral row 14 mm from GT	0.32 ± 0.06 (P = .008)	0.32 ± 0.11 (<i>P = .051</i>)	0.34 ± 0.14 (P = .008)	0.33 ± 0.11 (P = .0001)
Zone 4: lateral row 21 mm from GT	0.70 ± 0.16	0.65 ± 0.19	1.02 ± 0.23	0.79 ± 0.24
Mean cortical thickness	0.48 ± 0.11	0.47 ± 0.08	0.56 ± 0.14	

^aData are reported as mean ± SD. Boldfaced *P* values indicate statistical significance. GT, greater tuberosity.

TABLE 4
Anteroposterior Comparison of Bone Morphometric Parameters^a

	Zone A, Posterior Third of the Greater Tuberosity, mm	Zone B, Middle Third of the Greater Tuberosity, mm	Zone C, Anterior Third of the Greater Tuberosity, mm	<i>P</i> Value
Volumes				
BV, mm ³	74.5 ± 27.4	55.8 ± 24.9	56.9 ± 20.7	.0001
BV/TV, %	7.3 ± 2.7	5.5 ± 2.4	5.6 ± 2.0	.0001
Trabecular properties				
Tb.Pf, mm ⁻¹	5.3 ± 2.5	6.6 ± 2.9	6.1 ± 2.3	.058
SMI	2.4 ± 0.6	2.5 ± 0.7	2.5 ± 0.6	.798
Tb.Th, μm	0.3 ± 0.1	0.3 ± 0.1	0.3 ± 0.1	.462
Tb.N, mm ⁻¹	0.3 ± 0.2	0.2 ± 0.2	0.2 ± 0.1	.364
Tb.Sp, μm	1.5 ± 0.6	1.7 ± 1.1	1.8 ± 1.0	.114

^aData are reported as mean ± SD. Boldfaced *P* values indicate statistical significance. BV, bone volume; SMI, structure model index; TV, total tissue volume; Tb.Pf, trabecular pattern factor; Tb.Sp, trabecular separation; Tb.Th, trabecular thickness.

TABLE 5
Superoinferior Comparison of Bone Morphometric Indices^a

	Row 1, Medial	Row 2, Superior Lateral (0-7 mm From GT)	Row 3, Intermediate Lateral (8-14 mm From GT)	Row 4, Inferior Lateral (15-21 mm From GT)	<i>P</i> Value
Volumes					
BV, mm ³	87.3 ± 25.1	47.4 ± 15.8	52.76 ± 17.9	62.0 ± 22.7	.0001
BV/TV, %	8.6 ± 2.5	4.7 ± 1.6	5.2 ± 1.8	6.1 ± 2.2	.0001
Trabecular properties					
Tb.Pf, mm ⁻¹	4.3 ± 1.9	8.1 ± 1.8	6.6 ± 2.2	5.0 ± 2.7	.0001
SMI	2.4 ± 0.3	2.4 ± 0.3	2.3 ± 0.5	2.9 ± 0.9	.0001
Tb.Th, μm	0.3 ± 0.06	0.2 ± 0.09	0.3 ± 0.3	0.1 ± 0.05	.0001
Tb.N, mm ⁻¹	0.3 ± 0.08	0.3 ± 0.2	0.2 ± 0.2	0.2 ± 0.1	.0001
Tb.Sp, μm	1.3 ± 0.4	1.6 ± 0.8	1.7 ± 1.0	2.2 ± 1.1	.0001

^aData are reported as mean ± SD. Bolded *P* values indicate statistical significance. BV, bone volume; GT, greater tuberosity; SMI, structure model index; TV, total tissue volume; Tb.Pf, trabecular pattern factor; Tb.Sp, trabecular separation; Tb.Th, trabecular thickness.

The trabecular pattern factor (7.6 ± 2.3 [intact] vs 6.1 ± 2.1 [torn]; *P* = .003) and trabecular number (0.31 ± 0.30 mm⁻¹ [intact] vs 0.17 ± 0.08 mm⁻¹ [torn]; *P* = .001) were also greater in lateral rows of the GTs with intact tendons. While the trabecular separation was significantly greater in the lateral rows of the GTs with torn tendons (2.1 ± 1.2 μm [torn] vs 1.4 ± 0.5 μm [intact]; *P* = .0001) (Table 6 and Figure 2).

DISCUSSION

Arthroscopic TOE double-row rotator cuff repair techniques have evolved over the last decade with varying configurations of suture anchor placement. Recommendations in the literature regarding the optimum sites for placement of suture anchors in rotator cuff repair are controversial.^{7,11,13,29,31} Furthermore, the type of anchor utilized depends on an understanding of the osseous morphology

TABLE 6
 Superiorinferior Comparison of Bone Morphometric Indices^a

	Intact Tendons, Rows 2 to 4 (n = 6)	Torn Tendons, Rows 2 to 4 (n = 7)	P Value
Volumes			
BV, mm ³	61.9 ± 24.1	51.8 ± 21.7	.018
BV/TV, %	6.1 ± 2.4	5.1 ± 2.1	.018
Trabecular properties			
Tb.Pf, mm ⁻¹	7.6 ± 2.3	6.1 ± 2.1	.003
SMI	2.5 ± 0.7	2.6 ± 0.7	.385
Tb.Th, μm	0.3 ± 0.14	0.3 ± 0.15	.290
Tb.N, mm ⁻¹	0.31 ± 0.30	0.17 ± 0.08	.001
Tb.Sp, μm	1.4 ± 0.5	2.1 ± 1.2	.0001

^aData are reported as mean ± SD. Boldfaced P values indicate statistical significance.

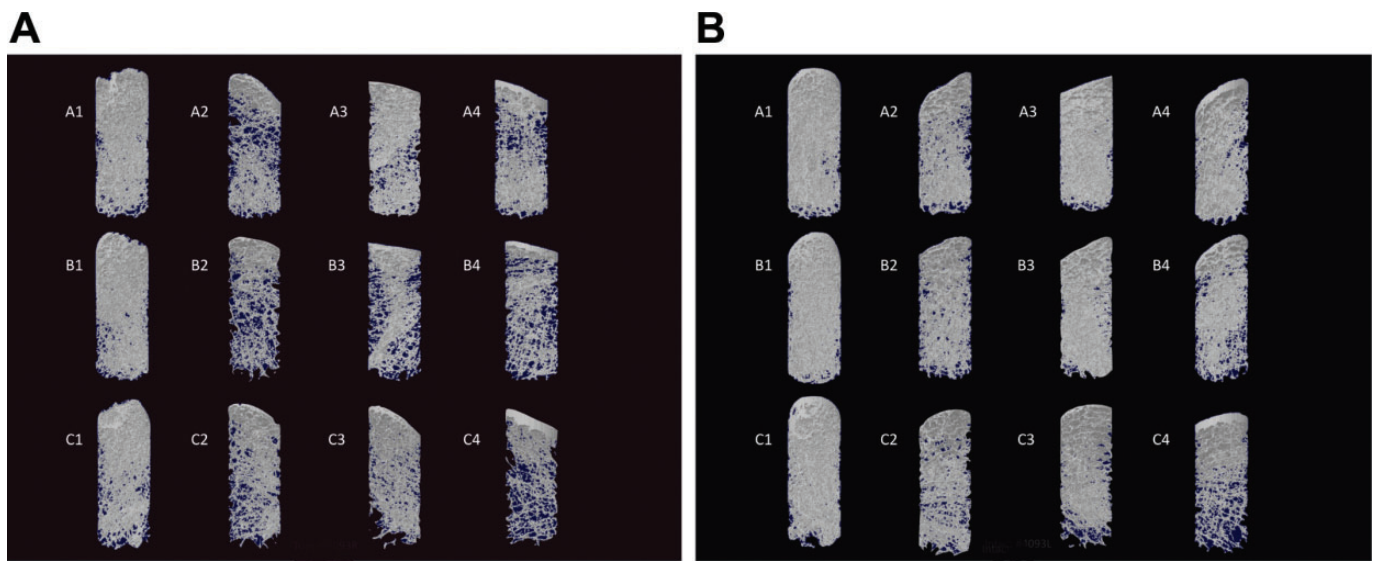


Figure 2. Macroscopic representative regions of greater tuberosity volume of interest in an individual who had a (A) torn rotator cuff on the right side and (B) intact tendons on the left side. On close inspection, it is evident that the bone quality in the lateral zones (A-C and 2-4) is different.

of the fixation area and, specifically, the predominance of cortical or spongy bone.

The mattress tension band technique developed by Boileau et al⁵ positions the anchor much more distal to the summit of the GT, where a higher pullout strength has been demonstrated. Rossouw et al²⁹ found that suture anchors placed more than 20 mm distal of the tip of the GT had greater pullout strengths. The authors speculated that a greater cortical thickness might be the reason for this increase in pullout strength and therefore recommended insertion of anchors as far distal from the tip of the GT as possible. Other authors have also recommended placing suture anchors distal to the GT because the bone stock was thought to be better in this region.^{11,31}

This micro-CT study is the first to demonstrate that the inferior-most lateral row, 21 mm from the summit, not only has good bone stock, demonstrated by the high levels of BV and BV/TV percentage, but also the thickest cortical bone. We also found this region to have the greatest SMI. SMI is a

nonmetric parameter that describes the relative prevalence of rods and plates of trabecular bone in a 3D structure, with strong correlation with bone strength.²¹ In terms of BV/TV, the juxta-articular medial row had the best bone stock, followed by the inferior-most lateral row 15 to 21 mm from the summit of the GT. Previous studies have similar findings with regard to the juxta-articular medial row and they recommend placement of medial row anchors adjacent to the articular surface to guarantee a better structural bone stock.^{17,20}

We found no significant difference in the trabecular properties between the posterior, intermediate, and anterior zones of the GT, but both BV and BV/TV were significantly greater in the posterior third of the GT than in the intermediate or anterior thirds. Barber et al reported decreased pullout strength of suture anchors in the anterior compared with posterior portion of the GT.¹ Although they found greater pullout forces in the posterior part of the GT, they failed to show any trabecular differences between the

anterior and posterior areas of the GT. Our findings are also consistent with Kirchoff et al,¹⁷ who analyzed the mean BV/TV of the GTs of the osteoporotic humeral head using high-resolution peripheral quantitative computed tomography (HR-pQCT). These authors also found significant regional differences, with the best bone stock in the posterior parts of the GT.

The trabecular pattern factor (Tb.Pf) is a 3D index that describes the reciprocal trabecular lattices and is a marker of trabecular connectivity.^{9,14,23} To our knowledge, this parameter has never been studied in the GT before. We found that trabecular connectivity had an inverse relationship to bone stock (BV and BV/TV). Tb.Pf was greatest in the superior-most lateral row, 7 mm from the GT, followed by the intermediate lateral row, 14 mm below the summit of the GT. These 2 areas had the lowest BV and BV/TV percentage in our study, consistent with other micro-CT studies in the literature.^{17,20} Cortical thickness was also lowest in these zones. The loss of connectivity has a substantial impact on structural integrity and results in elevated fracture risk.

In a further study, Kirchoff et al¹⁸ showed better micro-CT parameters of bone quality in the superficial portion of the analyzed bone cylinders from the GT of cadaveric specimens with intact rotator cuffs in comparison with the deep portion. They demonstrated that cancellous bone presents with increasingly worse bone quality in terms of low BV/TV, reduced trabecular number as well as trabecular thickness, and increased trabecular separation when analyzing subsequently deeper portions of the bone cylinders of the GT starting from the outer cortical surface. They concluded that screwing of the anchors to a deeper cancellous region would not result in increased stability.

There were no differences regarding sex or side between the torn and intact groups. We found statistically significant differences in some histomorphometric parameters between the GTs of proximal humeri that had torn or intact rotator cuffs. A micro-CT study by Meyer et al²⁰ found that tendon tears are associated with a reduction in cancellous bone density of greater than 50%, leading to a virtually hollow GT with intact cortical bone. They found that the cortical bone quality was far more consistent and not grossly altered by full-thickness tendon tears.²⁰ We also found that there were statistically significant differences in the bone volume parameters as well as the trabecular number (Tb.N), trabecular separation (Tb.S), and trabecular pattern factor. Interestingly, there was no difference in SMI.

This investigation has several limitations. The advanced age of the cadaveric specimens may limit the applicability of our findings to the 50- to 60-year-old patient groups that commonly present with rotator cuff tears. The presence of chronically retracted tears would have an impact on GT bone quality, as demonstrated by this study and Meyer et al.²⁰ We did not carry out biomechanical testing of the lateral rows to further support our histomorphometric findings. Rossouw et al²⁹ found that suture anchors placed more than 20 mm distal to the tip of the GT had greater pullout strength, but we limited our histomorphometric analysis to 21 mm below the GT because of the potential risk to the axillary nerve below this level.

CONCLUSION

The inferior-most lateral row, 15 to 21 mm from the tip of the GT, has good bone stock, the highest cortical thickness, and the best SMI for lateral row anchor placement. The anterior-most part of the GT, 15 to 21 mm below its summit, had the greatest cortical thickness of all zones. The posterior third of the GT also has good bone stock parameters, second only to the medial row.

The best site for lateral row cortical anchor placement in posterior-superior transosseous equivalent rotator cuff repair is 15 to 21 mm below the summit of the GT.

REFERENCES

1. Barber FA, Feder SM, Burkhart SS, Ahrens J. The relationship of suture anchor failure and bone density to proximal humerus location: a cadaveric study. *Arthroscopy*. 1997;13:340-345.
2. Barber FA, Herbert MA. Suture anchors—update 1999. *Arthroscopy*. 1999;15:719-725.
3. Barber FA, Herbert MA, Beavis RC, Barrera Oro F. Suture anchor materials, eyelets, and designs: update 2008. *Arthroscopy*. 2008;24:859-867.
4. Boileau P, Brassart N, Watkinson DJ, Carles M, Hatzidakis AM, Krishnan SG. Arthroscopic repair of full-thickness tears of the supraspinatus: does the tendon really heal? *J Bone Joint Surg Am*. 2005;87:1229-1240.
5. Boileau P, Brassart N, Youssanne Y, Scobeece R. The mattress-tension-band technique: a knotless double-row arthroscopic rotator cuff repair. *Tech Shoulder Elbow Surg*. 2009;10:22-25.
6. Burkhart SS. The deadman theory of suture anchors: observations along a south Texas fence line. *Arthroscopy*. 1995;11:119-123.
7. Burkhart SS, Diaz Pagan JL, Wirth MA, Athanasiou KA. Cyclic loading of anchor-based rotator cuff repairs: confirmation of the tension overload phenomenon and comparison of suture anchor fixation with transosseous fixation. *Arthroscopy*. 1997;13:720-724.
8. Craft DV, Moseley JB, Cawley PW, Noble PC. Fixation strength of rotator cuff repairs with suture anchors and the transosseous suture technique. *J Shoulder Elbow Surg*. 1996;5:32-40.
9. Davison KS, Siminoski K, Adachi JD, et al. Bone strength: the whole is greater than the sum of its parts. *Semin Arthritis Rheum*. 2006;36:22-31.
10. Djurasovic M, Marra G, Arroyo JS, Pollock RG, Flatow EL, Bigliani LU. Revision rotator cuff repair: factors influencing results. *J Bone Joint Surg Am*. 2001;83:1849-1855.
11. Gartsman GM. All arthroscopic rotator cuff repairs. *Orthop Clin North Am*. 2001;32:501-510.
12. Gerber C, Schneeberger AG, Beck M, Schlegel U. Mechanical strength of repairs of the rotator cuff. *J Bone Joint Surg Br*. 1994;76:371-380.
13. Goradia VK, Mullen DJ, Boucher HR, Parks BG, O'Donnell JB. Cyclic loading of rotator cuff repairs: a comparison of bioabsorbable tacks with metal suture anchors and transosseous sutures. *Arthroscopy*. 2001;17:360-364.
14. Guo XE, Kim CH. Mechanical consequence of trabecular bone loss and its treatment: a three-dimensional model simulation. *Bone*. 2002;30:404-411.
15. Hecker AT, Shea M, Hayhurst JO, Myers ER, Meeks LW, Hayes WC. Pull-out strength of suture anchors for rotator cuff and Bankart lesion repairs. *Am J Sports Med*. 1993;21:874-879.
16. Hildebrand T, Rueggsegger P. Quantification of bone microarchitecture with the Structure Model Index. *Comput Methods Biomech Biomed Eng*. 1997;1:15-23.
17. Kirchoff C, Braunstein V, Milz S, et al. Assessment of bone quality within the tuberosities of the osteoporotic humeral head: relevance for

- anchor positioning in rotator cuff repair. *Am J Sports Med.* 2010;38:564-569.
18. Kirchoff C, Kirchoff S, Sprecher CM, et al. X-treme CT analysis of cancellous bone at the rotator cuff insertion in human individuals with osteoporosis: superficial versus deep quality. *Arch Orthop Trauma Surg.* 2013;133:381-387.
 19. Meier SW, Meier JD. Rotator cuff repair: the effect of double-row fixation on three-dimensional repair site. *J Shoulder Elbow Surg.* 2006;15:691-696.
 20. Meyer DC, Fucentese SF, Koller B, Gerber C. Association of osteopenia of the humeral head with full-thickness rotator cuff tears. *J Shoulder Elbow Surg.* 2004;13:333-337.
 21. Mitra E, Rubin C, Qin YX. Interrelationship of trabecular mechanical and microstructural properties in sheep trabecular bone. *J Biomech.* 2005;38:1229-1237.
 22. Muller R, Van Campenhout H, Van Damme B, et al. Morphometric analysis of human bone biopsies: a quantitative structural comparison of histological sections and micro-computed tomography. *Bone.* 1998;23:59-66.
 23. Odgaard A, Gundersen HJ. Quantification of connectivity in cancellous bone, with special emphasis on 3-D reconstructions. *Bone.* 1993;14:173-182.
 24. Perilli E, Baruffaldi F, Visentin M, et al. MicroCT examination of human bone specimens: effects of polymethylmethacrylate embedding on structural parameters. *J Microsc.* 2007;225:192-200.
 25. Perilli E, Briggs AM, Kantor S, et al. Failure strength of human vertebrae: prediction using bone mineral density measured by DXA and bone volume by micro-CT. *Bone.* 2012;50:1416-1425.
 26. Perilli E, Parkinson IH, Reynolds KJ. Micro-CT examination of human bone: from biopsies towards the entire organ. *Ann Ist Super Sanita.* 2012;48:75-82.
 27. Pietschmann MF, Fröhlich V, Ficklscherer A, et al. Suture anchor fixation strength in osteopenic versus non-osteopenic bone for rotator cuff repair. *Arch Orthop Trauma Surg.* 2009;129:373-379.
 28. Reed SC, Glossop N, Ogilvie-Harris DJ. Full-thickness rotator cuff tears. A biomechanical comparison of suture versus bone anchor techniques. *Am J Sports Med.* 1996;24:46-48.
 29. Rossouw DJ, McElroy BJ, Amis AA, Emery RJ. A biomechanical evaluation of suture anchors in repair of the rotator cuff. *J Bone Joint Surg Br.* 1997;79:458-461.
 30. Thomazeau H, Boukobza E, Morcet N, Chaperon J, Langlais F. Prediction of rotator cuff repair results by magnetic resonance imaging. *Clin Orthop Relat Res.* 1997;344:275-283.
 31. Ticker JB, Warner JJ. Single-tendon tears of the rotator cuff. Evaluation and treatment of subscapularis tears and principles of treatment for supraspinatus tears. *Orthop Clin North Am.* 1997;28:99-116.
 32. Tingart MJ, Apreleva M, Lehtinen J, Zurakowski D, Warner JJ. Anchor design and bone mineral density affect the pull-out strength of suture anchors in rotator cuff repair: which anchors are best to use in patients with low bone quality? *Am J Sports Med.* 2004;32:1466-1473.
 33. Zumstein MA, Jost B, Hempel J, Hodler J, Gerber C. The clinical and structural long-term results of open repair of massive tears of the rotator cuff. *J Bone Joint Surg Am.* 2008;90:2423-2431.